

Laser-Induced Choroidal Neovascularization : A Case Report

S.Ayyadi, C.Sadouni, M.Issiaka, A.Mchachi, L.Benhmidoune, A.Chakib,
R.Rachid, M.ElBelhdji

Department of Adult Ophtalmology , Hospital of 20 Aout 1953, Ibn Rochd University Hospital
Faculty of Medecine and Pharmacy of Casablanca- Hassan II University

Summary : We report the case of a nine-year-old boy presented to our consultation with blurred vision in his right eye for 5 months. The symptom immediately happened after child's game when the boy staring at the laser beam for a few seconds . Examination of ocular fundus with slit lamp showed yellowish lesion in macula in his right eye. CNV was confirmed by fundus examinations and intravitreal ranibizumab injection was performed.

Keywords: choroidal neovascularization, laser

Date of Submission: 24-06-2021

Date of Acceptance: 07-07-2021

I. Introduction :

Laser instruments have been used in several contexts, such as the lecture halls, but also inappropriately as toys for children and induced maculopathy such as choroidal neovascularization (CNV). Patients with laser induced CNV typically present with blurred vision, central scotomas, and metamorphopsia.

The treatment of CNV secondary to laser injury is still debated. In literature, few cases of CNV secondary to laser injury have been treated by intravitreal bevacizumab

II. Case Report:

A 9-year-old Moroccan boy presented to our consultation with blurred vision in the right eye (OD) for 5months accompanied by a central scotoma, which appeared after having stared at the beam of a laser pointer.

The laser pointer is "a class III laser product, wavelength: 650 nm, the maximum output power: less than 100mW" according to the sticker on it.

On examination, his best corrected visual acuity (BCVA) was 1/10 OD and 10/10 in the left eye (OS). The intraocular pressures and the anterior segments were normal in both eyes. Funduscopic examination demonstrated a yellowish-white lesion in the macula OD (Figure 1)

Spectral domain optical coherence tomography (OCT) illustrated disruption of external limiting membrane, ellipsoid zone, interdigitation zone and retinal pigment epithelium, an elevated dome-shaped lesion with an extension to the subretinal space (Figure 2).

Fluorescein angiography was performed in order to confirm the presence of a subretinal neovascular lesion, well-delineated with hyperfluorescence (Figure 3).

Spectral domain optical coherence tomography angiography (OCTA) revealed the the neovascular membrane existing in the level of deep and outer retina. Flow deficit in the level of choriocapillaris was found to correspond to the choroidal neovascularization (Figure 4).

A diagnosis of laser induced CNV was made and one intravitreal injection of 0.5 mg/0.05 mL ranibizumab was performed without any amelioration because of inactivated CNV.

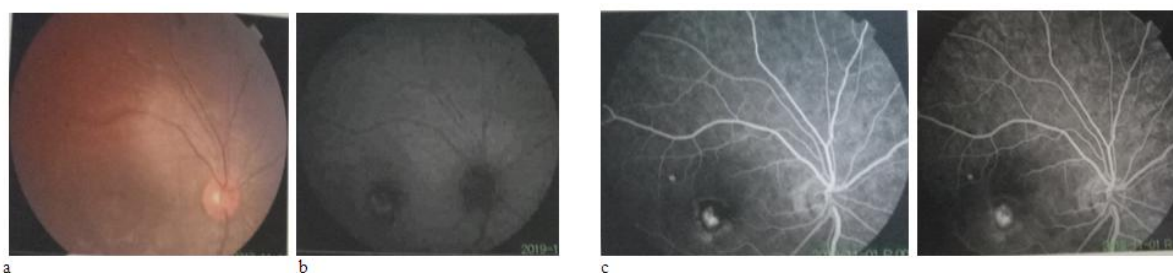


Figure1: a. Funduscopic examination demonstrated a yellowish-white lesion in the macula OD - b. hyperautofluorescence lesion in the macula - c. subretinal neovascular lesion, well-delineated with hyperfluorescence

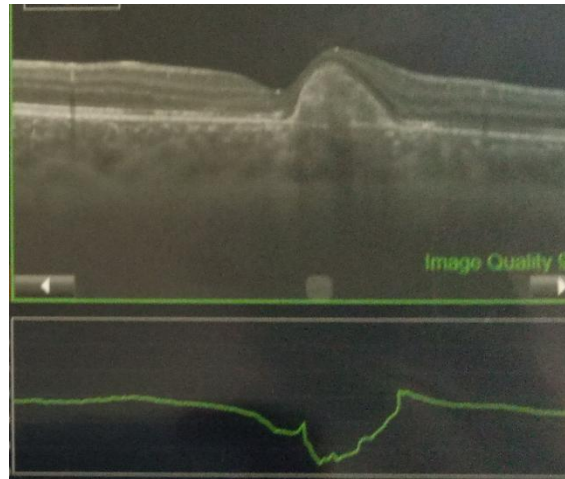


Figure 2: disruption of external limiting membrane, ellipsoid zone, interdigitation zone and retinal pigment epithelium, an elevated dome-shaped lesion with an extension to the subretinal space

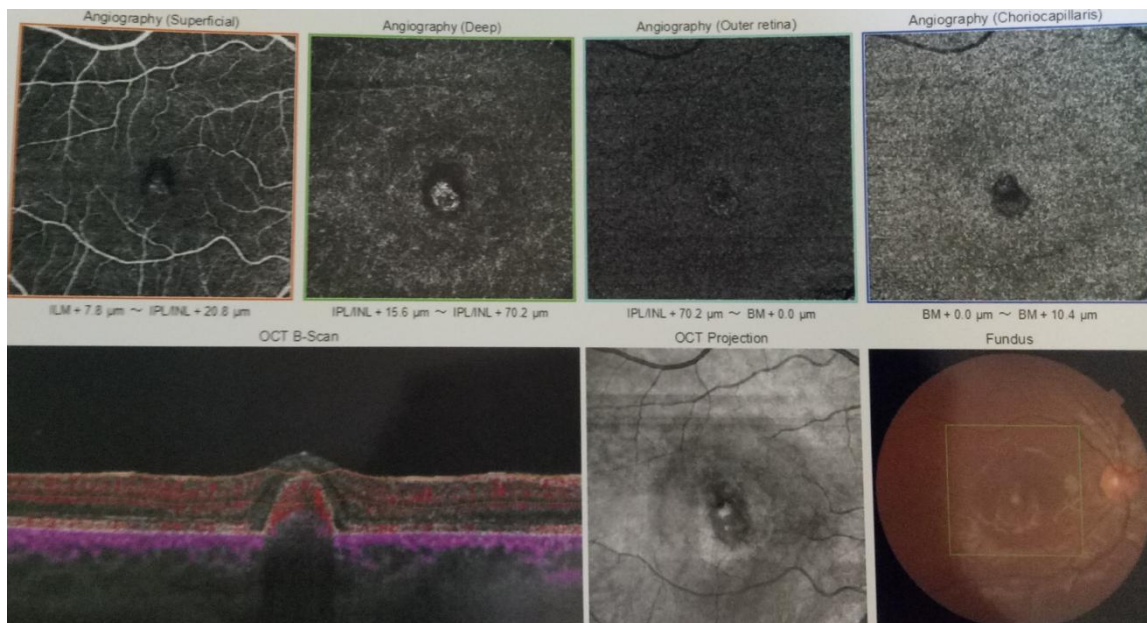


Figure 3: Spectral domain optical coherence tomography angiography revealed the neovascular membrane existing in the level of deep and outer retina and was superonasal to the fovea. Flow deficit in the level of choriocapillaris was found to correspond to the choroidal neovascularization.

III. Discussion :

The incidence of laser induced eye injuries has been on a rise because the wide use of laser in many activities. The safety level of laser products is categorized according to the American National Standard Institute and Food and Drug Administration as a class III. The morphology of retinal damage from the laser pointers may vary. Fundus findings described in the literature include subretinal hemorrhage [1], retinal edema, scars in the pigment epithelium [2], foveal granularity [3], vitreous or chorioretinal hemorrhage [4], perifoveal drusenoid like deposits/pigment clumps [5, 6], or ring-shaped hypopigmented lesions in fovea [7, 8] and rarely choroidal neovascularization [9].

After diagnosis of laser induced Choroidal neovascularization (CNV), intravitreal ranibizumab was performed [10]. The evolution was marked by the non-improvement of the visual acuity and the non-regression of the CNV because it was inactivated (occult). However, We reviewed the published articles which reported laser induced CNV with treatment of intravitreal anti-VEGF injections. Li and al. reported 7-year-old boy whose BCVA improved to 30/50 and rapid regression of CNV after only 1 anti-VEGF injection [11]. Francesca Amoroso and al. reported A 14-year-old boy whose showed an increase in BCVA, from 20/40 to 15/20 in the month following the intravitreal injection [12].

Laser pointers are readily available and appropriate use of laser pointers in the pediatric population must be emphasized due to the potential irreversible retinal injury.

Health professionals, school teachers, and parents should raise public awareness of this emerging public health issue by educating children about the dangers of laser pointers. Laser pointer devices among children should be discouraged and limited due to the possibility of permanent harm to themselves and others..[13]

IV. Conclusion

Handheld lasers can produce permanent retinal damage with visual sequelae if improperly used. Legislation and laws may be required to better control the sale and use of these devices

References:

- [1]. Boosten K, Van Ginderdeuren R, Spileers W, Stalmans I, Wirix M, Van Calster J, Stalmans P (2011) Laser-induced retinal injury following a recreational laser show: two case reports and a clinicopathological study. *Bull Soc Belge Ophthalmol* 317:11–16
- [2]. Wyrsch S, Baenninger PB, Schmid MK (2010) Retinal injuries from a handheld laser pointer. *N Engl J Med* 363: 1089–1091
- [3]. Ziahosseini K, Doris JP, Turner GS (2010) Laser eye injuries. Maculopathy from handheld green diode laser pointer. *Br Med J* 340:c2982
- [4]. Mainster MA, Stuck BE, Brown J Jr (2004) Assessment of alleged retinal laser injuries. *Arch Ophthalmol* 122:1210–1217
- [5]. Sell CH, Bryan JS (1999) Maculopathy from handheld diode laser pointer. *Arch Ophthalmol* 117:1557–1558
- [6]. Sethi CS, Grey RH, Hart CD (1999) Laser pointers revisited: a survey of 14 patients attending casualty at the Bristol Eye Hospital. *Br J Ophthalmol* 83:1164–1167
- [7]. Ueda T, Kurihara I, Koide R (2011) A case of retinal light damage by green laser pointer (Class IIIB). *Jpn J Ophthalmol* 55:428–430
- [8]. Zamir E, Kaiserman I, Chowers I (1999) Laser pointer maculopathy. *Am J Ophthalmol* 127:728–729
- [9]. Fujinami K, Yokoi T, Hiraoka M, Nishina S, Azuma N (2010) Choroidal neovascularization in a child following laser pointer-induced macular injury. *Jpn J Ophthalmol* 54:631–633
- [10]. Laser Institute of America. American National Standard for Safe Use of Lasers Z136.1. Orlando, FL: Laser Institute of America; 2014.
- [11]. Caixin Li, MD , Jianqing Li, MD, Xinzhu Chen, MD, Peirong Lu, MD, PhD. Laser-induced choroidal neovascularization A case report and some reflection on animal models for age-related macular degeneration. *Medicine* 2021;100:23
- [12]. Francesca Amoroso Eric H. Souied Meryem Filali Ansary Polina Astroz Alexandra Mouallem-Bézière Alexandre Pedinielli Alexandra Miere. Optical coherence tomography angiography findings of choroidal neovascularization secondary to laser injury: A case report. *American Journal of Ophthalmology Case Reports* Volume 19, September 2020, 100767
- [13]. K. Xu, E.K. Chin, P.A. Quiram, et al. Retinal injury secondary to laser pointers in pediatric patients. *Pediatrics*, 138 (4) (2016), Article e20161188

S.Ayyadi, et. al “ Laser-Induced Choroidal Neovascularization : A Case Report.” *IOSR Journal of Dental and Medical Sciences (IOSR-JDMS)*, 20(07), 2021, pp. 17-19.