

A Rare Case of Submeatal Leiomyomatous Polyp

1. Dr. Vijay Kumar C.R.

Professor, Dept. of Obstetrics and Gynecology, Dr. B.R. Ambedkar Medical College, Bengaluru, Karnataka.

2. Dr. Nutan Saha

Post-graduate trainee, Dept. of Obstetrics and Gynecology, Dr. B.R. Ambedkar Medical College, Bengaluru, Karnataka.

Abstract

Vaginal fibroids are rare condition with approximately 300 cases reported in world literature, exist as primary vaginal tumor and usually arise from anterior vaginal wall. This condition may present with various symptoms and may also be mistaken for carcinoma, sarcoma, vaginal cyst, cystocele, uterine prolapse, and adenomyoma of the vagina because of the variety in its size, appearance and locations. Here we are reporting a rare case of submeatal leiomyomatous polyp which was preoperatively diagnosed as vaginal prolapse.

KEYWORDS

Vaginal tumor, Vaginal fibroid, Leiomyoma, Dyspareunia, Urinary Retention, Excision, Enuclation.

Date of Submission: 02-07-2021

Date of Acceptance: 16-07-2021

I. Introduction

Fibroids are the most common benign tumors of uterus and to some extent, in the cervix, followed occurrences in the round ligament, the uterosacral ligament, ovaries, inguinal canal, urethra and fallopian tube. Young et al. observed two cases of vaginal tumors which are rare and include papilloma, mucus polyp, hemangioma, and rarely leiomyoma[1].

Vaginal leiomyomas remain a scarce entity with only ~300 reported cases since the first recognized case back in 1733 by Denys de Leyden[1]. Among 50,000 surgical specimens, Bennett and Erlich found only 9 cases and only 1 case in 15,000 autopsies[2].

These hormone-dependent tumors arise most commonly from the anterior vaginal wall causing varied clinical presentations and may or may not be associated with leiomyomas elsewhere in the body.

Here we are presenting a rare case of submeatal leiomyomatous polyp presenting with preoperative diagnosis as vaginal prolapse.

II. Case Report

A 30-year-old female Para-2 Living-1 non-tubectomised presented with C/o Mass perVagina since 2years, initially small but gradually increasing in size, pains locally on touch for 3-4 months, not associated with lower abdominal pain, C/o Dyspareunia for 6-7 months, Urinary Retention 3-4 months associated with increased urinary frequency, Leucorrhoea intermittently. No H/o Reduction of mass on lying down/Dysuria/Bleeding locally on touch/lower abdominal pain/bowel disturbance/post-coital or intermenstrual bleeding. Cycles were of 28±2 days with 4-5 days duration with normal flow, not associated with clots/dysmenorrhea. LCB- 1½years ago and not on any contraception. No H/o comorbidities/significant Family H/o malignancy/fibroids.

On examination, patient moderately built/well-nourished, no pallor/pedal-edema/lymphedema, vitals stable. On PerAbdomen examination, abdomen soft/non-tender/no organomegaly. On PerSpeculum examination, Cervix healthy, vaginal wall fullness noted with mass arising anteriorly. No abnormal discharge noted. Bimanual examination revealed a huge mass over anterior vaginal wall of ~5*5cm, cystic to firm in consistency. Cervix felt separately. Uterus anteverted/non-palpable/freely mobile. Bilateral and posterior fornices free.

On clinical evaluation, diagnosis of soft tissue tumor of vaginal wall was made however the urethral diverticulitis was kept in mind.

Diagnostic cystoscopy done initially to rule out the diverticulitis. By vaginal route, polypectomy done under Spinal. Priorly Foley's catheterization done to delineate well the urethra during dissection and to avoid the incidental urethral injury. Sample was then sent for HPE with post-operative diagnosis of submeatal leiomyoma. Postoperatively, clear urine drained in catheter.

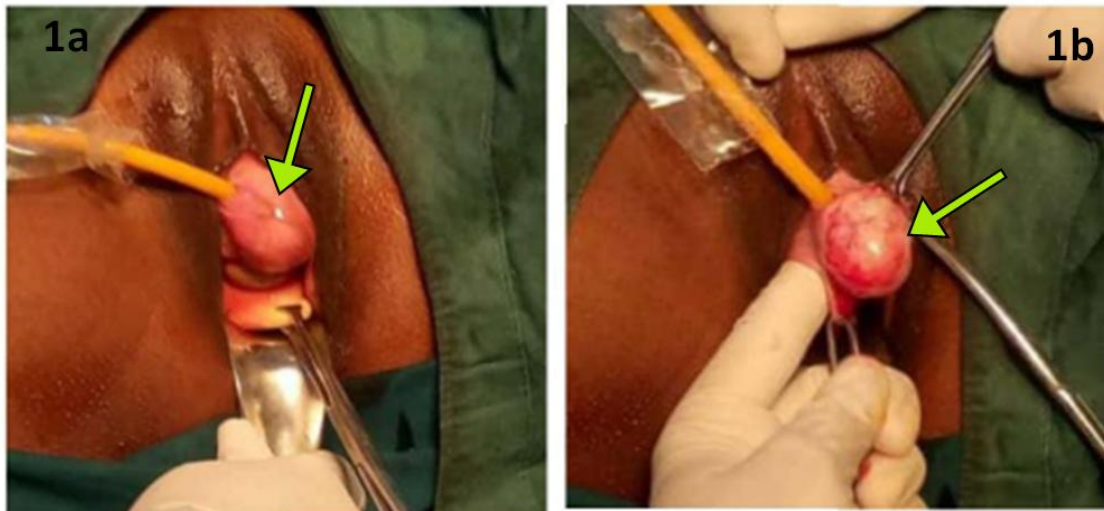


Fig. 1a&1b : Submeatal Leiomyomatous Polyp, 1a: emerging distinctly from the Anterior Vaginal Wall from below the Urethral Surface, 1b: Enucleating the mass from its bed.

Gross pathological examination reported a specimen consists of single grey-white nodular bit of tissue, measuring 3*3*2.5cm. The cut-surface showed grey-white glistening solid areas. Microscopic examination reported a well circumscribed tumor, having a capsule and the stroma showed extensive areas of myxoid degeneration. Few viable areas were seen, with spindle cells in fascicles. No atypical cells or mitotic activity or necrosis noted. Impression outlined as Leiomyomatous polyp with degenerative changes.

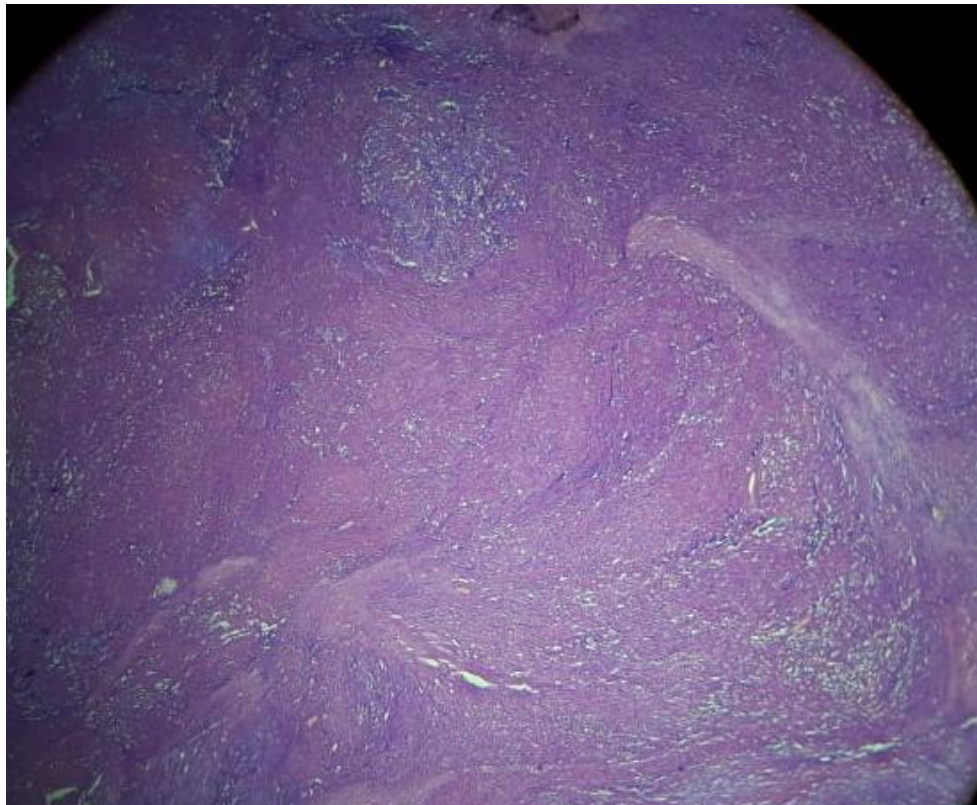


Fig. 2: Lower Power View (10x magnification) showing extensive areas of myxoid degeneration with areas showing spindle cells in fascicles.

III. Discussion

Extra-uterine fibroids are benign tumors which are rare and may cause issue in creating diagnosis. Vaginal leiomyoma is a rare tumor of vagina reported in precisely 300 cases to date within the literature[3]. Commonest age group 35–50years, additional common among Caucasian women[2].

Histology of Vagina-1.Vaginal mucosa-Nonkeratinized, stratified squamous epithelium. 2.Vaginal submucosa - Beneath the basement membrane. Composed of connective tissue with elastic fibers and numerous lymphatics and venous plexus. 3.Muscularis layer-Composed of a circular layer of muscle overlaid by a longitudinal layer. The solid tumors originating from the vaginal tissue incorporates papilloma, hemangioma, mucous polyp, and rarely leiomyoma[3].

Although rare, the most common type of mesenchymal neoplasm of the vagina is the leiomyoma which varies from 0.5~15cm in diameter[3] and is usually situated as a single, well-circumscribed mass within the midline anterior vaginal wall [1]. Few studies mentioned the placement of fibroid in the lateral wall and rarely in posterior wall. It may hinder birth-canal if accompanies pregnancy.

It may or may not be related to leiomyomas elsewhere in the body[2]. Vaginal leiomyomas are estrogen-dependent tumors[3]. It arises from vaginal smooth muscle (intramural) or local arterial musculature or smooth muscle of the bladder or urethra, can be pedunculated and solid in addition as cystic[2]. Usually, they are single, small, benign, and slow-growing. Sarcomatous change has, however, been reported[4].

Differential Diagnosis- Anterior vaginal mass-cystocele, urethrocele, urethral diverticulum, inclusion cysts, cervical myoma, and prolapse of uterus. Posterior vaginal tumors-Rectocele, enterocele, inclusion cysts, and tumors of the rectum or rectovaginal septum

Lateral forniceal mass-Gartner's duct cysts, inclusion cysts, para-urethral and Bartholin cysts or abscesses, endometriosis, and malignant tumors of the vagina[3].

Usually asymptomatic but may present with complaints if the size crosses >6cm. Clinical presentations may vary depending on the size and location, commonest being some mass protruding out of vagina alongside abdominal pain, dyspareunia, vaginal discharge, dysmenorrhea,dysfunctional uterine bleeding, menometrorrhagia, retention urine, urinary frequency, dysuria, recurrent UTI, incomplete-voiding, infertility, gluteal swelling, pain in right iliac fossa[2].

One study reported a vaginal fibroid case diagnosed post-operatively presented as ovarian tumor priorly.

Preoperatively, ultrasonographic diagnosis could be tough however, MRI sometimes clinches the diagnosis. Pelvic MRI is recommended if imaging is inconclusive/non-diagnostic throughout TVS. MRI is additional reliable diagnostic tool in evaluating normal vaginal anatomy and vaginal disease due to its soft-tissue characterization and depiction of anatomical detail. Vaginal anatomy is found to be best illustrated by T2-weighted sequences. A vaginal leiomyoma usually appears as a homogenous round lesion with identical signal to that of the myometrium, with multiple calcifications. Lack of calcifications is a congruous finding in leiomyosarcomas. Poor vaginal tissue characterization excludes computerized tomography (CT) as the modality of choice in evaluating the female pelvis[4].

However, for diagnosis, histopathological confirmation is gold standard showing a composition of spindle-shaped cells with elongated and oval nuclei and little or no mitotic activity. Increased mitotic activity without aggressive behavior could be features of vaginal leiomyoma with pregnancy. Sarcomatous transformation can occur and a histopathologic study confirms the proper diagnosis. So, atypism, hypercellularity, and mitotic figures ought to be evaluated to rule out malignancy[2].

Total surgical vaginal excision/enucleation of the mass with disease-free margins, ideally with urethral catheterization to guard the urethra throughout surgery, is the treatment of choice.

Most effective approach-abdominal or vaginal route, depending on location of the tumor. Vaginal approach could cause severe hemorrhage if the base of tumor is not approachable or if the growth is present in upper part of vaginal fornices. In such cases, it is better to choose abdominal approach. At times an abdominoperineal approach is required to perform complete surgery[3].

Recurrence is rare however reported thus should be followed up for any risk of recurrence. Our patient was symptom-free after 2-months of follow-up.

One study surveyed through 11 vaginal leiomyomas-average times to show symptoms was 8.4years with incidence for malignant change was 9.1%.

The uniqueness of our case was that the diagnostic dilemma because of its distinct submeatal location. Also, intraoperatively it posed difficulties in resecting the leiomyoma as it is closely incorporated with urethra and bladder wall respectively.

IV. Conclusion

Although vaginal tumors are rare, thorough supervision should be given in recognizing the myoma at a premature stage it has capacity to transform into malignancy. Complete enucleation is recommended to prevent

recurrence and malignant transformation. Vaginal fibroids may present with various symptoms; hence, MRI may be necessary along with medical history.

References

- [1]. Patil RR, Vijay NR, Joshi S. An unusual presentation of vaginal leiomyoma. *Journal of Mid-life Health*. 2019 Oct;10(4):204.
- [2]. Gupta M, Saini V, Jindal R. Vaginal Leiomyoma: Case Report and Literature Review. *Journal of South Asian Federation of Menopause Societies*. 2017 Jan;5(1):62-5.
- [3]. HARINI H. VAGINAL LEIOMYOMA-A RARE CASE REPORT [Internet]. *Ejournal-tnmgrmu.ac.in*. 2017 [cited 11 July 2020]. Available from: <http://ejournal-tnmgrmu.ac.in/index.php/surgery/article/view/3347>
- [4]. Wethmar EI, D Mouton A, Dreyer G. Vaginal leiomyoma presenting as a lateral vaginal wall mass. *Southern African Journal of Gynaecological Oncology*. 2017 Jan 2;9(1):16-8.

Dr. Vijay Kumar C.R. "A Rare Case of Submeatal Leiomyomatous Polyp." *IOSR Journal of Dental and Medical Sciences (IOSR-JDMS)*, 20(07), 2021, pp. 36-39.