

# Hydatid Cyst of Liver: A Case Report and Review of Literature

Dr.R. Jayakumar M. S.<sup>1</sup>, Dr. S.Viveganandan<sup>2</sup>, Dr. Kalaranjani. V<sup>3</sup>  
(Associate professor<sup>1</sup>, Post Graduate<sup>2</sup>, Post Graduate<sup>3</sup>, Department of General Surgery, Coimbatore medical college Hospital, Coimbatore, Tamilnadu, India)

---

## Abstract

Human hydatid disease or cystic echinococcosis (CE) is parasitic disease of world-wide distribution and is endemic in sheep rearing areas including the Indian subcontinent. It is caused by the parasite, *Echinococcus granulosus* a cestode that lives in the small intestine of dogs and other canines. The most common site of occurrence of hydatid cysts in humans is the liver followed by the lungs. They are asymptomatic in most cases and discovered accidentally on a routine abdominal ultrasound or an ultrasound performed for diagnosing other pathologies. The hepatic hydatid cyst therapy is multimodal, including medical, surgical, and, lately, minimally invasive techniques. We report a case of calcified hepatic hydatid cyst which was managed surgically.

**Keywords:** Zoonoses, Hydatid cyst, *Echinococcus granulosus*, hepatic cyst.

---

Date of Submission: 10-08-2021

Date of Acceptance: 25-08-2021

---

## I. Introduction

Human hydatid disease or cystic echinococcosis (CE) is parasitic disease of world-wide distribution and is endemic in sheep rearing areas including the Indian subcontinent. It is caused by the parasite, *Echinococcus granulosus* a cestode that lives in the small intestine of dogs and other canines. It is a serious disease, potentially lethal, which can be found anywhere in the world, but especially in endemic areas such as the Mediterranean Basin, Australia, New Zealand, North Africa, Eastern Europe, the Balkans, Middle East and South America. The life cycle of *Echinococcus* is indirect and involves two hosts, one definitive carnivore host (dogs) and the other intermediate herbivore host (sheep, Cattles, Humans). The problem arises when humans act as an accidental intermediate host and ingest viable oncosphere-containing eggs, which have been shed in the faeces of the definitive host. The oncospheres invade the intestines, enter the vasculature and develop into hydatid cysts in any organ or tissue, where a variety of symptoms can be produced. However, the liver acts as the first filter for hydatid larvae, making it the most commonly affected organ followed by lung. The hydatid cyst is mainly found in the liver (75% of the cases), being asymptomatic in most cases and discovered accidentally on a routine abdominal ultrasound or an ultrasound performed for diagnosing other pathologies. The hepatic hydatid cyst therapy is multimodal, including medical, surgical, and, lately, minimally invasive techniques. Our patient 65 years old female presented with abdominal pain, dyspepsia. Imaging studies revealed a well-defined calcified lesion with folded membranes in segment 3 & 4, compressing the left branch of portal vein. Patient underwent open surgery – pericystectomy. The likelihood of calcified cyst compressing left portal vein, operative management is almost always necessary.

## II. Case Report

A 65 years old female presented with chief complaints of abdominal pain & dyspepsia for 1 month duration. On examination patient general condition was fair with stable vitals. Abdomen was soft, not distended. A vague mass felt in right hypochondrium, non-tender, firm in consistency. No organomegaly, bowel sounds present. Baseline investigations were within normal limits.

### Imaging studies:

- Plain radiograph abdomen – erect showed calcified cyst in liver
- Ultrasonogram showed a cyst of size 6\*5 cms in left lobe of liver with calcifications in cyst wall.
- CECT abdomen & pelvis showed a well-defined calcified lesion of size 6.1 (TR) \* 5.3 (AP) \* 7(CC) with folded membranes in segment 3 & 4, compressing the left branch of portal vein.

Elective laparotomy was planned. Intraoperatively a calcified cyst of size 6\*5 cms present over left lobe of liver. After thoroughly packing the abdomen with mop pads soaked with hypertonic saline,

pericystectomy was done meticulously to avoid spillage. There were no communications of the cyst with biliary tract. Postoperative period was uneventful with the histopathology report as calcified hydatid cyst.

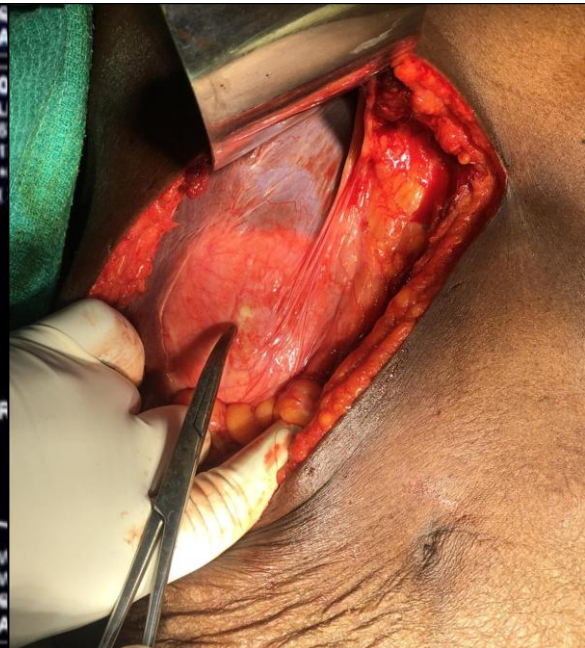
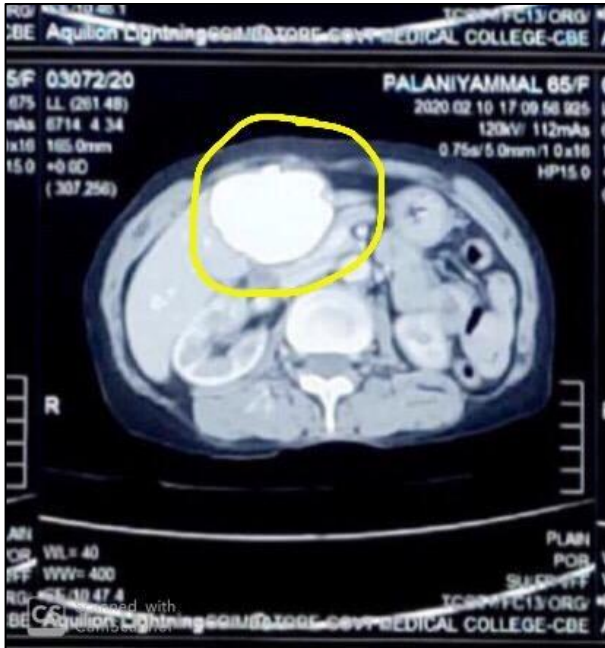

FIG 1: CT image of calcified hydatid cyst.

FIG 2: intraoperative image of calcified hydatid cyst of left lobe of liver.

### III. Discussion

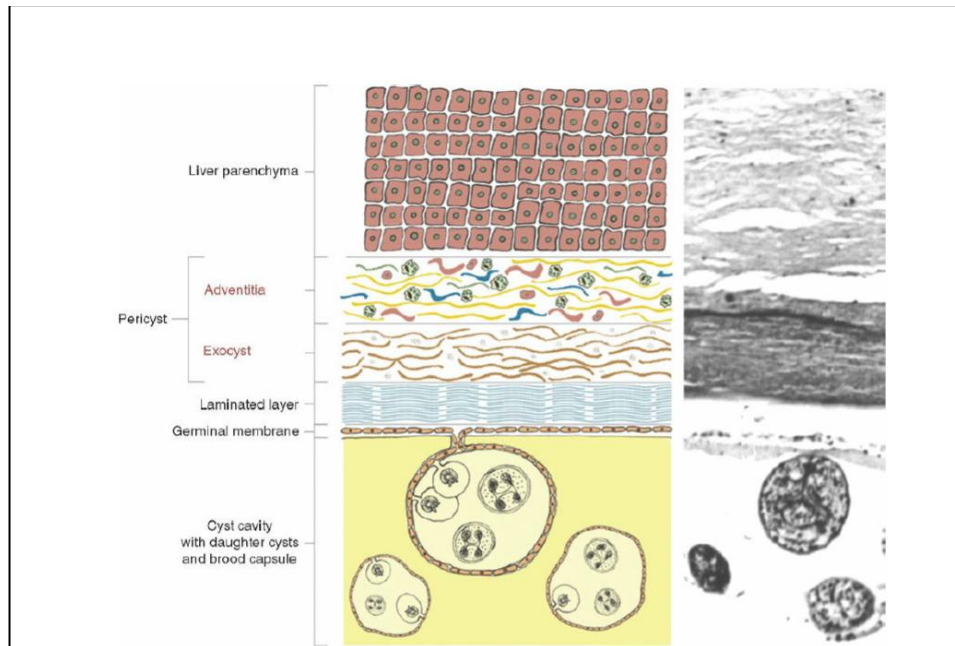
Hydatid disease or echinococcosis is a zoonosis that occurs primarily in sheep-grazing areas of the world but is common worldwide because the dog is a definitive host. Echinococcosis is endemic in Mediterranean countries, the Middle East, Far East, South America, Australia, New Zealand, and east Africa. (1) Humans contract the disease from dogs, but there is no human-to-human transmission. (2)

There are three species that cause hydatid disease. *Echinococcus granulosus* is the most common, and *Echinococcus multilocularis* and *Echinococcus ligartus* account for a small number of cases. (1) Dogs are the definitive host of *E. granulosus*; adult tapeworm is attached to the villi of the ileum. Up to thousands of ova are passed daily and deposited in the dog's feces. Sheep are the usual intermediate host, but humans are an accidental intermediate host. Humans are an end stage to the parasite. In the human duodenum, the parasitic embryo releases an oncosphere containing hooklets that penetrate the mucosa, allowing access to the bloodstream. In the blood, the oncosphere reaches the liver (most commonly) or lungs, where the parasite develops its larval stage—the hydatid cyst.

#### **Pathology:**

It has 3 layers.

- Adventitia (Pseudocyst): Inseparable fibrous tissue due to reaction of liver to parasite.
- Laminated membrane (Ectocyst): White, elastic layer formed by parasite itself.
- Germinal epithelium (Endocyst): Living part lining the cyst. It secretes hydatid fluid, brood capsule with scolices. Once brood capsule disintegrates it grows into daughter cyst.



An uncomplicated hydatid cyst typically contains a clear, colorless, odorless fluid secreted by the germinal membrane. Sodium, chloride, and bicarbonate concentrations are the same in the fluid as in the patient's plasma, whereas potassium and calcium levels are lower. In uncomplicated cysts, hydatid fluid is sterile. Bile-stained cyst fluid indicates a cystobiliary communication. When superadded infection is present, the cyst fluid appears frankly purulent; in degenerated cysts, the fluid becomes turbid. Spillage of hydatid fluid content as a result of traumatic or iatrogenic rupture produces implantation of protoscolices and secondary cysts on surrounding viscera, known as secondary hydatidosis (3). Although any segment of the liver can be involved, the location of liver hydatid cysts seems to be related to the respective volume of each lobe of the liver; thus, a higher involvement of the right lobe is observed, especially in segments VII and VIII (4). Liver hydatid cysts, left untreated grow and follow one of several courses:

- Develop fistulae with adjacent organs or the biliary system
- Rupture into the peritoneal cavity seeding daughter cysts & Anaphylaxis
- Develop daughter cysts within or rarely die.
- Calcified cyst.

The most common site of occurrence of hydatid cysts in humans is the liver (50%–93%) followed by lung, but it can also affect the brain, heart, kidney, ureter, spleen, uterus, fallopian tube, mesentery, pancreas, diaphragm and muscles. Brain involvement, which is more commonly seen in children, is encountered in 1- 2 % of the patients and the cysts are usually solitary and have an intraparenchymal localization. Cardiac involvement is uncommon (0.02 – 2 %). The left ventricular wall is the most frequent site, but the interventricular septum, right ventricle, left or right atrium may also be involved with varying degrees of complications. Major complications result from rupture of the cyst into the heart or pericardium. Death may occur subsequent to anaphylactic shock, cardiac tamponade and systemic or pulmonary hypertension. Pancreatic involvement has been reported in 0.25 – 0.75 % of adult cases and the mode of infestation is presumed to be hematogenous, although local spread via the pancreatic or bile ducts has been suggested, as well as peripancreatic lymphatic invasion. Pre-operative diagnosis of hydatid cysts of the pancreas may be difficult because it may be confused with pseudopancreatic, cystadenocarcinoma and true congenital and post-traumatic pancreatic cysts.

**Clinical features:**

- Mostly Asymptomatic
- Palpable liver with classical thrill (hydatid thrill).
- Discomfort in right upper quadrant, dyspepsia, weight loss, fatigue, vomiting
- Jaundice & pain.
- Anaphylaxis.

**Camelotte sign:**

Following intrabiliary rupture, gas enters into cyst causing partial collapse of cyst wall.

Although most patients may be asymptomatic for years or have nonspecific symptoms, about one third of the patients may present with pressure effects or complications. The pressure effect of the cyst can produce symptoms of obstructive jaundice and abdominal pain. The common complications are rupture into peritoneal cavity causing seedings & anaphylaxis, biliary communications, secondary infections, external compression leading to portal hypertension, intrathoracic rupture.

#### **IV. Complications**

##### ***Compression***

Depending on the location, large cysts can cause compression of the bile ducts with obstructive jaundice (5), of the hepatic veins with a Budd-Chiari syndrome (6), and/or of the vena cava (7). Rarely, liver hydatid cysts lead to a real presinusoidal portal hypertension (5).

##### ***Cyst Infection***

As with all liver cysts, hydatid cysts may become infected after an episode of bacteremia or via a communication with the bile ducts.

##### ***Rupture Into the Biliary Tract***

Cystobiliary communications that occur after rupture of a cyst into the bile ducts can be minor or major. Minor communications are usually asymptomatic and are revealed postoperatively by the presence of a bile leak, whereas major communications cause obstructive jaundice and cholangitis. Endoscopic retrograde cholangiopancreatography (ERCP) is useful to confirm biliary obstruction that results from hydatid material and facilitates treatment with an endoscopic sphincterotomy and extraction of the hydatid debris with a balloon or basket. (8)

##### ***Rupture Into the Bronchial Tree***

During their development, hydatid cysts of the posterior and upper segments of the liver (IVa, VII, and VIII) may stick to the diaphragm, causing indentation, and ultimately spontaneous erosion

##### ***Rupture Into the Peritoneum***

The main cause of peritoneal involvement is the intraperitoneal rupture of a hydatid cyst. This complication is rare, even in endemic regions, with an incidence ranging from 1% to 8% (9). It may occur spontaneously or after a traumatic injury (10).

##### ***Rupture Into Other Cavities or Organs***

Rupture into the gastrointestinal tract that involves the stomach and the duodenum has been reported (11). Isolated cases of rupture of liver hydatid cysts into the pericardium (12) and into large vessels, including the inferior vena cava, have also been described (13).

#### **V. Diagnosis**

The results of routine laboratory blood work are nonspecific. LHCs may be reflected in an elevated bilirubin or alkaline phosphatase level. Leukocytosis may suggest infection of the cyst. Eosinophilia is present in 25% of all persons who are infected, while hypogammaglobinemia is present in 30%.

##### ***Ultrasonography (USG)***

USG helps in the diagnosis, treatment and follow-up of patients. A simple hydatid cyst is well circumscribed with budding signs on the cyst membrane and may contain free-floating hyperechogenic hydatid sand. A rosette appearance is seen when daughter cysts are present. The cyst can be filled with an amorphous mass, which can be diagnostically misleading. Calcifications in the wall of the cyst are highly suggestive of hydatid disease and can be helpful in the diagnosis.

##### ***Hassen Gharbi's usg based classification of liver hydatid cyst:***

Type 1: Pure fluid collection.

Type 2: Fluid collection with split wall.

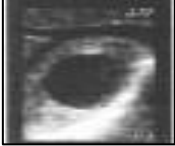
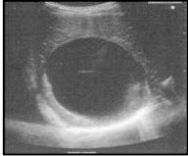
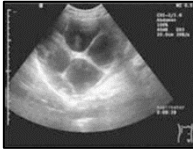

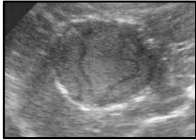
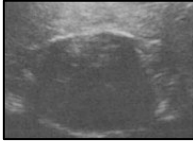
Type 3: Fluid collection with septa.

Type 4: Heterogenous appearance.

Type 5: Reflecting thick wall.

WHO informal working group on Echinococcus (IWGE) classification (Table 1) of LHCs has important consequences on treatment decision making and is widely accepted.

***Ultrasonography classification of echinococcal cyst:***

WHO IWGE	IMAGE	DESCRIPTION	STAGE
CL		Unilocular, no cyst wall.	Active
CE 1		Cyst wall present	Active
CE 2		Multivesicular rosette like cyst.	Active
CE 3		Detaching laminated membrane.	Transitional
CE 4		Degenerative contents	Inactive
CE 5		Thick calcified wall.	Inactive

***Computed Tomography (CT):***

More accurate in identifying cyst characteristics cart wheel like multivesicular rosette appearance. CT gives more precise information than US regarding the morphology of the cyst, including size, location, number, and relationships to adjacent structures. CT shows exogenous daughter cysts and cysts in the peritoneal cavity and may also show evidence of complications, such as common bile duct dilation as a result of biliary obstruction in a jaundiced patient with cholangitis because of the hydatid content in the bile duct

***MRI:***

On T2-weighted MRI, hydatid liver cysts may have a low signal intensity rim. This is a characteristic sign of hydatid disease that represents the outer, collagen-rich laminated membrane of the cyst. When present, daughter cysts are seen as cystic structures attached to the germinal layer and are hypointense relative to the intracystic fluid on T1-weighted images and hyperintense on T2-weighted images (14).

In cysts with biliary complications, MR cholangiography can provide good visualization of the intrahepatic and extrahepatic biliary tree and its relationship with the hydatid cyst and cystobiliary communications (15)

**ERCP:** Endoscopic Retrograde Cholangio Pancreatography may be done preoperatively to identify cysto-biliary communications.

**Serology:**

Different serological tests are being carried out for the diagnosis, screening and postoperative follow up for recurrence. These include hydatid immunoelectrophoresis, ELISA, latex agglutination and indirect hemagglutination test. Almost every serodiagnostic technique has been evaluated for echinococcosis, with variable results. The indirect hemagglutination test and the enzyme-linked immunosorbent assay (ELISA) have a sensitivity of 90% overall and are the initial screening tests of choice. Immunodiffusion and immunoelectrophoresis demonstrate antibodies to antigen 5 and provide specific confirmation of reactivity.

## **VI. Treatment**

The objectives of the ideal treatment are threefold:

- (1) removal of the entire parasite
- (2) removal of the residual cavity
- (3) the identification and treatment of biliary fistula.

Four treatment options are currently available: radical surgery, conservative surgery, PAIR, and antiparasitic medical treatment with benzimidazoles (BMZs).

Surgery, which is the only treatment that reaches the three objectives of the ideal treatment, is the most efficient treatment. Percutaneous and medical treatments represent alternatives to surgery.

**Surgical:**

Although the treatment of hepatic hydatid cysts is primarily surgical, alternative options are in evolution. (16) These may be conservative or radical. Conservative procedures aim at sterilization and evacuation of cyst content, including the hydatid membrane (hydatidectomy), and partial removal of the cyst. The evacuation and hydatidectomy consist of puncture of cyst and aspiration of part of the content to permit introduction of scolicidal agent and total aspiration thereafter. The risks are anaphylactic shock, chemical cholangitis, if the cyst communicates with the biliary tree, and spillage of the cyst contents and secondary hydatidosis. Relapse rates of up to 20% are reported after surgery of LHCs. After partial removal of the cyst, a residual cavity remains, bearing the risk of secondary bacterial infection and abscess formation. Radical procedures aim at complete removal of the cyst with or without hepatic resection. Radical procedures bear greater intraoperative risks, with less postoperative complications and relapses. They are considered as gold standard therapy.

Laparoscopic management of LHCs has gained ground despite the initial exaggerated fear of complications such as anaphylaxis. Various techniques such as total pericystectomy, puncture and aspiration of contents followed by marsupialization, unroofing and drainage, unroofing and omentoplasty, and omentoplasty using helical fasteners have been described. One of the problems faced in laparoscopic treatment of liver hydatid cysts is the difficulty in evacuating the particulate contents of the cyst, the daughter cysts, and laminated membrane. Bickel et al initially advocated the use of a large transparent beveled cannula. Saglam described a perforator-grinder-aspirator apparatus designed specifically for the evacuation of hydatid cysts. Palanivelu developed the "Palanivelu Hydatid System" (PHS) consisting of a complex system of fenestrated trocar and cannulas to avoid peritoneal spillage. PHS not only prevents any spillage of hydatid fluid but also assists complete evacuation of the cyst content and allows intracystic magnified visualization for cyst-biliary communication.

**PAIR:**

In the past, percutaneous aspiration of hydatid cysts was contraindicated because of the risk of rupture and uncontrolled spillage. However, percutaneous aspiration with injection of scolicidal agents has been reported with high success rates in highly selected patients. (17) This technique is known as PAIR (puncture, aspiration, injection, and reaspiration). Two randomized trials, one comparing PAIR with surgery (N = 50) and one comparing PAIR with medical therapy, have shown similar success rates. These trials were small and had significant methodologic problems, limiting the ability to draw firm conclusions. (18)

Preoperative treatment may decrease the risk of spillage and is a reasonable and safe practice. (19) Preoperative albendazole and praziquantel should be considered in order to sterilize the cyst, decrease the chance of anaphylaxis, decrease the tension in the cyst wall (thus reducing the risk of spillage during surgery)

and to reduce the recurrence rate postoperatively. Intraoperatively the use of hypertonic saline or 0.5% silver nitrate solutions before opening the cavities tends to kill the daughter cysts and therefore prevent further spread or anaphylactic reaction.

### **Adjunctive treatment**

There is some evidence for the following adjunctive measures to play a useful role.

- 1) Prevention of secondary CE and relapses
  - a) Albendazole – starting 1 week before surgery and continuing to up to 3 months after surgery. There is no uniform recommendation and the efficacy is not known.
  - b) Surgical field protection with pads soaked with scolicidal agents.
- 2) Prevention of cholangitis
  - a) If de-roofing is performed, a search for cystobiliary-fistulae is mandatory. Bile-stained fluid content, raised levels of bilirubin in the aspirated fluid and spillage of contrast on antegrade cholangiography are all indicative of cystobiliary communication.
  - b) Strictly avoiding injection of scolicidal solution into cysts that communicate with the biliary tree (cysto-biliary fistulas).
- 3) Management of the residual cavity
  - a) Ideally, cysts are completely removed to avoid residual cavities. This prevents suppuration, reduces the risk of biliary fistulas, and achieves faster healing and shorter hospital stay.
  - b) When hydatidectomy or partial or subtotal cystectomy is performed, the residual cavities are managed by simple drainage with suction and filling with epiploon (omentoplasty) to reduce the risk of complications.

## **VII. Conclusion**

Patients with hepatic hydatid cyst form a heterogeneous group (taking into account gender, age, place of origin); semiology is poor and unspecific; among laboratory examinations, eosinophilia is a sign of concern that should place the hydatid liver cyst on the differential diagnosis list; imaging, most commonly in the form of ultrasound examination, the easy, cheap and non-irradiation method is the basis of the diagnosis of hepatic hydatid cyst; minimally invasive methods have high applicability, less frequent complications and shorter hospitalization; the therapeutic solution for the hepatic hydatid cyst remains the attribute of general surgery, both by the still important role of classical and laparoscopic surgical techniques and by the ability of surgery to provide therapeutic assistance to cases treated through minimally invasive techniques. Surgical treatment remains the “gold standard” in therapy. Medical treatment should precede and follow the surgical intervention.

## **References**

- [1]. cystic echinococcosis: a case series and review of literature, *Am J Surg* 194:313–316, 2007.
- [2]. Agayev RM, Agayev BA: Hepatic hydatid disease: Surgical experience over 15 years. *Hepatogastroenterology* 55:1373–1379, 2008.
- [3]. Krige J, Beckingham JJ: Liver abscesses and hydatid disease. In Beckingham JJ, editor: *ABC of liver, pancreas, and gallbladder*, London, 2001, British Medical Journal Publishing Group, pp 29–32.
- [4]. Kayaalp C, et al: Distribution of hydatid cysts into the liver with reference to cystobiliary communications and cavity-related complications, *Am J Surg* 185:175–179, 2003a.
- [5]. Avgerinos ED, et al: Clinical presentations and surgical management of liver hydatidosis: our 20 year experience, *HPB (Oxford)* 8:189–193, 2006.
- [6]. Akbulut S, et al: Budd-Chiari syndrome due to giant hydatid cyst: a case report and brief literature review, *J Infect Dev Ctries* 7:489–493, 2013.
- [7]. Ramia JM, et al: Cysto-biliary communication in liver hydatidosis, *Langenbecks Arch Surg Dtsch Ges Für Chir* 397:881–887, 2012.
- [8]. Ozaslan E, Bayraktar Y: Endoscopic therapy in the management of hepatobiliary hydatid disease, *J Clin Gastroenterol* 35:160–174, 2002.
- [9]. Sözüer EM, et al: The perforation problem in hydatid disease, *Am J Trop Med Hyg* 66:575–577, 2002.
- [10]. Ozturk G, et al: Posttraumatic free intraperitoneal rupture of liver cystic echinococcosis: a case series and review of literature, *Am J Surg* 194:313–316, 2007.
- [11]. Diez Valladares L, et al: Hydatid liver cyst perforation into the digestive tract, *Hepatogastroenterology* 45:2110–2114, 1998.
- [12]. Thameur H, et al: Cardiopericardial hydatid cysts, *World J Surg* 25:58–67, 2001.

- [13]. Karunajeewa HA, et al: Hydatid disease invading the inferior vena cava: successful combined medical and surgical treatment, ANZ J Surg 72:159–160, 2002.
- [14]. Pedrosa I, et al: Hydatid disease: radiologic and pathologic features and complications. Radiogr, Rev 20:795–817, 2000.
- [15]. Little AF, et al: MR cholangiography in the evaluation of suspected intrabiliary rupture of hepatic hydatid cyst, Abdom Imaging 27:333–335, 2002.
- [16]. Brunetti E, Kern P, Vuitton DA: Expert consensus for the diagnosis and treatment of cystic and alveolar echinococcosis in humans. Acta Trop 114:1–16, 2010.
- [17]. Tamarozzi F, Vuitton L, Brunetti E, et al: Non-surgical and non-chemical attempts to treat echinococcosis: Do they work? Parasite 21:75, 2014.
- [18]. Nasser Moghaddam S, Abrishami A, Malekzadeh R: Percutaneous needle aspiration, injection, and reaspiration with or without benzimidazole coverage for uncomplicated hepatic hydatid cysts. Cochrane Database Syst Rev (2):CD003623, 2006.
- [19]. Mezhir J, Fong Y, Jacks L, et al: Current management of pyogenic liver abscess: Surgery is now second-line treatment. J Am Coll Surg 975–983, 2010

Dr.R. Jayakumar M. S, et. al. “Hydatid Cyst of Liver: A Case Report and Review of Literature.” *IOSR Journal of Dental and Medical Sciences (IOSR-JDMS)*, 20(08), 2021, pp. 27-34.