

Extranodal Castleman Disease of the Upper Arm presenting with joint pain: A case report

Dr. Zini Chaurasia¹, Dr. Cheta Singh¹, Dr Prateek Garg².

¹ Department of Pathology, Dr Baba Saheb Ambedkar Medical College and Hospital

² Department of Orthopedics, Dr Baba Saheb Ambedkar Medical College and Hospital

Corresponding author: Dr. Zini Chaurasia

Abstract:

Hyaline vascular type Castleman Disease (HVCD) is a rare benign disorder characterised by lymphoid hyperplasia. Mediastinum is the most common site of occurrence with extremities being rare. We describe a case of HVCD of upper arm in a 35 year old female presenting with predominantly a soft tissue, superficial swelling in right arm and excised as soft tissue tumor.

Key words: Hyaline vascular type castlemans disease, extremity, Soft tissue tumor.

Date of Submission: 18-09-2021

Date of Acceptance: 03-10-2021

I. Introduction:

Benjamin Castleman described a case series of 13 patients who presented with enlarged mediastinal lymph nodes and were erroneously diagnosed as thymoma. He described two prominent histopathological features in these lymph nodes that were separate from other lymphoproliferative disorders and neoplasms. These features were hyperplasia of lymphoid follicle and marked capillary proliferation [1]. Castleman disease presents as an interesting differential to a variety of malignancies, including follicular dendritic cell sarcoma, Kaposi's sarcoma (KS), non-Hodgkin's lymphoma, Hodgkin's lymphoma [2,3]. In recent years it has been associated with POEMS syndrome as well as with the human immunodeficiency virus (HIV) and human herpesvirus 8 (HHV-8) [4,5]. Histologically two variants of CD have been described : Hyaline vascular Castleman disease (HVCD) and plasma cell Castleman disease (PCCD). Of the two histological variants, HVCD accounts for 90% of cases and most commonly presents as a mediastinal nodal mass [6,7,8]. Few cases of Castleman disease in the extremities have been reported in the English literature [9-11].

II. Case Report:

A 35 years old female presented with a swelling and pain on her right upper arm for 3 years. The patient complained that initially the swelling was painless but now not only was it painful but also restricted her elbow joint. No history of previous tuberculosis could be elicited. There was no other swelling present in the patient. Examination revealed a soft, well defined, 4cm swelling on the medial aspect of upper mid arm. Conventional radiograph revealed a soft tissue tumor. Excisional biopsy was performed and the tissue was received in 10% buffered formalin for histopathological examination. Grossly the tissue was globular measuring 4.5x2.5x2 cms. On cut section it was hemorrhagic. Histological examination revealed a capsulated mass with hyperplasia of lymphoid follicles separated by thick collagenised bands, marked capillary proliferation by medium sized vessels surrounded by fibrosis [Figure 1a]. At few places rimming of lymphocytes in "onion skin" manner was also appreciated [Figure 1b]. Also at few places plasma cell along with lymphocytes in the fibrosed tissue were appreciated. Considering the microscopic findings, A diagnosis of Hyaline vascular type Castleman's Disease was given. The patient was lost in follow up.

III. Discussion:

In 1954, Benjamin Castleman described a separate entity from lymphoproliferative disorders and neoplasms. These lesions mainly occurred in mediastinal lymph nodes and were misdiagnosed as thymoma. He described them as hyperplasia of lymphoid follicles and capillary proliferation that accounted for excessive bleeding on surgery in these patients [1]. Histologically three types have been described: a) Hyaline Vascular type CD, b) plasma cell type and c) Mixed type showing features of both HVCD and PC [12]. Most common sites of involvement include mediastinum or retroperitoneum [13,14]. Extremities are rarely involved [14]. The mean age of presentation has been given as 18 years by Eward et al [15]. Though our patient is a little older, several case reports have mentioned older age of presentation [15]. The knowledge on radiological findings was

sparse regarding to CD and often showed non specific fetatures of soft tissue tumors, vascular tumors, malignant lymphoma [14,15]. This often led to a misdiagnosis clinically. Also the proliferation of blood vessels may point to a cavernous hemangioma. Additionally, it is important to recognize and diagnose Castleman disease because of its potential for transformation into follicular dendritic cell sarcoma. To the best of our knowledge only one case of recurrence of CD has been reported in a patient with a nasopharyngeal HVCD mass which recurred 8 years after excision [16].This same patient developed a follicular dendritic cell sarcoma 11 years after excision of the primary [16].In summary, the diagnosis of castlemans has always been challenging, especially when presenting at unusual locations. We have described this case with the hopes that it will sensitize the clinicians to consider Castleman disease when atypical soft tissue masses of the extremities are encountered.

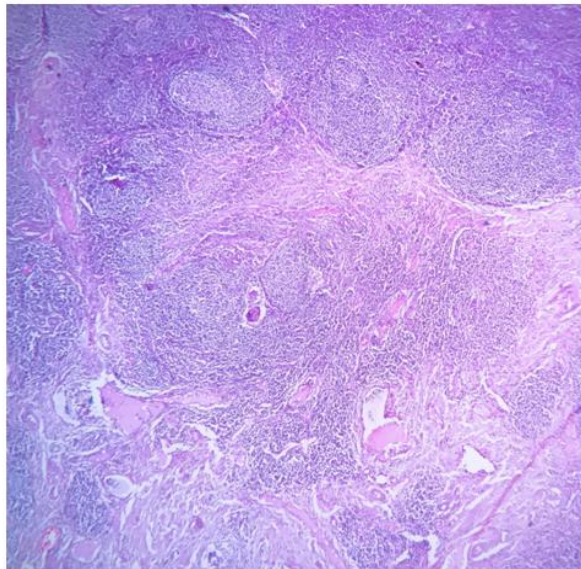


Figure 1a: H & E, 10X: Microscopy showing hyperplasia of lymphoid follicles separated by thick collagenised bands, marked capillary proliferation by medium sized vessels surrounded by fibrosis

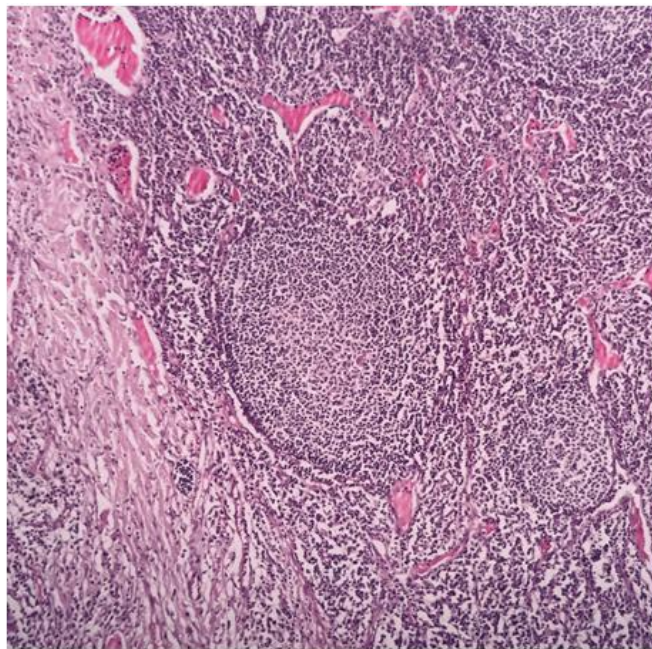


Figure 1b: H & E, 40X: Microscopy showingrimming of lymphocytes in "onion skin" manner

References:

- [1]. Castleman B, Towne VW. Case records of the Massachusetts General Hospital: Case No. 40231. *N Engl J Med* 1954; 250:1001-05.
- [2]. Soulier J, Grollet L, Oksenhendler E, et al. Kaposi's sarcoma- associated herpesvirus-like DNA sequences in multicentric CD. *Blood* 1995;86:1276-80.
- [3]. Moore PS, Chang Y. Detection of herpesvirus-like DNA sequences in Kaposi's sarcoma in patients with and without HIV infection. *N Engl J Med* 1995;332:1181-85.
- [4]. Chang Y, Cesarman E, Pessin MS, Lee F, Culpepper J, Knowles DM, Moore PS. Identification of herpesvirus-like DNA sequences in AIDS-associated Kaposi's sarcoma. *Science* 1994;266:1865-69.
- [5]. Dupin N, Gorin I, Deleuze J, Agut H, Huraux JM, Escande JP. Herpes-like DNA sequences, AIDS-related tumors, and Castleman's disease. *N Engl J Med* 1995;333:798-99.
- [6]. Kazakov DV, Fanburg-Smith JC, Suster S, Neuhauser TS, Palmedo G, Zamecnik M, Kempf W, Michal M. Castleman disease of the subcutis and underlying skeletal muscle: Report of 6 cases. *Am J Surg Pathol* 2004;28(5):569-77.
- [7]. Fiel-Gan MD, Voytek TM, Weiss RG, Brown RT, Joshi VV. Castleman's disease of the left triceps in a child suspected to be a small round cell tumor of childhood. *Pediatr Dev Pathol* 2000;3(3):286-89.
- [8]. Rooney RC, Pitcher JD. Castleman's disease in the extremity. *Am J Orthopsychiatry* 1998;27:373-74.
- [9]. Dargent JL, Delplace J, Roufosse C, Laget JP, Lespagnard L. Development of a calcifying fibrous pseudotumour within a lesion of Castleman disease, hyaline-vascular subtype. *J Clin Pathol* 1999;52:547-49.
- [10]. Skelton HG, Smith KJ. Extranodal multicentric Castleman's disease with cutaneous involvement. *Mod Pathol* 1998;11: 983-89.
- [11]. Cohen H. Tumor-like proliferations of lymphoid tissue— occurrence in deltoid muscle and mediastinum. *J Mount Sinai Hosp* 1957;24:750-60.
- [12]. Keller AR, Hochholzer L, Castleman B. Hyaline vascular and plasma cell types of giant lymph node hyperplasia of the mediastinum and other locations. *Cancer* 1972;29:670-83.
- [13]. Falchi L, Capello D, Palumbo B, Rauco A, Emili R, Cianciulli M, Pace R, Capparella V, Liberati F, Liberati AM. A case of nodular sclerosing Hodgkin's lymphoma repeatedly relapsing in the context of composite plasma cell-hyaline vascular Castleman's disease: Successful response to rituximab and radiotherapy. *Eur J Haematol* 2007;79(5):455-61.
- [14]. Frizzera G. Castleman's disease: More questions than answers. *Hum Pathol* 1985;16:202-05.
- [15]. Eward WC, DeWitt SB, Brigman BE, Kontogeorgakos V, Lagoo AS. Extranodal Castleman disease of the extremities: a case report and review of the literature. *Skeletal Radiol.* 2014 Nov;43(11):1627-31. doi: 10.1007/s00256-014-1945-z. Epub 2014 Jun 27. PMID: 24970669.
- [16]. Chan ACL, Chan KW, Chan JKC, Au WY, Ho WK, Ng WM. Development of follicular dendritic cell sarcoma in hyaline- vascular Castleman's disease of the nasopharynx: Tracing its evolution by sequential biopsies. *Histopathology* 2001;38: 510-18.

Dr. Zini Chaurasia, et. al. "Extranodal Castleman Disease of the Upper Arm presenting with joint pain: A case report." *IOSR Journal of Dental and Medical Sciences (IOSR-JDMS)*, 20(9), 2021, pp. 36-38.