

## BLUE GLOW - Inadvertent Vitreous staining with Trypan blue dye

Dr.Sree Divya Koya<sup>1</sup>, Dr.Kruti Shah<sup>1</sup>, Dr.Haritha Veluri<sup>1</sup>,  
Dr.Ashok Kanakamedala<sup>2</sup>

*1Department of Cornea, Anterior Segment, Sankara Eye Hospital, Guntur.*

*2Department of Vitreo-Retina, Sankara Eye Hospital, Guntur.*

**Purpose :** To report a case of prolonged vitreous staining with Trypan blue, till 3 weeks.

Date of Submission: 25-10-2022

Date of Acceptance: 06-11-2022

### I. Methodology:

A 20 year old male presented with history of trauma to right eye with a thorn 2 days ago, followed by decreased vision in right eye. On examination visual acuity in right eye was counting fingers 2 meters, left eye was 6/6. Anterior segment examination of right eye revealed a corneal tear about 3 mm in paracentral area, with loose fluffy cortical material in anterior chamber, with traumatic cataract. Fundus examination was not possible due to corneal tear and traumatic cataract. USG Bscan was avoided due to open globe injury. Left eye anterior segment and fundus were within normal limits. Patient underwent right eye primary corneal tear repair with lens aspiration of traumatic cataract. Corneal tear was sutured with 10-0 mono filament nylon suture, anterior capsule was stained with trypan blue to identify the site of capsular breach, traumatic cataract removal was done with bimanual irrigation aspiration cannula, with intact posterior capsule.

On Post operative day-1, tear was well apposed, anterior chamber was well formed, pupil was round, aphakic, with intact PC. Alteration of fundal glow was observed, with bluish glow from fundus. On examination with +90D lens and IDO, bluish glow from fundus was noted without any retinal pathology, so vitreous staining with trypan blue was confirmed. Most probable etiology will be trypan blue dye penetrating through zonules, due to weak zonules post trauma. Patient was prescribed topical antibiotics, topical steroid eye drops.

-During post-op 1 week follow up bluish glow from fundus was still persistent, with aphakic correction patient's visual acuity improved to 6/12.

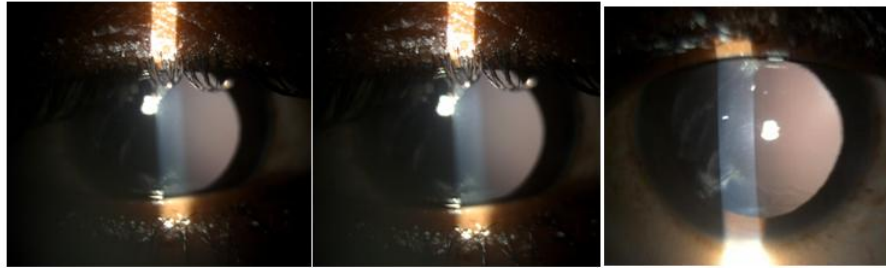
-During post-op 2 weeks follow up, bluish glow from fundus was still present, with decreased intensity.

-During post op 3 weeks followup, bluish glow from fundus almost disappeared.

-During 1 month follow up: normal fundal glow was present, on examination with +90D lens and IDO, vitreous was clear, without any bluish hue. Patient's vision improved to 6/6 with aphakic correction, indicating nil toxicity on retina due to trypan blue. Additional diagnostic evaluation is needed to clarify the damage caused by this staining.

### II. Conclusion:-

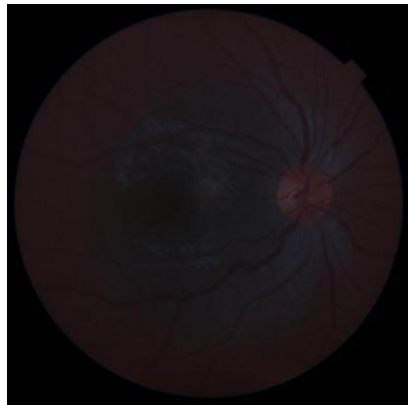
We are reporting this case, because here, corneal tear was very small, about 3mm, almost para-central, trauma is penetrating type so less likely to cause zonular damage, though in trauma cases vitreous staining with trypan blue is common, dye will disappear on next post operative day, or usually by the end of 1<sup>st</sup> post operative week.<sup>1,2</sup> In this case, prolonged retention of stain in vitreous till post-operative 3 weeks, is a rare entity.



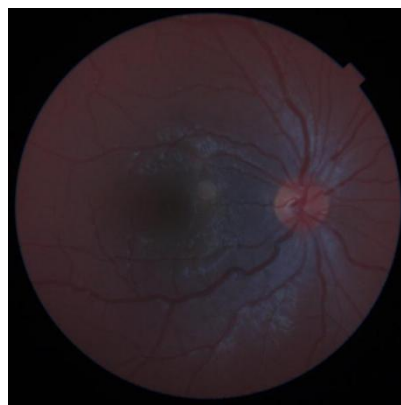
post op week 1 showing blue glow in retro-illumination.

Bluish glow in retro-illumination post op week-2

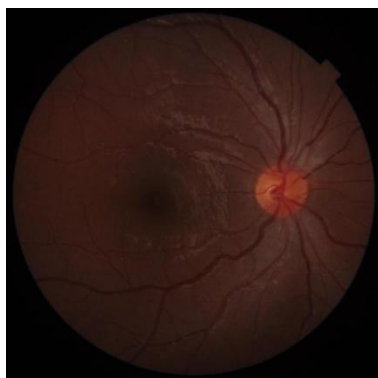Post op week-3 showing normal glow in retro-illumination



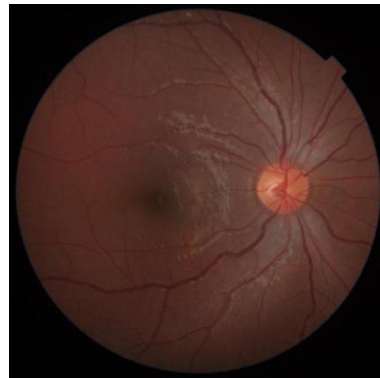POD-1: Intense bluish discoloration of vitreous with trypan blue



POD-8 : showing dye retention in vitreous



Post op - week 2 follow up showing minimal retention of dye.



Post op- week 3 showing normal fundus

**Trypan blue dye:**

Trypan blue is a blue hydrophilic anionic azo dye.<sup>1</sup> It is unable to cross cell membranes in living cells, and thus is only able to stain dead cells with compromised cell membranes. ERM contains a relatively high number of dead glial cells, and thus has a high affinity for trypan blue. Due to its hydrophilicity, trypan blue also has a weak affinity for the ILM and vitreous.<sup>2,3</sup> Trypan blue is seldom used to only stain the ILM or vitreous, as other dyes (such as indocyanine green and corticosteroids) provide superior visualization.

**Uses-**

Anterior segment(0.06%): To stain anterior capsule of lens, posterior stromal fibres in DLEK, endothelium in DSEK.

Vitrectomy: to enhance identification, delination, removal of ERM.  
Oculoplasty : to stain Tenon's capsule during enucleation.

Trypan blue is a dye that facilitates anterior lens capsule visualization and capsule manipulation during cataract surgery.<sup>4,5</sup> Trypan blue staining of the posterior capsule and anterior vitreous is uncommon; reports in the literature indicate that it may occur in eyes with ocular trauma, history of ocular surgery, or pseudoexfoliation.<sup>3,6,7</sup> Migration of dye to the posterior chamber and vitreous cavity through areas of zonular weakness has been implicated as the probable cause of anterior vitreous and posterior capsule staining

**Risk factors for vitreous staining during cataract surgery : 1,2,3**

- Post uveitis
- Iris atrophy s/p trauma causing zonular deficit
- Prostrate medication
- Surgical manipulation: iris hooks- iris retractors lift the iris, thereby facilitating the passage of trypan blue through the intact zonules to the posterior chamber
- Peripheral iridotomy
- Excessive use of viscoelastics- increase intraocular pressure and force the posterior migration of the dye through intact zonules
- Pseudoexfoliation syndrome
- High myopia- peripheral irido-lenticular space is more porous in eyes with higher axial length, permitting posterior flow of dye.

**Precautions:**

- Staining under air, viscoelastic
- Attaching iris retractors parallel to iris plane without elevation.
- Injecting viscoelastic in peripheral irido-lenticular space, to act as a barrier for posterior migration of dye.
- Mixing visco-elatic and trypan blue.

**Clearance time:**

Case reports were showing Mild staining noted intra-operatively would resolve with in post-operative 1 week or 10 days. There was one case report showing prolonged retention of dye upto 77 days.

**Toxicity:**

Trypan blue in high concentrations (above 0.5%) may have toxic effects on the retina.

**III. Conclusion:-**

Trypan blue staining of the posterior capsule and anterior vitreous can occur during phacoemulsification in eyes with risk factors related to cataract surgery as well as in eyes with no zonular pathology. Trypan blue in the posterior segment causes no detectable early problems other than increasing the risk of surgical complications by interfering with visualization of the posterior capsule and capsulorhexis intraoperatively, and it disappears usually after the first week. Toxic effects on retina are rare, and only seen in higher concentrations.

**References:**

- [1]. Ho, Derek K.-H. MA(Cantab), FRCOphth; Rajkumar, Kadaba N. MS, FRCS(Ed). Inadvertent vitreous staining with trypan blue. Journal of Cataract & Refractive Surgery: August 2020 - Volume 46 - Issue 8 - p 1198-1199 doi: 10.1097/j.jcrs.0000000000000239
- [2]. Kayıkçioğlu ÖR, Mayalı H, Doğruya S, Alp Ş, Yılmazlar AA, Kurt E. Unintentional Staining of the Anterior Vitreous with Trypan Blue During Cataract Surgery. Turk J Ophthalmol. 2020 Oct 30;50(5):308-312. doi: 10.4274/tjo.galenos.2020.94580. PMID: 33342199; PMCID: PMC7610048.
- [3]. Chowdhury PKRaj SMVasavada AR Inadvertent staining of the vitreous with trypan blue. J Cataract Refract Surg 2004;30 (1) 274- 276
- [4]. Jacobs DS, Cox TA, Wagoner MD, Ariyasu RG, Karp CL; American Academy of Ophthalmology; Ophthalmic Technology Assessment Committee Anterior Segment Panel. Capsule staining as an adjunct to cataract surgery: a report from the American Academy of Ophthalmology. Ophthalmology. 2006;113:707-713. [PubMed] [Google Scholar]
- [5]. Sharma N, Bhartiya P, Sinha R, Vajpayee RB. Trypan blue assisted phacoemulsification by residents in training. Clin Exp Ophthalmol. 2002;30:386-387. [PubMed] [Google Scholar]
- [6]. Bacsal KME, Chee SP. Trypan blue-associated retinal toxicity post complicated cataract surgery. Eye (Lond). 2006;20:1310-1311. [PubMed] [Google Scholar]
- [7]. Birchall W, Raynor MK, Turner GS. Inadvertent staining of the posterior lens capsule with trypan blue dye during phacoemulsification. Arch Ophthalmol. 2001;119:1082-1083. [PubMed] [Google Scholar]