

Uveal melanoma, meningioma; a complex neurochristopathy: a case report

MRAD Khalil , HNICH Hajar, AKENNOUR Younes , BOUSLAMTI Ahmed , LAKHDARI Meryem ,ROBBANA Lobna ,Abdallah El hassan , Berraho Amina
Department of Ophthalmology B, Ibn Sina Hospital, University Mohamed V, Rabat, Morocco.

Abstract:

Uveal melanoma as well as meningioma have both the neural crest as embryological origin , these tumors are called neurochristopathy , Simple neurochristopathies are unifocal and localized while complex neurochristopathies are multifocal, hence we present a case of a 67-years-old Caucasian woman who consulted in our ophthalmology department for uveal melanoma , during the systemic assessment the brain MRI showed a left temporal occipital meningioma .this case highlight the importance of a good investigation in front of a neurochristopathie in order to find a complex neurochristopathie.

Date of Submission: 15-12-2022

Date of Acceptance: 30-12-2022

I. Introduction :

Uveal melanoma is the most common primary intraocular tumor in adults with an incidence of 5.1 cases per million per year [1]. Meningiomas are extra-axial central nervous system (CNS) tumors which have a female predominance and occurs in middle-to-late adult life, most meningiomas (90%) are benign, 6% are atypical and a small proportion (2%) are malignant [2][3] .we will present a case of a 60 years old woman who developed a meningioma and chroidal melanoma .

II. Case Report :

We report a case of a 67-years-old Caucasian woman who consulted at the ophthalmology department for myodesopsia and blurry vision in the left eye of 1 month duration. The patient had a moderate headache involving for two months with no other medical background. She did not have any family history of melanoma. She was a nonsmoker and did not consume alcohol or recreational drugs. Ophthalmic examination was carried out, the patient had a best-corrected visual acuity of 9/10 in the right eye and 5/10 in the left eye. No abnormalities were found on the right eye .Regarding the left eye, the anterior segment was normal while we observed a temporal sentinel vessel at 2 mm from the limbus. On extended ophthalmoscopy, there was a melanotic choroidal lesion with 4, 5 *12mm basal diameter, overlying subretinal fluid, and the retina was elevated adjacent to the lesion (Figure 2). Fluorecein angiography showed central hypofluorescence by mask effect of melanoma with early hyperfluorescence of the retinal vessels as well as on the edges of the melanoma corresponding to serous detachment (Figure 3).On B-scan, there was a large, dome-shaped, regularly structured, moderately reflective lesion temporally in the periphery with 12,2 mm in largest diameter for a thickness of 5,8 mm (Figure 4). We also noticed a serous detachment of the peritumoral neuroepithelium without choroidal excavation.

Our examination and imaging were consistent with the diagnosis of a malignant melanoma of the choroid. The tumor was classified as T4N0M0 according to the TNM staging.

A complete systemic assessment was performed, the brain MRI showed a left occipital extra axial process based on implantation on the head of the cerebellum, hypointense on T1 (Figure 5) and hyperintense on T2 (Figure 6) with intense and homogeneous enhancement on T1 c + , measuring 33 x 21 mm which seems to extend to the posterior cerebral fossa through the tent of the cerebellum, corresponding to a left temporal occipital meningioma. No evidence of metastatic disease has been shown on complete body CT scan, liver ultrasound and blood tests s. Once the diagnosis was made, an interdepartmental team was assembled to determine the best course of action. The treatment options were limited due to the lesion size and the location, thus radiotherapy was proposed. The meningioma was respected with regular follow-up by neurosurgery.

III. Discussion :

Neural crest is a pluripotent structure capable of generating various derivatives such as leptomeninges, melanocytes, peripheral nervous system, the entire autonomic nervous system, chromaffin cell system (including the adrenal medulla), and the connective tissue of the face [4]. Neural crest precursors exist in the dorsal neural folds. The dorsal fusion of the neural folds form the neural tube, discrete cell masses split off from its dorsal midline and form the neural crest. After their formation, the neural crest cells migrate and give rise to the structures above. Neural crest cells also subsist in adults, in the stem cell state, which can be involved in regenerative processes. However, when their morphogenetic program is altered, they can generate multiple tumors, in the skin, the nerves (benign and malignant tumors of the nerve sheaths, neurofibromas,) and the brain (50% of cases of brain tumors with a third of optic pathway gliomas are cancerous). [5] Disorders resulting from aberrations in the growth and development of neural crest-derived structures are called "neurocristopathies." Simple neurocristopathies are unifocal and localized pathological processes. They involve tissues derived from neural crest cells, including neuroblastomas, pheochromocytomas, medullary carcinomas of the thyroid, meningiomas and peripheral neuroectodermal tumors. Neurocristopathy occurring in multiple sites and forms constitute the "complex neurocristopathies"; they are variegated associations of simple neurocristopathies. [4] The neurofibromatosis are the most common examples of complex neurocristopathies and are characterized by pathological hamartomatous proliferations of neural crest-derived tissues. Associated with meningiomas, malignant melanomas neurofibromas, schwannomas, pheochromocytomas, and gliomas. Our patient had a combination of two tumors of neural crest origin making it a complex neurocristopathy, however he did not meet the criteria for either neurofibromatosis type 1 or type 2.

IV. Conclusion :

Through our case we'd like to emphasize that in front of any malignant melanoma of the choroid which is considered as a simple neurocristopathy, it is mandatory to look for another tumor of the neural crest in order to identify a complex neurocristopathy, which can influence the prognosis of the disease.

References

- [1]. Kaliki, S., & Shields, C. L. (2016). Uveal melanoma: relatively rare but deadly cancer. *Eye*, 31(2), 241–257. doi:10.1038/eye.2016.275
- [2]. Mirimanoff RO, Dosoretz DE, Linggood RM *et al*. Meningioma: analysis of recurrence and progression following neurosurgical resection. *J. Neurosurg.* 62, 18–24 (1985).
- [3]. Jaaskelainen J. Seemingly complete removal of histologically benign intracranial meningioma: late recurrence rate and factors predicting recurrence in 657 patients: a multivariate analysis. *Surg. Neurol.* 26, 261–469 (1986).
- [4]. Bolande RP Neurocristopathy: its growth and development in 20 years. *Pediatr Pathol Lab Med.* 1997;171- 25
- [5]. Warwar RE, Bullock JD, Shields JA, Eagle RC. Coexistence of 3 Tumors of Neural Crest Origin: Neurofibroma, Meningioma, and Uveal Malignant Melanoma. *Arch Ophthalmol.* 1998;116(9):1241–1243. doi:10.1001/archophth.116.9.1241

ICONOGRAPHY :

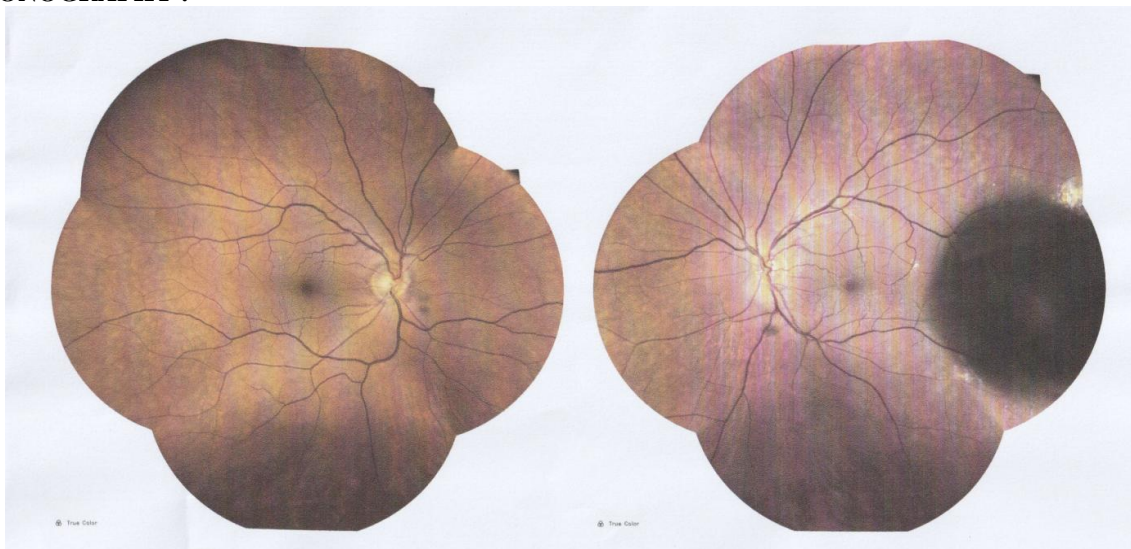


Figure 1 : normal fundus photograph of the right eye

Figure 2 : Fundus photograph of left eye showing a temporal pigmented choroidal tumor with overlying intraretinal hemorrhages

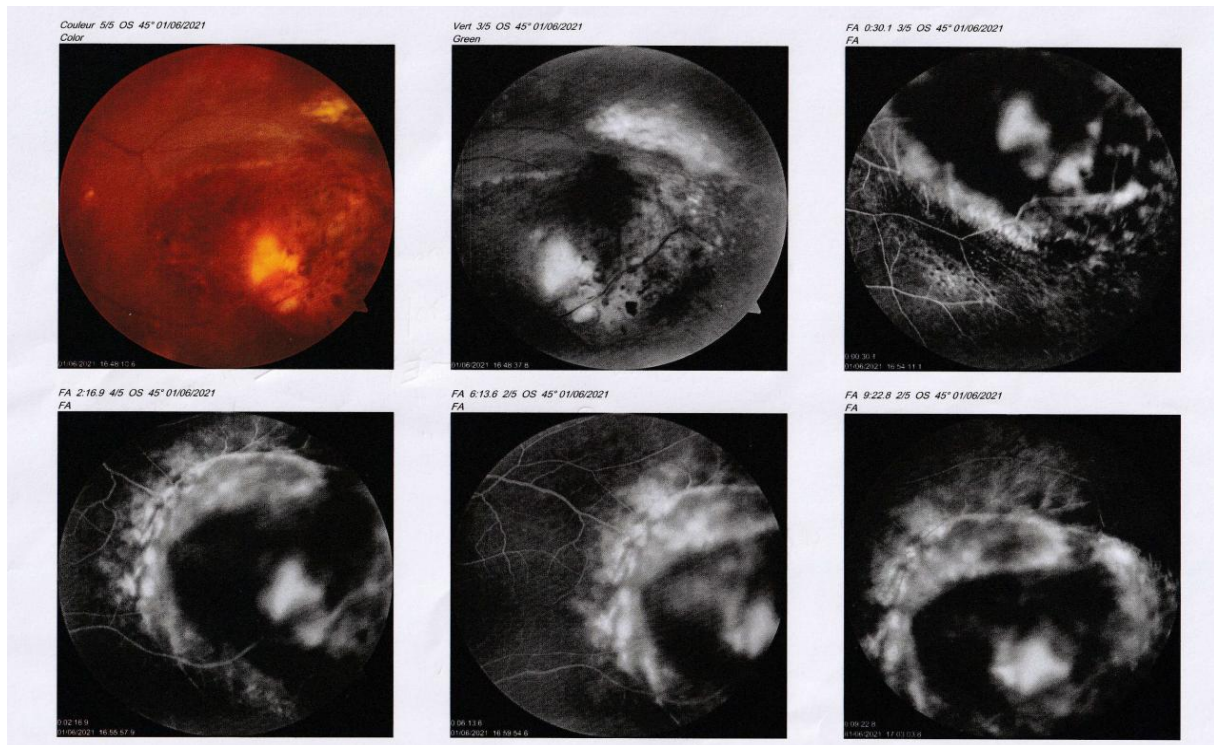


Figure 3 : Fluorecein angiography of the left eye showing a central hypofluorescence of the lesion with an early hyperfluorescence of the retinal vessels as well as the edges of the melanoma corresponding to serous detachment

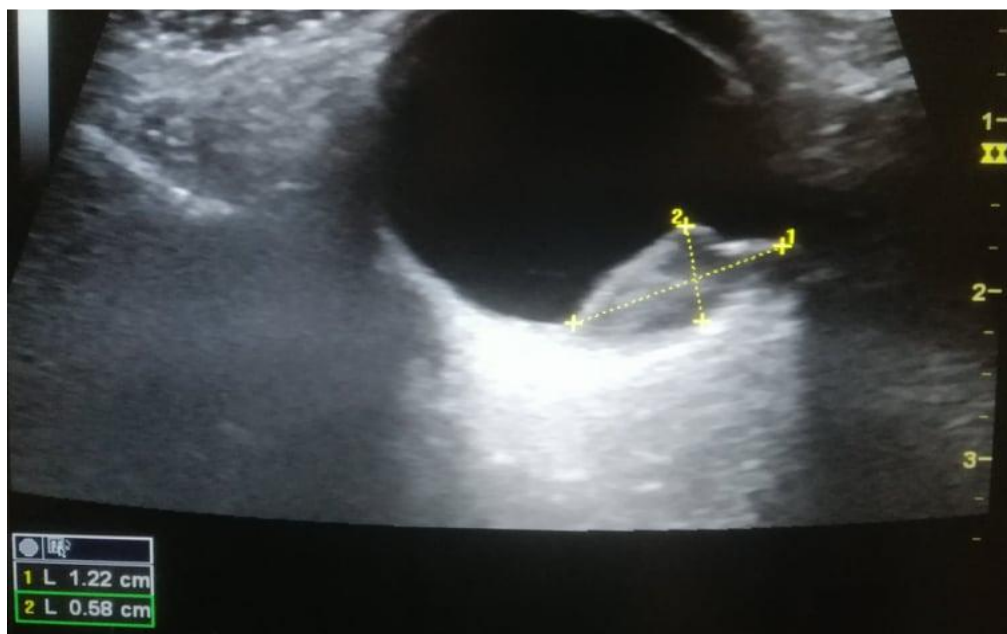


Figure 4: B-SCAN of the left eye showing a dome-shaped, regularly structured, moderately reflective lesion temporally in the periphery with 12,2 mm in largest diameter for a thickness of 5,8 mm

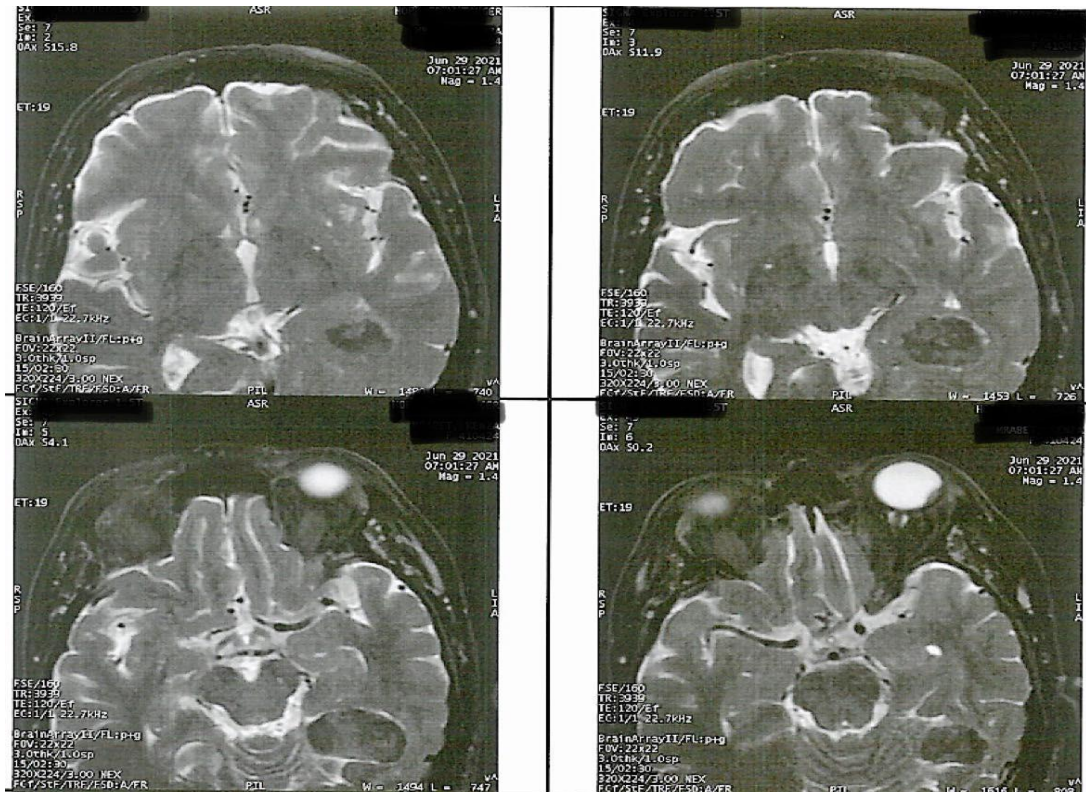


Figure 5: Brain MRI showing a left temporal occipital meningioma hypointense on T1

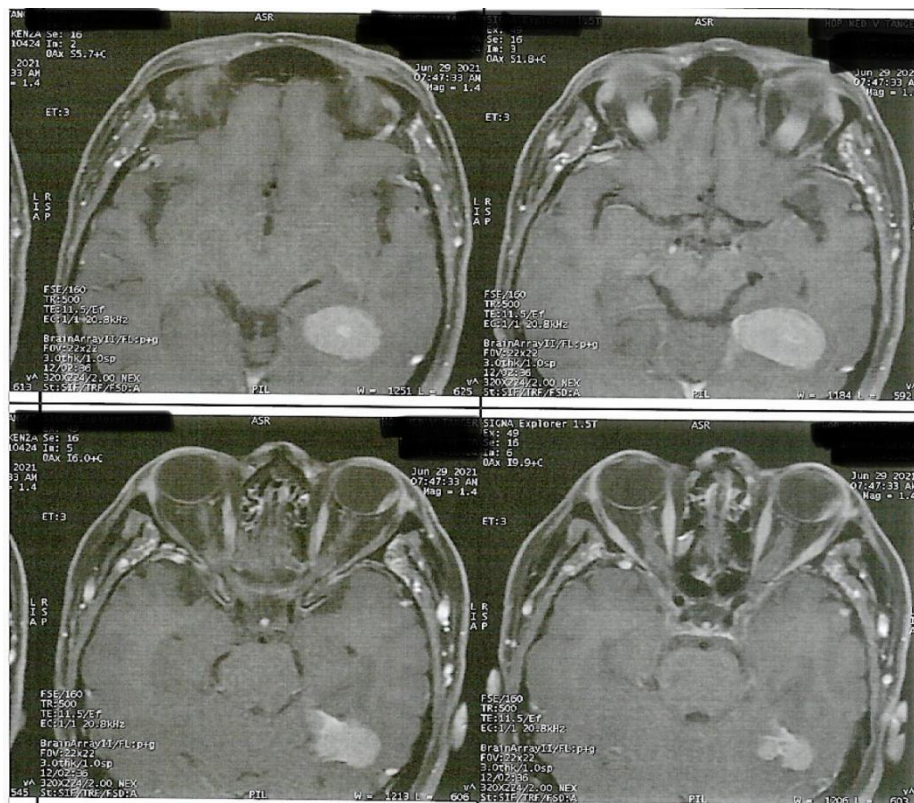


Figure 6: Brain MRI showing a left temporal occipital meningioma hyperintense on T2