

Lip Prints- An Emerging Tool for Personal Identification

Dr. Shaji T Varghese¹, Dr. Muhammed Sajjed², Dr. Lijo K Jose³, Dr. Hrudya Balachandran⁴, Dr. Pramada Kishore⁵, Dr. Arun PB⁶, Dr. Jayaraj AA⁷.

¹Professor &HOD, Department of Orthodontics, PSM Dental College / KUHS, Kerala, India

²Post graduate student, Department of Orthodontics, PSM Dental College / KUHS, Kerala, India

³Professor, Department of Orthodontics, PSM Dental College / KUHS, Kerala, India

⁴Reader, Department of Orthodontics, PSM Dental College / KUHS, Kerala, India

⁵Senior Lecturer, Department of Orthodontics, PSM Dental College / KUHS, Kerala, India

^{6,7}Post graduate student, Department of Orthodontics, PSM Dental College / KUHS, Kerala, India

Abstract:

Background: Lip prints are the normal lines and fissures in the zone of transition of human lip between mucosa and the skin. The study of lip prints is known as cheiloscopy. Like finger prints lip prints are permanent, unchangeable and unique to each person except in monozygotic twins. They are identifiable as early from the sixth week of intrauterine life. The present study was aimed to determine the prevalence of lip pattern among males and females in Malabar population.

Materials and Methods: A study group of 240 patients (120 males and 120 females) in the age group 13-30 years were selected for the study. Red coloured Dazzler Matte finish Lipstick was used and the most commonly used lipstick-cellophane technique was adopted in the study. The cellophane strip was then stuck to the study proforma for permanent record and the lip impressions were subsequently visualized with the use of a 10X magnifying lens.

Results: When the lip patterns were compared between male and female subjects of the total selected samples, the branched lip pattern was most common in males and the reticular lip pattern was common in females with a significant p-value of 0.007.

Conclusion: Lip prints, because of their uniqueness act as a legitimate means of identifying the sex of a person.

Key Word: Cheiloscopy.

Date of Submission: 06-02-2022

Date of Acceptance: 20-02-2022

I. Introduction

The lip prints are unique to an individual just like the fingerprints and shows strong hereditary pattern.¹ The unique pattern of lip prints has reduced the challenges faced by man in early days to provide the identity of an individual. The importance of cheiloscopy is that lip prints are genetic and shows a strong familial tendency. Therefore the lip prints once formed are unchangeable even after death and unique to each person except in monozygotic twins.³ The lip prints are developed at the sixth week of intrauterine life.²

The present study was aimed to determine the prevalence of lip pattern among males and females in Malabar population.

Historical inspection

It was only in 1932 that Edmond Locard, one of France's greatest criminologists, recommended the use of lip prints in personal identification and criminalization.⁴ In 1950, Synder reported in his book Homicide Investigation that the characteristics of the lips formed by lip grooves are as individually distinctive as the ridge characteristics of finger prints.⁵ Cottone in 1981, reported in his book Outline of Forensic Dentistry, that cheiloscopy is one of the special techniques used for personal identification.⁴

II. Material And Methods

A study group of 240 patients (120 males and 120 females) in the age group 13-30 years were chosen randomly from the patients coming to the department of Orthodontics, PSM college of Dental science and Research Thrissur., hailing from different districts of Malabar population in Kerala State, India.

All the subjects were informed about the purpose and objective of the study and a signed informed consent form was obtained from all. Subjects with any kind of malformation, deformity, inflammation, trauma,

and scars on the lips were excluded from the study. People either sensitive or allergic to lipsticks were also excluded from the study.

Red colored Dazzler Matte finish Lipstick was used for the study (Fig 1). The most commonly used lipstick-cellophane technique was adopted in the study as proposed by Sivapathasundaram et al.⁶ (Fig 1). The subjects were asked to sit with lips closed and relaxed position on a dental chair, and the lips of the subjects were cleaned with the help of wet cotton. Red colored lipstick was applied on each lip evenly using a disposable cotton bud (Fig 1). The subjects were asked to rub both the lips together to spread the lipstick evenly. Over the lipstick, the glued portion of the cellophane tape strip was placed and a lip impression was made. (Fig 3). The cellophane strip was then stuck to the study proforma for permanent record and the lip impressions were subsequently visualized with the use of a 10X magnifying lens. The middle part of the lower lip (10 mm wide) was taken as study area for classification.

The lip print pattern was determined by counting the highest number of lines in the middle part of the lower lip. (Fig 4).

The classification of lip print patterns as proposed by Tsuchihashi,⁷ was followed which was:

- Type I : Clear-cut vertical grooves that run across the entire lips.
- Type I' : Similar to type I, but do not cover the entire lip.
- Type II : Branched grooves (branching Y-shaped pattern).
- Type III : Intersected grooves (criss - cross pattern, transverse grooves).
- Type IV : Reticular grooves.
- Type V : Undetermined (grooves do not fall into any of the type I-IV and cannot be differentiated morphologically).

Type I i.e., full vertical grooves and type I' i.e., partial vertical grooves were very difficult to differentiate between each other, therefore were considered as a single group in this study.

Statistical analysis

Data was analyzed using SPSS (statistical package for social sciences) version 20 (SPSS Inc., Chicago, IL). Pearson Chi-square test was used to ascertain the significance of differences between the variables. The level $P < 0.05$ was considered as the cutoff value or significance.

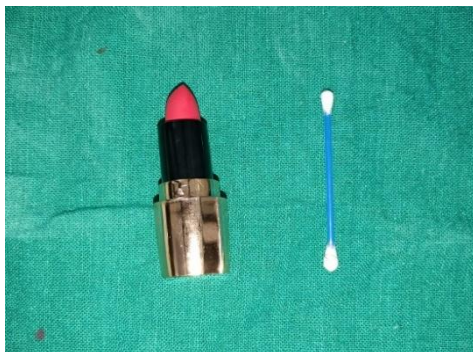

Fig 1: Lip stick and Ear bud

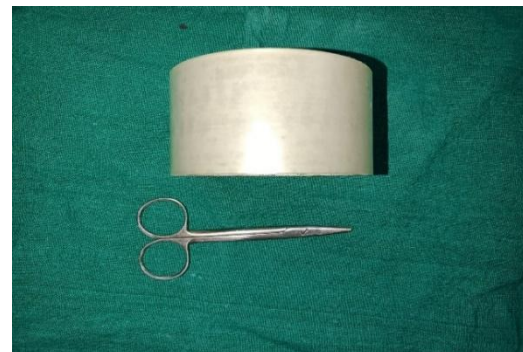

Fig 2: Cellophane strip and scissor

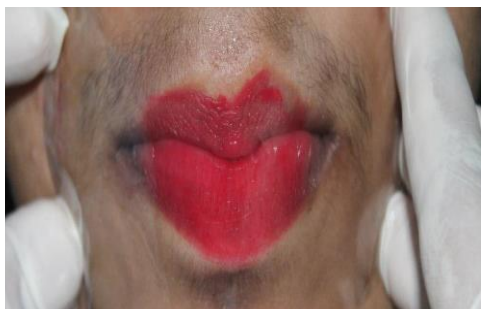

Fig 3: Cellophane strip applied on patient to obtain lip pattern



Fig 4: Lip print pattern obtained

III. Result

After interpretation of lip patterns of 240 individuals, it was found that branched lip pattern was most common with 83 individuals (34.5%) followed by reticular lip pattern and vertical lip pattern of 64 individuals (26.6%) each, intersected lip pattern in 17 individuals (7%), and undetermined lip pattern in 12 individuals (5%). (Table 1)

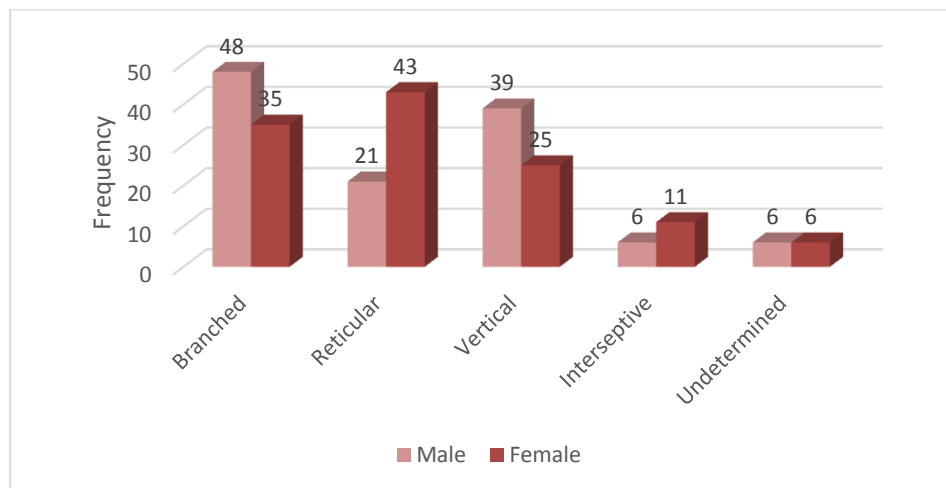
When the lip patterns were evaluated in both male and female subjects of the total selected sample, it was found that branched lip pattern was most common in males with 48 subjects (40%) followed by vertical lip pattern of 39 individuals (32.5%), reticular lip pattern of 21 individuals (17.5%) and intersected and undetermined lip pattern of 6 individuals (5%) each. (Table 1) (Graph 1).

Reticular lip pattern with 43 subjects (35.8%) was common in females which was followed by branched lip pattern of 35 individuals (29.1%), vertical lip pattern of 25 individuals (20.8%), intersected lip pattern of 11 individuals (9.1%) and undetermined lip pattern of 6 individuals (5%). (Table 1) (Graph 1).

On comparing the lip patterns in both the genders, a chi square value of 14.13 with 4 degrees of freedom and a p-value of 0.007 was obtained which was statistically significant.

Lip Patterns	Gender		Total
	Male	Female	
Branched	48(40%)	35(29.1%)	83(34.5%)
Reticular	21(17.5%)	43(35.8%)	64(26.6%)
Vertical	39(32.5%)	25(20.8%)	64(26.6%)
Intersected	6(5%)	11(9.1%)	17(7%)
Undetermined	6(5%)	6(5%)	12(5%)
Total	120	120	240

Table 1: Prevalence of lip pattern among Males and Females



Graph 1: Prevalence of lip pattern among Males and Females

IV. Discussion

The lip prints are analogous to thumb prints and is confirmed that specific lip prints are common among male and female individuals. Like thumb prints, lip prints can also be used as an identification tool as each individual's lips have a specific pattern of grooves and fissures.⁸

On lip print analysis, in the present study, none of the lip patterns were identical. The present study was undertaken to find out the variations in lip patterns among 240 individuals. It was an attempt to analyze whether the lip print holds the potential for determination of sex and identity of an individual. Suzuki et al., conducted a study and found that lip prints are dissimilar among different individuals.⁷

In the present study, examination of lip print patterns revealed that no two lip prints matched with each other. The uniqueness of lip patterns were confirmed again by this study. This may be of great help in forensic field, where lip print can be used as a tool to identify the individual.

In a study conducted by Prasad et al on Aryan- Dravidian and Mongoloid groups, Type III was found to be most prevalent lip print pattern in both females and males.⁹

In another study on North Indian population, in females Type I was the most prevalent and in males, Type III was the most prevalent lip print pattern.

Similar result was obtained in a study conducted by Kinra et al on Rajasthan population and revealed that majority of the study group belonged to Type III lip pattern. In males, the predominant type was Type III and Type I/ I' pattern was predominant in females.¹⁰

Similarly it was found that Type I pattern was the most common among males in a study conducted by Ghimire et al among Nepalese population and in the study done by Malik et al, type IV and type V patterns were most common in males.¹¹ However, the studies conducted by Arif et al., Sheetal et al and Kautilya et al among South Indian population showed that the most common patterns found in males were types IV, V, and III, respectively.⁷

Similarly, Malik and Goel also reported that Type I and Type I' were the most common patterns in females among North India population¹², while in the study done by Kautilya et al., the most common pattern found was Type I.

These results were in contrast to the present study on Malabar population where the Type II pattern was most prevalent in males and type IV pattern was prevalent in females. These variations could be attributed to the geographic disparities that may exist in lip print with respect to the most common pattern.

Similarly the present study proved that cheiloscopy hold the potential to identify sex of the individual and also in personal identification.

V. Conclusion

Lip prints, because of their uniqueness, are a valuable source of evidence for personal identification. Lip prints which are stable from the 6th week of intra uterine life are the characteristic of an individual, and no two individuals have the same lip prints. Hence there exist a need to accept lip prints as legitimate means of identifying a person of interest.

In a country like India with diverse population groups, more elaborate studies need to be conducted to understand the lip prints in different ethno- racial groups better.¹³

References

- [1]. Raghav P, Kumar N, Shingh S, Ahuja NK, Ghalaut P. Lip prints: The barcode of skeletal malocclusion. *J Forensic Dent Sci* 2013; 5: 110-7.
- [2]. Kesarwani P, Choudhary A. Establishing Role of Cheiloscopy in Person Identification and Sex Determination. *J Orofac Res.* 2017; 6(1): 4-7.
- [3]. Gupta p, Gupta N, Bannur B M, Mugadlimath A B, Sane M R, Hiremath R. A study of correlation of cheiloscopy and blood group. *Journal of Forensic Medicine science and Law* 2014;23(1): 13-18.
- [4]. Saraswati TR, Mishra G, Ranganathan K. Study of lip prints. *J Forensic Dent Sci* 2009; 1: 28-31.
- [5]. Kumar P, Dupare R, Kumar P, Gupta V. Role of lip prints as a novel tool in personal identification: An overview. *SRM J Res Dent Sci* 2013;4:21-4.
- [6]. Sivapathasundharam B, Prakash PA, Sivakumar G. Lipprints (cheiloscopy). *Indian J Dent Res* 2001; 149: 129-32.
- [7]. Sharma V, Ingle NA, Kaur N, Yadav P. Identification of sex using lip prints: A clinical study. *J Int Soc Prevent Communit Dent* 2014; 4: S173-7.
- [8]. Kulkarni N, Vasudevan SD, Shah R, Rao P, Balappanavar AY. Cheiloscopy: A new role as a marker of sagittal jaw relation. *J Forensic Dent Sci* 2012; 4: 6-12.
- [9]. Prasad P, Vanishree. A comparison of lip prints between Aryans-Dravidians and Mongols. *Indian J Dent Res* 2011; 22: 664-8.
- [10]. Kinra M, Ramalingam K, Sethuraman S, Rehman F, Lalawat G, Pandey A. Cheiloscopy for Sex Determination: A Study. *Univ Res J Dent* 2014; 4: 48-51.
- [11]. Ghimire, N, Ghimire N, Nepal P, Upadhyay S, Budhathoki S, Subba A, Kharel B. Lip print pattern: An identification tool. 2013; 11(3): 229-233.
- [12]. Malik R, Goel S. Cheiloscopy: A deterministic aid for forensic sex determination. *J indian Acad Oral Med Radiol* 2011;23(1):17-19.
- [13]. Kaul R, Shilpa PS, Padmashree S, Bhat S, Sultana N. Study of lip prints in different ethno-racial groups in India. *Indian J Dent Res* 2017; 28: 545-8.

Dr. Shaji T Varghese, et al. "Lip Prints- An Emerging Tool for Personal Identification." *IOSR Journal of Dental and Medical Sciences (IOSR-JDMS)*, 21(02), 2022, pp. 40-43.