

Efficacy of Botulinum toxin injection into lateral pterygoid muscle versus occlusal splint therapy and botulinum toxin injection for management of temporomandibular joint internal derangement (Comparative study)

Aliaa Adel Sayed¹, Mohamed Ahmed Elsholkamy², Abd elbadea Abdallah Abd elmabood³, Eman A. Elsharrawy⁴

⁽¹⁾ Post grade student at oral and maxillofacial surgery, faculty of dentistry, Suez Canal University. ⁽²⁾ Professor of Oral and Maxillofacial Surgery Faculty of Dentistry, Suez Canal University. ⁽³⁾ Associate Professor of Oral and Maxillofacial Surgery Faculty of Dentistry, Zagazig University. ⁽⁴⁾ Professor of Anesthesiology Faculty of Dentistry, Suez Canal University, Egypt.

Abstract

Introduction Temporomandibular joint (TMJ) internal derangement (ID) is one of the most common forms of temporomandibular disorder (TMD). This term used to denote a mechanical fault in the joint interfering with its smooth movement, such as an abnormal positional relationship of the articular disc to the mandibular condyle and the articular eminence. Thus, the term has been used synonymously with disc displacement. The disorders have been associated with characteristic clinical findings, including pain, joint sounds, headache, and irregular or deviated jaw functions. The aim of the present study was to investigate the effect of botulinum toxin type A injection in the lateral pterygoid muscle on temporomandibular joint clicking versus occlusal splint therapy and botulinum toxin type A. **Patients & methods:** The study enrolled forty patients divided into two equal groups. All patients were selected from the outpatient clinic, complaining of a painful TMJ click with muscle tenderness, associated with ADDR confirmed by magnetic resonance imaging. A BTX-A vial was diluted with normal saline to a concentration of 10 U per 0.1 mL for injection in a 1-ml insulin syringe. This was injected into the ipsilateral LP muscle with the guidance of an electromyogram device. Hard occlusal splint fabricated from transparent acrylic resin. **Results:** There was no statistically significant difference between pain, clicking and MMO in the two groups preoperatively. Group I showed the statistically significantly lowest mean pain scores. The mean MMO after 12 months showed statistically significantly higher mean value compared to pre-operative measurement in the two groups. Group I showed no clicking while Group II showed the highest prevalence of clicking. **Conclusion:** There was a significant increase in mouth opening from the start of treatment and till the end of the follow up period, concerning pain there is decrease in VAS values, and clicking improved postoperatively after 1 week in the first group while improved after first month in the second group, radiographic evaluation show no change in MRI.

Key words: Botulinum toxin, Lateral pterygoid muscle, Occlusal splint.

Date of Submission: 25-02-2022

Date of Acceptance: 06-03-2022

I. Introduction

Anterior disc displacement is one of the most common forms of temporomandibular disorder (TMD)^[1]. The term refers to clinical criteria classifying TMJ disorders but is generally used to denote a mechanical fault in the joint interfering with its smooth movement, such as an abnormal positional relationship of the articular disc to the mandibular condyle and the articular eminence. Thus, the term has been used synonymously with disc displacement^[2]. The disorders have been associated with characteristic clinical findings, including pain, joint sounds, headache, and irregular or deviated jaw functions, several attempts to identify the cause of disc displacement were reported^[3]. The responsibility of the lateral pterygoid muscle (LPM) is one of the widely accepted theories since its upper head inserts into the disc, The upper head of the LPM was found to be hyperactive in cases of anterior disc displacement (ADD) applying an anteriorly pulling force on the disc, Clinical diagnosis of ADD can be challenging, particularly considering the psychosocial factors that can be involved in pain disorders. Therefore, MRI of the TMJ has gained an important role in the diagnosis of ADD^[4]. MRI enables direct visualization of the disc, accurate determination of disc position and morphology and

evaluation of condylar motion in a noninvasive manner, Initial treatment should be conservative which includes soft diet, behavior modification, non-steroidal anti-inflammatory drugs, muscle relaxants, occlusal splints, and physical therapy^[5]. Surgery is indicated when noninvasive management has failed to resolve disc displacement and significant symptoms persist^[6]. The surgical procedures may include disc plication, discectomy or eminectomy, Bakke introduced a novel treatment procedure for severe clicking of the temporomandibular joint (TMJ) associated with anterior disc displacement (ADD), using injections with botulinum toxin (BTX- A) in the lateral pterygoid muscle (LP)^[7]. It has been suggested that ADD may be caused, precipitated or maintained by LP activity so; the present study evaluated the efficacy of injection of botulinum toxin (Botox) into the lateral pterygoid muscle versus occlusal splint therapy as a treatment of anterior disc displacement^[8].

II. Material And Methods

The study was a randomized clinical trial. Patients who participated in the study were selected from the patients attending the outpatient clinic of Oral and maxillofacial surgery Dentistry Department, Faculty of Dentistry, Suez Canal University, Egypt. Approval of the Research Ethical Committee of the Faculty of Dentistry, Suez Canal University (12/2015) was obtained before starting the study.

2.1. Preoperative evaluation

Past and present dental history, data were collected in form of chief complaint, included side, duration, onset, precipitating, relieving factors, and relation to other activities such as eating, yawning, or shouting^[9]. Also the presence of parafunction habits such as nail biting clinical examination including intraoral and extraoral examination

Preoperative measurements including maximal mouth opening, pain, clicking sounds, radiographic evaluation using MRI and panorama to exclude any other causes of pain^[10].

2.2. Operative procedure

Botox, presented as a powder in a transparent glass vial, was used. Each vial contains 100 U of Clostridium botulinum type A neurotoxin complex (active ingredient), 0.5 mg of human albumin and 0.9 mg of sodium chloride (inactive ingredients) Botox vial was transferred in a small icebox, and kept frozen until time of administration^[11]. The contents of the 100 IU vial were diluted in 1.0 ml sterile, preservative free 0-9% sodium chloride solution to give a solution of 10 U/0.1 ml. BOTOX disposable injection needle electrode (37 mm × 27G)^[12].

2.3. Patients grouping

Patients were divided randomly into two equal groups (n=20) as follows group I: included (20) patients suffering from anterior disc displacement^[13]. Each received BOTOX injection into lateral pterygoid muscle under EMG- guidance to localize the muscle utilizing monopolar cannulated electrode. Each lateral pterygoid muscle received 30U BOTOX. Group II Included (20) patients suffering from anterior disc displacement treated by performing occlusal splint, group III Included (20) patients with anterior disc displacement treated with occlusal splint and BOTOX injection into lateral pterygoid muscle lateral pterygoid muscle approached intraorally lateral to the maxillary tuberosity halfway between the muscle origin and insertion, with the needle just above the maxillary molar. The needle was inserted through the mucosa adjacent to the distal root of the maxillary second molar medial to the coronoid process and anterior to the condylar head of the mandible, parallel and as close as possible to the buccal alveolar bone. The injection site was located by EMG verifying that the maximum level of activity was obtained during contralateral jaw movement against resistance. After EMG confirmation was done for needle position aspiration was performed followed by slow injection rate of 30 U Botox into lateral pterygoid muscle (Fig 1).

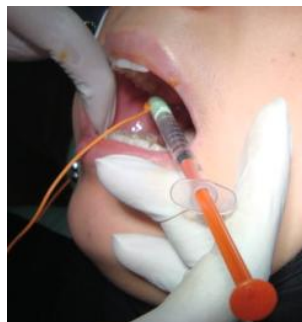

Fig. (1) Botulinum toxin type A (BTX-A) injection in the lateral pterygoid muscle.

Group II: Occlusal splint fabrication and botulinum toxin injection

Injection of botulinum toxin in the lateral pterygoid muscle as group I and fabrication of occlusal splint at same visit. The process of occlusal guard fabrication was started with occlusal examinations. Self-curing transparent acrylic resin was used to fabricate the splint in the form of a flat anterior bite plane with a thickness of 2–3 mm, which separated the posterior teeth while allowing contact between the anterior teeth. All splints were disinfected and then tried in the patient's mouth to check retention. Patients were advised to wear the splint for 1 year. The patients were instructed to use finger pressure to seat and remove the occlusal guard. All patients were examined routinely, 1 or 2 days after guard placement, to ensure proper use of the guard and to ascertain possible problems Fig (2).

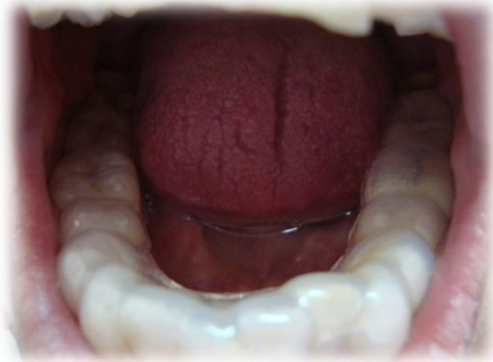

Fig (2): occlusal splint appliance.

2.4. Post-operative assessment and follow up:

All patients in group I and II were asked about the presence of any of the following symptoms: Difficulty in chewing, yawning, talking, muscle atrophy, facial asymmetry. All patients were recalled for follow up at 1 week, 1, 3, 6 months and 1 year postoperatively to assess the following: Degree of joint pain using VAS, Presence or absence of joint clicking, improvement of mouth opening using calliper, palpation of the TMJ, evaluation of joint sounds, MRI images were performed at 6 month after treatment to evaluate disk position. Statistical analysis for the results of the present study included comparison of pain VAS score values (mean), MMO values (mean) and clicking in three groups over the follow up period. The data were collected and statistically analyzed using statistic program IBM® SPSS® Statistics Version 20 for Windows

III. Results:

3.1 Pain

After 1 week, there was no statistically significant difference between Group I and Group II; both showed the statistically significantly highest mean scores. After 1 month, Group I showed the statistically significantly lowest mean pain scores. After 3 months; there was no statistically significant difference between pain scores in the two groups. After 6 months, Group II showed the statistically significantly highest mean pain scores. After 12 months; there was no statistically significant difference between pain scores in the two groups (Fig 3).

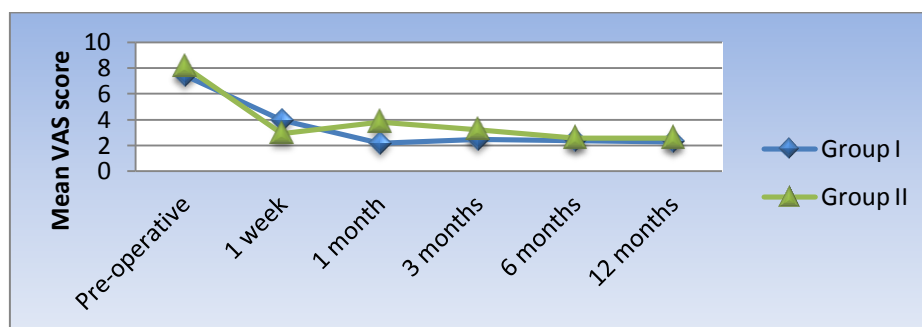


Fig (3): Line chart representing comparison between mean pain scores at different time periods in each group

3.2 Maximal mouth opening

Pre-operatively, there was no statistically significant difference between MMO in the two groups. There was no statistically significant difference between Group I and Group II; both showed the statistically

significantly lowest mean values. After 1 month, 3 as well as 6 months; there was no statistically significant difference between MMO in the two groups. After 12 months, Group I showed the statistically significantly lowest mean MMO (Fig 4).

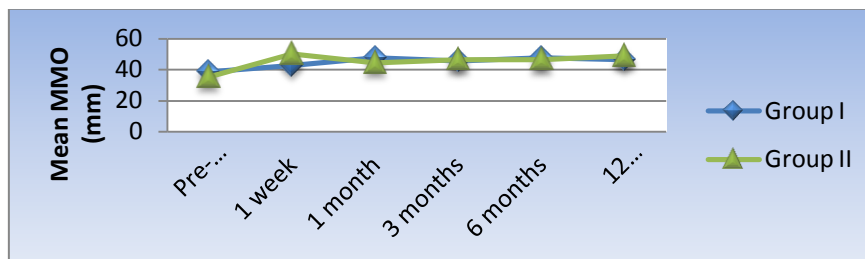


Fig (4): Line chart representing comparison between mean MMO at different time periods in each group

3.3 clicking

Pre-operatively, all cases showed clicking. After 1 week, there was a statistically significant difference between the two groups. Group I showed no clicking. Group II showed the highest prevalence of clicking. After 1 month, 3, 6 as well as 12 months; there was a statistically significant difference between the two groups. Group II showed the highest prevalence of clicking (Fig 5).

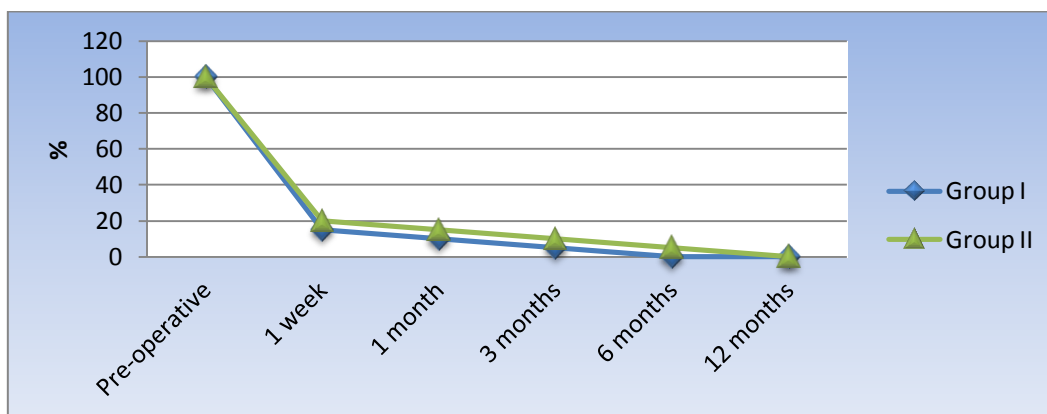


Fig (5): Line chart representing prevalence of clicking at different follow up times

IV. Discussion

Internal Derangement (ID) is one of the frequently diagnosed Temporomandibular Disorders (TMD) [1]. The main goal of ADD treatment is to alleviate pain, eliminate TMJ dysfunction and improve quality of life [2]. Botulinum toxin considered as a valuable treatment option because of its role in reduction of muscle hyperactivity especially when the muscular element is the main cause [3]. On comparing VAS subjective pain scores pretreatment and post-treatment in Botox group there was decrease in pain from the first week [4]. There was no statistically significant change in mean pain scores from 1 to 3, 3 to 6 as well as from 6 months to 12 months [5]. The mean pain scores after 12 months showed statistically significant [6]. These results was consistent with the finding of *Von Lindren et al., 2001* evaluated the effect of botulinum toxin injections on reducing the maxillofacial muscle pain associated with TMJ dysfunction., localized pain was recovered in 80% of patients and remained in about half of the patients for 3 months after injection [7].

Moreover, *Arezzo, 2002* had discussed the possible mechanisms for the effect of Botox on pain [8]. He discussed five mechanisms through which Botox might have impact on pain [9]. First, the effect on muscle pain itself via changes in the sensitivity and response patterns Second, diminishing the activity in the γ motor neurons and. Third, the alterations in autonomic function through cholinergic control of vascular and autonomic functions [10]. Fourth including neuroplastic changes in the processing of afferent somatosensory activity at multiple levels of the neuroaxis. Fifth direct non- cholinergic effects on pain afferents [11].

They observed that toxin injection eliminated the click sound in 10 joints during the first week and in one joint after a week [12]. During three to four following months, recurrence of click sound was reported in only one joint [5].

However, the use of splint improvement occurred only in 9 cases at the first week and there was slow improvement in 11 cases all over the observation period [13]. That was in agreement with *Murakami et al., 2008* who advocated the use of splint therapy as a primary treatment modality and indicated that an early start of splint treatment had a positive influence on treatment outcome for ADD [13].

The presents results showed that BTX-A injection and occlusal splint were both effective in treating TMJ pain and dysfunction as there were no significant statistical differences could be demonstrated between both techniques when compared with relation to improvement in pain, MMO and function postoperatively.

Local adverse reactions to BTX-A occur following migration of the toxin into adjacent muscles. Therefore, clinical expertise and EMG guidance was essential to define the proper insertion site of injection leading to optimal muscle targeting. The therapeutic dose of BTX-A has a wide range *Michaels et al., 2012* researched adverse events associated with therapeutic use of BTX-A in maxillofacial and cervical conditions. The present observations regarding doses of BTX-A injection into lateral pterygoid muscle were in agreement with *Bakke et al (2005)* ^[5] who stated that 30 to 35 U BOTOX was a reasonable therapeutic dose for lateral pterygoid muscle injection. However, *Jost et al., 2003* stated that lateral pterygoid muscle should receive 50 U Botox and the same doses apply for the masseter muscle. As the LPM lies deep in the vicinity of maxillary artery and pterygoid venous plexus and due to its small size, EMG was used for guidance during the injection of BTX. Differentiation between the lower and upper head of LPM during injection wasn't essential as its small size secure diffusion of solution throughout the whole muscle fiber. Regarding the complication related to BTX-A injection which developed in 1 subject in Botox group in the form of deviation of opening to the injected side and disappeared within one month. Regarding MRI evaluation, all TMJs showed persistent postoperative ADD with reduction in spite of disappearance of clinical signs and symptoms that is in accordance with *Kaneyama et al., 2007* ^[14]. study where they found ADD in MRI in 35% of asymptomatic volunteers. It is obvious that relief of symptoms was not correlated with improvement of the disk position.

V. Conclusion

BTX-A injection of LPM is a simple non-invasive treatment modality for treatment of ADD in the form of pain relive, absence of clicking and improvement of MMO with minimal side effect, Occlusal splint was less effective in treatment of clicking, BOTOX alone was more effective than both techniques together.

Disclosure and acknowledgment

The authors do not have any financial interest in the companies whose materials are included in this article

References

- [1]. Young AL. Internal derangements of the temporomandibular joint: A review of the anatomy, diagnosis, and management. J Indian Prosthodont Soc. 2015 Jan-Mar; 15(1):2-7.
- [2]. Stelzenmueller W, Umstadt H, Weber D, Goenner-Oezkan V, Kopp S, Lisson J. Evidence - The intraoral palpability of the lateral pterygoid muscle - A prospective study. Ann Anat. 2016 Jul; 206:89-95.
- [3]. Madani AS, and Mirmortazavi A. Comparison of three treatment options for painful temporomandibular joint clicking. J of Oral Science. 2011; 53:349-54.
- [4]. Al-Belasy FA, Dolwick MF. Arthrocentesis for the treatment of temporomandibular joint closed lock: a review article. Int J Oral Maxillofac Surg. 2007; 36:773-82.
- [5]. Bakke M, Møller E, Werdelin LM, Dalager T, Kitai N, Kreiborg S. Treatment of severe temporomandibular joint clicking with botulinum toxin in the lateral pterygoid muscle in two cases of anterior disc displacement. Oral Surg Oral Med Oral Pathol Oral Radiol Endod. 2005 Dec; 100(6):693-700.
- [6]. Leeuw RD. Internal Derangements of the Temporomandibular Joint. J of Oral Maxillofac Surg. 2008; 20: 159-168.
- [7]. Elfving L, Helkimo M, Magnusson T. Prevalence of different temporomandibular sounds, with emphasis on disc-displacement, in patients with temporomandibular disorders and controls. Swed Dent J 2002; 26: 9-19.
- [8]. Fernández, P; Jesús, Lamela M; Ramos, A; Fernández-Canteli, A; Tanaka, E. The region-dependent dynamic properties of porcine temporomandibular joint disc under unconfined compression. J Biomech 2013; 46: 845-848.
- [9]. Stanković, S; Vljaković, S; Bošković, M; Radenković, G; Antić, V; Jevremović, D. Morphological and biomechanical features of the temporomandibular joint disc: an overview of recent findings. Arch Oral Biol 2013; 58:1475-1482.
- [10]. Singh, M; Detamore, MS. Biomechanical properties of the mandibular condylar cartilage and their relevance to the TMJ disc. J Biomech 2009; 42:405-417.
- [11]. Tanaka, E; Hirose, M; Koolstra, JH; van Eijden, TM; Iwabuchi, Y; Fujita, R; et al.. Modeling of the effect of friction in the temporomandibular joint on displacement of its disc during prolonged clenching. J Oral Maxillofac Surg 2008; 66:462-468.
- [12]. Hirose M, Tanaka E, Tanaka M, Fujita R, Kuroda Y, Yamano E. Three-dimensional finite-element model of the human temporomandibular joint disc during prolonged clenching. Eur J Oral Sci 2006; 114: 441-448.
- [13]. Luder HU. Factors affecting degeneration in human temporomandibular joints as assessed histologically. Eur J Oral Sci 2002; 110:106-13.
- [14]. Kaneyama K, Segami N, Shin-Ichi T, Fujimura K, Sato J, Nagao T. Anchored disc phenomenon with a normally positioned disc in the temporomandibular joint: characteristics and behavior. Br J. Oral Maxillofac Surg 2007; 45(4):279-83.
- [15]. Kurita H, Ohtsuka A, Kobayashi H, Kurashina K. A study of the relationship between the position of the condylar head and displacement of the temporomandibular joint disk. Dentomaxillofac Radiol. 2001; 30:162-5.

Aliaa Adel Sayed, et. al. "Efficacy of Botulinum toxin injection into lateral pterygoid muscle versus occlusal splint therapy and botulinum toxin injection for management of temporomandibular joint internal derangement (Comparative study)." *IOSR Journal of Dental and Medical Sciences (IOSR-JDMS)*, 21(03), 2022, pp. 25-29.