

A Rare Case Of Carcinosarcoma - Endometrium : A Case Report

Dr.V.S. Ajay chandrasekar¹, Dr.C. Gunasekar², Dr.R. Vimal chander³

1(Associate Professor, Department of Surgical oncology, Saveetha medical college and hospital, Thandalam)

2(Senior Resident, Department of General Surgery, Saveetha medical college and hospital, Thandalam)

3(Professor, Department of Pathology, Saveetha medical college and hospital, Thandalam)

Abstract

Carcino sarcoma of uterus is an rare neoplasm of the uterus which will contain both epithelial and mesenchymal elements. It accounts for less than 5% of the uterine malignancies and is more common in the 7th decade of life. Despite its rare nature, when present it is more aggressive with poor prognosis in comparison with other uterine malignancies. we hereby, present a case of uterine carcino sarcoma in a 67year old post-menopausal women who presented with abdominal pain and postmenopausal bleeding. Considering the aggressive nature of this malignancy, early detection and intervention is mandatory for improving the patients survival rates.

Key words - carcino sarcoma, epithelial, mesenchymal, abdominal pain, post menopausal bleeding.

Date of Submission: 04-04-2022

Date of Acceptance: 19-04-2022

I. Introduction

Carcinosarcoma of uterus previously known as Malignant Mixed Mullerian Tumor(MMMT) is an rare neoplasm of the uterus which will contain both epithelial and mesenchymal elements. It accounts for less than 5% of the uterine malignancies and is more common in the 7th decade of life^{1,2}. Despite its rare nature, when present it is more aggressive with poor prognosis in comparison with other uterine malignancies. Around 30-40% of patients will have extra uterine involvement at the time of presentation³. Surgical resection of the tumor with/without adjuvant chemotherapy is the mainstay of treatment. Adjuvant chemotherapy was found to be more effective compared to radiotherapy in some studies^{3,4}. In this study, we present a rare case of carcinosarcoma diagnosed in the histopathological examination of an 67year old post menopausal women.

II. Case Report:

67year old postmenopausal women came with complaints of abdominal pain (on and off) for the past 2months and with history of post menopausal bleeding 2episodes before 3months. she had no other significant clinical history. patient was initially evaluated in gynaecology department, where patient underwent endometrial curettage with colposcopy & biopsy. Histopathology was reported as high grade endometrial carcinoma. Hence, patient was referred to surgical oncology department for further management. Patients imaging showed enlarged uterus with thickened endometrium with growth filling the entire endometrial cavity[figure 1,2]. After obtaining informed written consent and anaesthetic fitness, (Type-II Radical Hysterectomy)Total abdominal hysterectomy with bilateral salpingo-oophorectomy with bilateral pelvic lymphnode dissection was done. specimen was sent to pathology department for histopathological examination. The size of the uterus with cervix measured 12.5×7×5cms with the endometrial tumor almost filling the entire uterine cavity, with size measuring 7.5×3.5×3.5cms. There was more than 50% involvement of the uterine myometrium with growth extending to the lower uterine segment(non-myoinvasive). Cervix, bilateral uterine tubes, ovaries, right pelvic nodes, omentum and peritoneal fluid was free of malignant deposit. The microscopic examination demonstrated poorly differentiated endometrial adenocarcinoma of the uterus with extensive spindle cell proliferation suggesting a sarcomatous component with myometrial invasion greater than 50% [picture 1 - 6]. There were sarcomatous elements with marked nuclear pleomorphism and mitotic activity; focal areas showing chondroid differentiation; lymphatic invasion/tumor emboli in lymphatic vessels. There was focal perineural invasion and extensive lymphovascular invasion with left pelvic lymph node micro metastasis(0.2 to 2mm diameter). Hence, the final pathology report was high grade carcino-sarcoma involving more than half of the myometrium, with left pelvic lymphnode micro metastasis; International Federation of Gynecology and Obstetrics (FIGO) Stage IB (pT1b pN1mi). Post operative period was uneventful and the patient was referred to medical oncology for adjuvant chemotherapy.

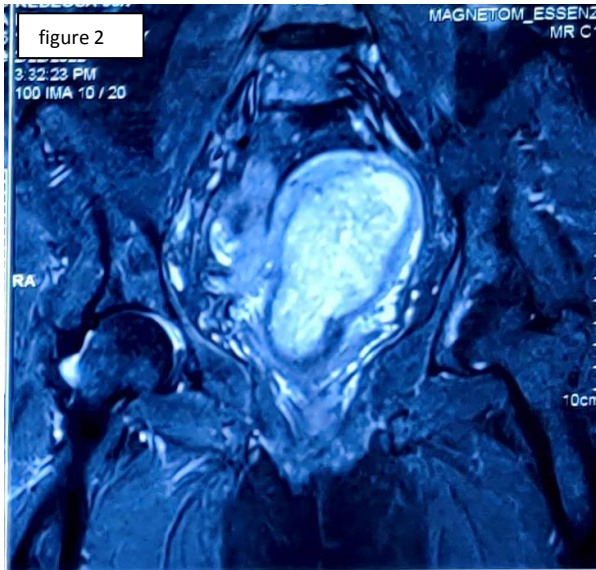
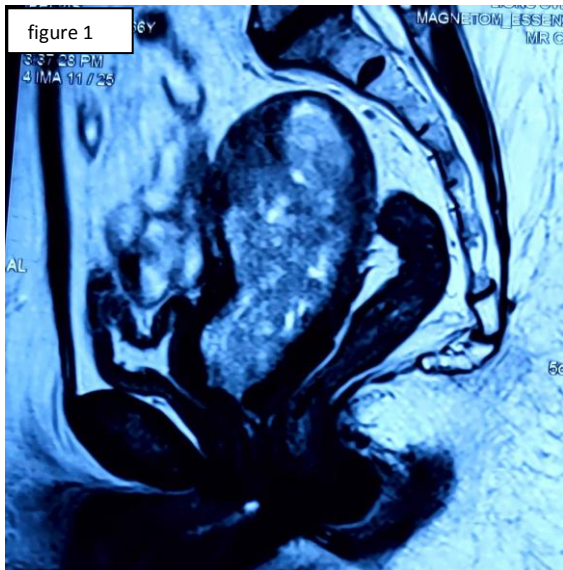
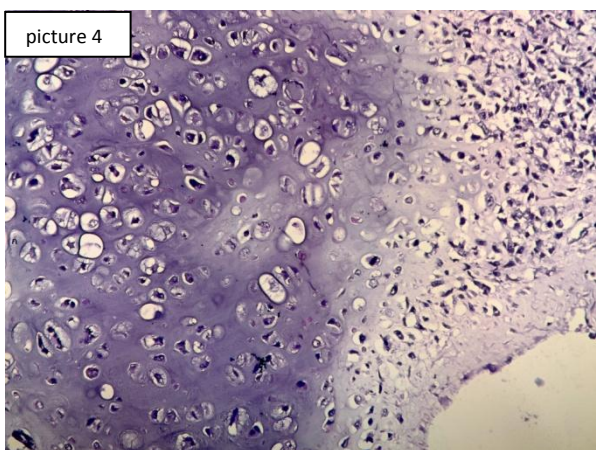
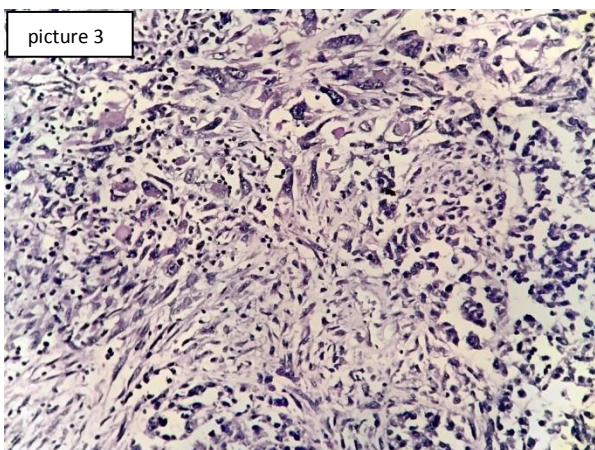
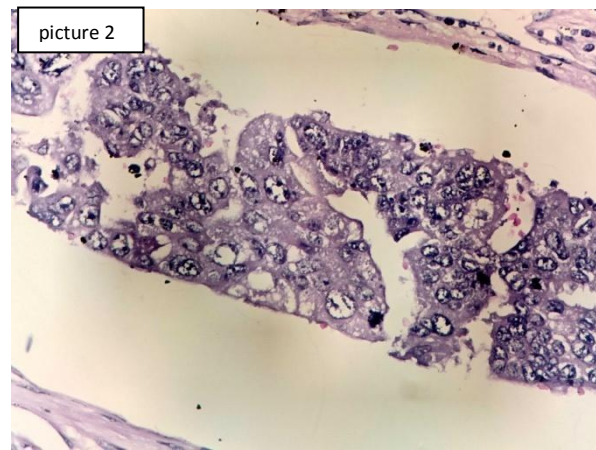
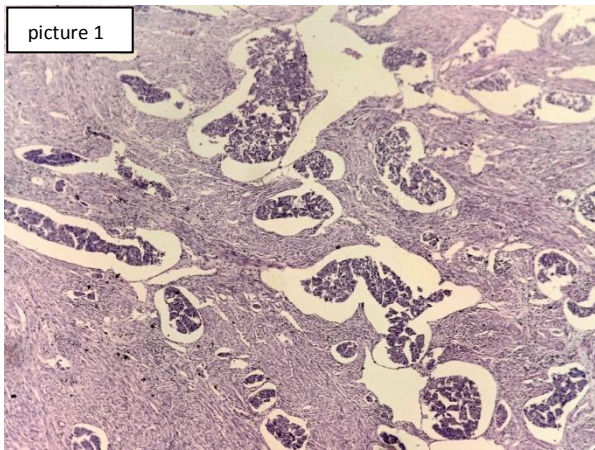
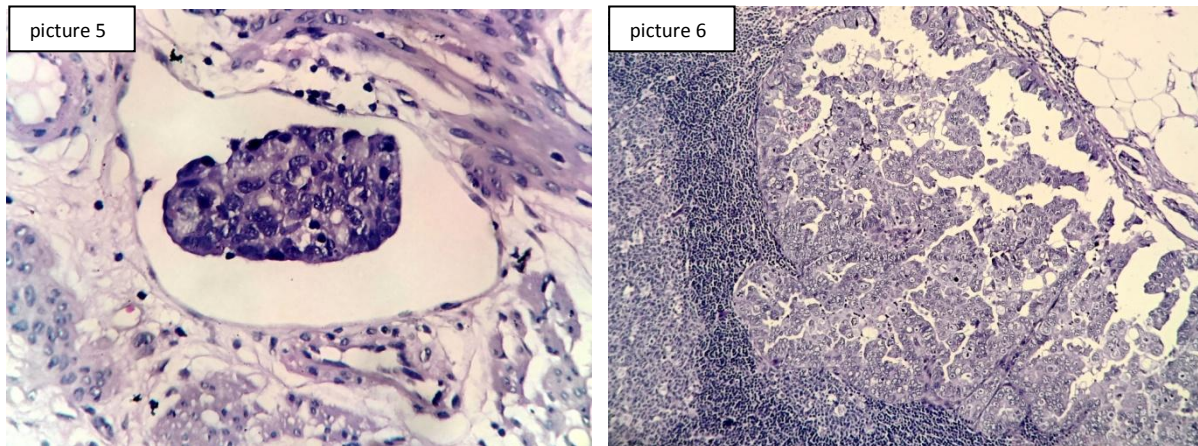


Figure 1 & 2 - MRI with contrast showing sagittal and coronal view of uterine mass





Picture 1 - Epithelial carcinomatous islands surrounded by sarcomatous elements (H&E x100)

Picture 2 - Carcinomatous elements (H&E x400)

Picture 3 - Sarcomatous elements with marked nuclear pleomorphism and mitotic activity (H&E x400)

Picture 4 - Sarcomatous elements in focal areas showing chondroid differentiation (H&E x400)

Picture 5 - Areas showing lymphatic invasion/tumor emboli in a lymphatic vessel (H&E x400)

Picture 6 - Metastatic tumor deposits in lymph node (H&E x100)

III. Discussion

Carcinosarcomas are characterized by an aggressive clinical course and an extremely poor prognosis. It has been previously reported that 70-90% of tumor-related deaths occurred within 18 months after diagnosis^{5,6}. However, a recent study reported that the prognosis of uterine carcinosarcomas had improved, with an overall median survival of 39 months⁷.

Carcinosarcomas are classified into two histological subtypes based on their sarcomatous component, namely homologous or heterologous. The homologous type tend to be fibrosarcomas, endometrial stromal tumors or leiomyosarcomas; while heterologous type consist of a sarcomatous component made up of tissues that are non-native to the uterus, and include rhabdomyosarcomas, chondrosarcomas, osteosarcomas and liposarcomas. In both types, the carcinomatous component is mainly composed of endometrioid, serous or clear-cell type adenocarcinoma. Homologous and heterologous carcinosarcomas arise with approximately equal frequencies⁸.

Clinical presentation is often the triad of abnormal uterine bleeding, pain and a rapid uterine enlargement. In physical examination, the tumor presents as a relatively large polypoid mass which could protrude from the cervix, posing the risk of uterus inversion⁹. Uterine carcinosarcomas have high rates of lymphatic spread, peritoneal seeding and pulmonary metastasis¹⁰. Approximately 30–40% of cases have extrauterine involvement at the time of first presentation, extrauterine nodal spread being widely prevalent and over 10% of patients initially present with distant metastasis. These contribute to the poor prognosis of this rare disease⁹.

Risk factors include obesity, nulliparity and the use of exogenous estrogen, tamoxifen and exposure to pelvic radiation are specifically linked to increased risk of developing carcinosarcoma¹¹. Hyperinsulinemia is associated with two-fold increased cancer risk; and obesity leads to hyperinsulinemia¹². Proinflammatory cytokines related to obesity are associated with an increased risk of endometrial carcinomas¹³. Carcinosarcoma arises from a single malignant epithelial clone and is considered to be a high-risk, undifferentiated (metaplastic) variant of endometrial adenocarcinoma. Recent studies showed that carcinomatous and sarcomatous elements are likely derived from a common precursor having mutations that are typical of carcinomas^{14,15}. Vaginal bleeding is the most common presenting sign for carcinosarcoma of uterus. Carcinosarcoma is usually hyperechoic compared to the myometrium on ultrasound^{16,17}.

The primary management of uterine carcinosarcoma is surgery for both staging and initial treatment. For patients with stage 4 disease, surgery is of palliative intent. The choice of adjuvant therapy protocol varies based on the stage of the disease¹⁸. Although the rarity of this neoplasm has precluded larger trials for evaluation for standardized treatment guidelines, Carboplatin and paclitaxel is usually the recommended initial regimen¹⁹. Some studies suggest combining vaginal brachytherapy (VBT) and chemotherapy. A survival advantage has been demonstrated in women with stage III endometrial cancer treated with chemoradiation (followed by systemic chemotherapy) compared to pelvic radiation therapy alone²⁰. Prognosis is usually poor. The stage is the most important prognostic factor. Negative prognostic factors include elevated CA 125, black race, lymphovascular space invasion, myometrial invasion and the presence of gross residual disease^{21,22}.

References

- [1]. Denschlag D, Ulrich UA: Uterine carcinosarcomas - diagnosis and management . *Oncol Res Treat.* 2018, 41:675-679.
- [2]. Bansal N, Herzog TJ, Seshan VE, Schiff PB, Burke WM, Cohen CJ, Wright J: Uterine carcinosarcomas and grade 3 endometrioid cancers. Evidence for distinct tumor behavior. *Obstet Gynecol.* 2008, 112:64-70.
- [3]. P. Ravishankar, D. A. Smith, S. Avril, E. Kikano, and N. H. Ramaiya, "Uterine carcinosarcoma: a primer for radiologists," *Abdominal Radiology*, vol. 44, no.8, 2019; 2874–2885.
- [4]. Cantrell LA, Blank SV, Duska LR: Uterine carcinosarcoma: a review of the literature . *Gynecol Oncol.* 2015, 137:581-588.
- [5]. Barwick KW and LiVolsi VA: Malignant mixed müllerian tumors of the uterus. A clinicopathologic assessment of 34 cases. *Am J Surg Pathol* 3: 1979; 125-135.
- [6]. Norris HJ, Roth E and Taylor HB: Mesenchymal tumors of the uterus. II. A clinical and pathologic study of 31 mixed mesodermal tumors. *Obstet Gynecol* 28: 1966; 57-63.
- [7]. Rauh-Hain JA, Shoni M, Schorge JO, Goodman A, Horowitz NS and del Carmen MG: Prognostic determinants in patients with uterine and ovarian carcinosarcoma. *J Reprod Med* 58: 2013; 297-304.
- [8]. Spaziani E, Picchio M, Petrozza V, Briganti M, Ceci F, Di Filippo A, Sardella B, De Angelis F, Della Rocca C and Stagnitti F: Carcinosarcoma of the uterus: A case report and review of the literature. *Eur J Gynaecol Oncol* 29: 531-534, 2008.
- [9]. P. Ravishankar, D. A. Smith, S. Avril, E. Kikano, and N. H. Ramaiya, "Uterine carcinosarcoma: a primer for radiologists," *Abdominal Radiology*, vol. 44, no. 8, 2019; 2874–2885.
- [10]. T. S. Pradhan, E. E. Stevens, M. Ablavsky, G. Salame, Y.-C. Lee, and O. Abulafia, "FIGO staging for carcinosarcoma: can the revised staging system predict overall survival?," *Gynecologic Oncology*, vol. 123, no. 2, 2011; 221–224.
- [11]. Cantrell LA, Blank SV, Duska LR: Uterine carcinosarcoma: a review of the literature . *Gynecol Oncol.* 2015, 137:581-588.
- [12]. Tsujimoto T, Kajio H, Sugiyama T: Association between hyperinsulinemia and increased risk of cancer death in nonobese and obese people: a population-based observational study. *Int J Cancer.* 2017, 141:102-111.
- [13]. Onstad MA, Schmandt RE, Lu KH: Addressing the role of obesity in endometrial cancer risk, prevention, and treatment. *J Clin Oncol.* 2016, 34:4225-4230.
- [14]. Brooks SE, Zhan M, Cote T, Baquet CR: Surveillance, epidemiology, and end results analysis of 2677 cases of uterine sarcoma 1989-1999. *Gynecol Oncol.* 2004, 93:204-208.
- [15]. Siming Zhao, Stefania Bellone, Salvatore Lopez, et al.: Mutational landscape of uterine and ovarian carcinosarcomas implicates histone genes in epithelial-mesenchymal transition. *Proc Natl Acad Sci U S A.* 2016, 25:12238-12243.
- [16]. Pacaut C, Bourmaud A, Rivoirard R, et al.: Uterine and ovary carcinosarcomas: outcome, prognosis factors, and adjuvant therapy. *Am J Clin Oncol.* 2015, 38:272-277.
- [17]. Teo SY, Babagbemi KT, Peters HE, Mortelet KJ: Primary malignant mixed Mullerian tumor of the uterus: findings on sonography, CT, and gadolinium-enhanced MRI. *AJR Am J Roentgenol.* 2008, 191:278-283.
- [18]. Callister M, Ramondetta LM, Jhingran A, Burke TW, Eifel PJ: Malignant mixed Müllerian tumors of the uterus: analysis of patterns of failure, prognostic factors, and treatment outcome. *Int J Radiat Oncol Biol Phys.* 2004, 58:786-796.
- [19]. Powell MA, Filiaci VL, Rose PG, et al.: Phase II evaluation of paclitaxel and carboplatin in the treatment of carcinosarcoma of the uterus: a Gynecologic Oncology Group study. *J Clin Oncol.* 2010, 28:2727-2731.
- [20]. de Boer SM, Powell ME, Mileshkin L, et al.: Adjuvant chemoradiotherapy versus radiotherapy alone for women with high-risk endometrial cancer (PORTEC-3): final results of an international, open-label, multicentre, randomised, phase 3 trial. *Lancet Oncol.* 2018, 19:295-309.
- [21]. Denschlag D, Ulrich UA: Uterine carcinosarcomas - diagnosis and management . *Oncol Res Treat.* 2018, 41:675-679.
- [22]. Huang GS, Chiu LG, Gebb JS, Gunter MJ, Sukumvanich P, Goldberg GL, Einstein MH: Serum CA125 predicts extrauterine disease and survival in uterine carcinosarcoma. *Gynecol Oncol.* 2007, 107:513-517.

Dr.V.S. Ajay chandrasekar, et. al. "A Rare Case Of Carcinosarcoma - Endometrium : A Case Report." *IOSR Journal of Dental and Medical Sciences (IOSR-JDMS)*, 21(04), 2022, pp. 10-13