

# Brucellar Spondylodiscitis – A Case Series on Presentation, Management, and Outcomes

Jo-Yi Cheong<sup>1</sup>

<sup>1</sup>(Department of Orthopedics, Sungai Buloh Hospital, Malaysia)

---

## Abstract:

*Brucellosis is a zoonosis that is endemic in certain parts of the world. The spine is the most common osteoarticular localisation of brucellosis infections. We report of two uncommon cases of spondylodiscitis secondary to brucella that were treated pharmacologically with intravenous Gentamicin for a week followed by a course of oral Doxycycline and Rifampicin. Disease resolution was evidenced by resolution of pain, normalisation of infective markers, and radiologic improvement. A high degree of suspicion in the diagnosis of brucellar spondylodiscitis is essential to reduce the delay to treatment. Thus, it should be considered in the differential diagnosis of chronic back pain especially in regions where brucellosis is endemic.*

**Key Words:** *Brucellosis, spondylodiscitis, spine brucellosis*

---

Date of Submission: 06-05-2022

Date of Acceptance: 21-05-2022

---

## I. Introduction

Brucellosis is a zoonotic disease, caused by *Brucella* sp., which is a gram-negative coccobacillus. Transmission to humans is via contact with infected animals or through consumption of animal products. Musculoskeletal involvement is the most common manifestation of the disease, with the spine being the most commonly affected area with a rate of up to 54%.<sup>1,2</sup> Its differential diagnoses include the more common tuberculosis, pyogenic infection, or degenerative disease. Diagnostic criteria for Brucellosis include (i) positive cultures, (ii) histopathology, (iii) serology, (iv) compatible clinical features, (v) exposure to animals or animal products, (vi) radiological evidence of infective spondylodiscitis. Early diagnosis and treatment of the disease with appropriate antibiotics is important for curative intention to prevent complications and avoid surgery. This case series highlights two patients who were treated with IV Gentamicin for a week followed by a combined treatment of oral Doxycycline and Rifampicin for five to eight months. Both of them achieved complete recovery from the disease with resolution of pain, normalised septic markers (erythrocyte sedimentation rate (ESR), C-reactive protein (CRP), and white cell count (WCC)).

## II. Case Series

### Case 1:

The first patient is a 66-year-old farmer with a history of hypertension and dyslipidemia. He was referred to our Orthopedic specialty service from a district hospital. This gentleman presented with lower back pain for the past two months radiating down the bilateral lower limbs. This was worsened by activity, and was associated with fever and appetite loss. Spine examination revealed lower lumbar tenderness. Neurological examination was unremarkable. He had a raised ESR of 50, while WCC and CRP were not elevated. His lumbosacral x-rays showed anterior osteophytes and reduced disc spaces of the L4/L5 level. Lumbosacral MRI showed L4/L5 spondylodiscitis with prevertebral, subligamentous, psoas, and epidural collection impinging on the bilateral L4 exiting and L5 traversing nerve roots. Tissue biopsy for histopathology and cultures were consistent with Brucellosis. Moreover, blood samples were positive for *Brucella* antibodies with titers of >1:5120. Hence, a diagnosis of Brucellar spondylodiscitis was made. His condition was co-managed with the Infectious Diseases team who started him on antimicrobial treatment with IV Gentamicin 240mg for a week followed by Oral Doxycycline 100mg BD and Oral Rifampicin 900mg OD for eight months. His back pain improved, and serial infective markers taken during clinic visits had normalized. A repeated MRI of the lumbosacral region 14 months later showed resolution of spondylodiscitis, paravertebral and epidural collection.

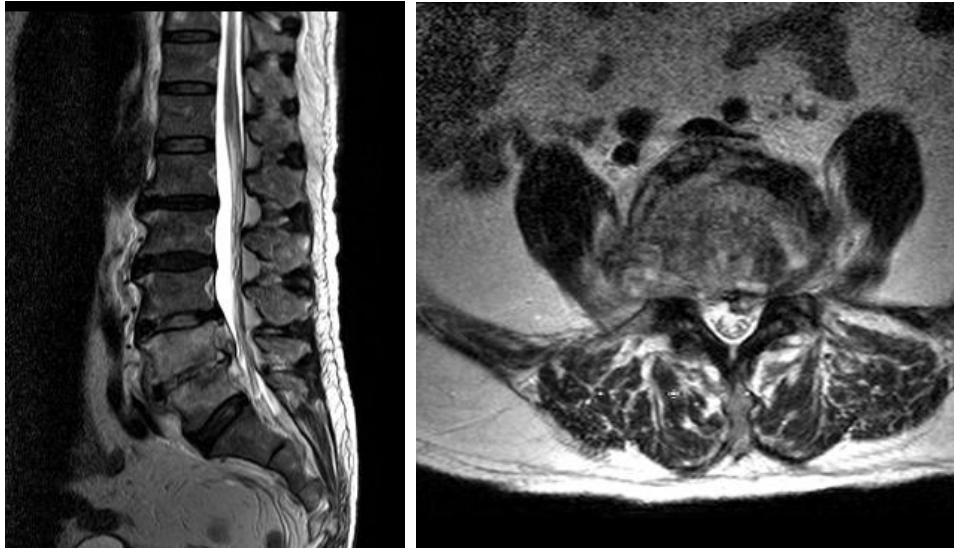


Figure 1: Lumbo-sacral MRI taken prior to commencing treatment showing infective spondylodiscitis features.

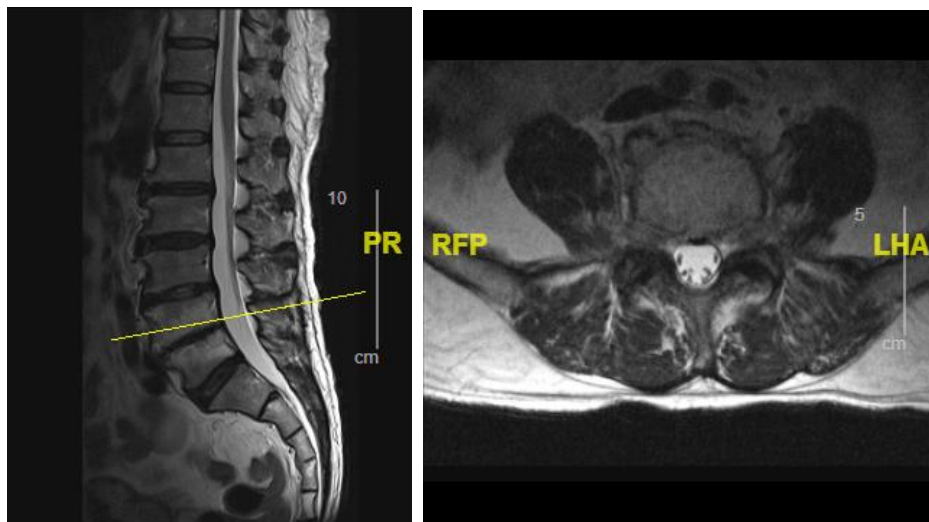


Figure 2: Repeated lumbo-sacral MRI after completion of treatment showing radiological improvement.

### Case 2:

This is a 48-year-old housewife with underlying diabetes mellitus and dyslipidemia who lives in the estate. She complained of chronic back pain with left radiculopathy that worsened after a fall, associated with fever and loss of appetite. Palpation revealed tenderness at the thoracolumbar junction. There was no neurological deficit, with intact power and sensation bilaterally. Her infective markers were raised, with a WCC of 14 and ESR of 97. Her x-ray showed anterior endplate erosion of T12 vertebra with reduced T12/L1 disc space. An MRI of the spine was conducted which showed T12/L1 spondylodiscitis, paravertebral and epidural collections with bilateral psoas, right quadratus lumborum and right gluteus muscle collections. Tuberculosis cultures were negative, whilst tissue and blood cultures for Brucellosis were positive. She was promptly commenced on IV Gentamicin for 1 week followed by Oral Doxycycline 100mg BD and Oral Rifampicin 900mg OD for five months. A repeat MRI of the spine eight months later showed resolved infection with no new collection. Her symptoms had also improved and her septic markers had normalized.

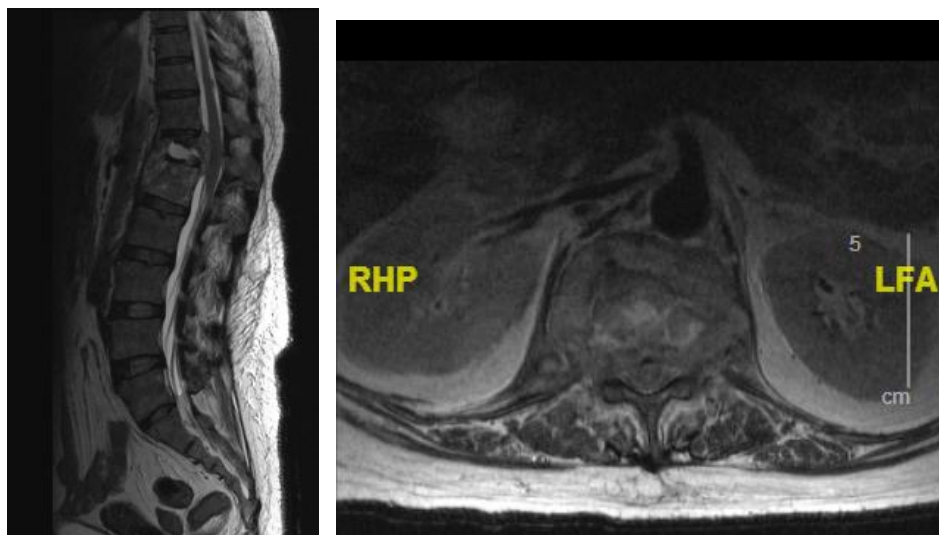


Figure 3: Lumbo-sacral MRI showing T12/L1 spondylodiscitis with spread into the epidural space, paravertebral space, and psoas, quadratus lumborum, and gluteus muscles.

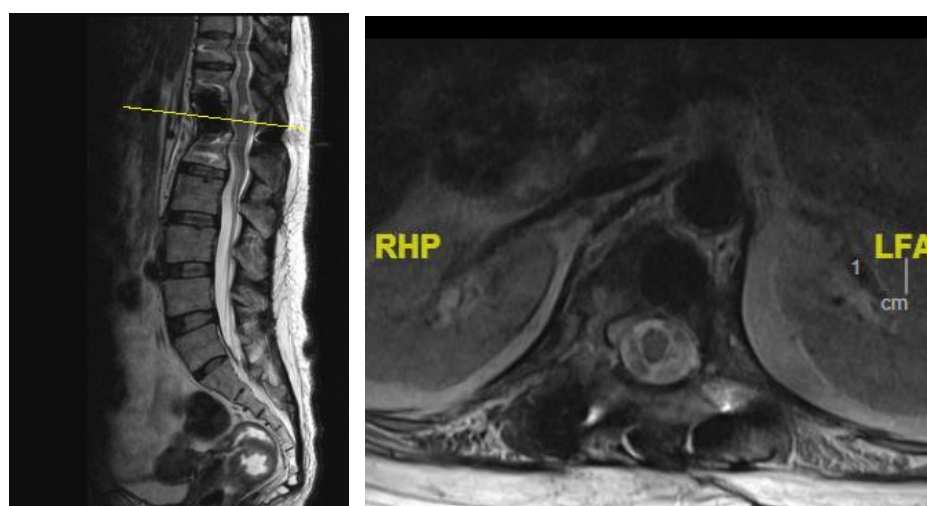


Figure 4: Post-treatment MRI lumbo-sacral demonstrating resolved spine infection and paravertebral collection.

### III. Discussion

Both patients had a strong clinical history to suggest exposure to *Brucella* sp., further evidenced by radiographic imaging of spondylodiscitis. Similar manifestations of spinal involvement on radiology investigations are observed in pyogenic, tuberculosis and brucellosis. Furthermore, these diseases are endemic in Malaysia, making prompt diagnosis essential in order to confirm the pathology.

Antibiotics are the mainstay of brucellosis treatment, with combination therapy recommended to prevent high relapse rates associated with monotherapy.<sup>3,4</sup> A multidisciplinary team approach with Infectious Diseases clinicians who are well-versed with antimicrobial therapy is recommended. Complicated spinal brucellosis extending to neighboring tissue and paravertebral and epidural spaces may require a longer duration of antibiotic treatment for adequate disease eradication.<sup>3,5</sup>

Our patients benefited from early diagnostic confirmation which led to prompt and appropriate antibiotic treatment. Even though their disease was considered complicated, which led to prolonged treatment for more than three months, both of them responded well to non-operative management. Surgical intervention should only be considered as the last resort in cases of worsening back pain, persistently high septic markers, and progressive neurological deficit despite adequate antimicrobial therapy.<sup>6</sup>

### IV. Conclusion

In conclusion, early diagnosis of brucellosis is important for prompt treatment. Brucellar spondylodiscitis responds well to antibiotic treatment, hence adequate therapy should be commenced immediately upon diagnosis. A complete clinical history exploring risk factors for brucellosis infections, clinical examination, blood workup including septic markers, cultures and serology, as well as an MRI spine is essential. Moreover,

tissue biopsy for histopathological evaluation and cultures are absolutely pertinent in achieving an appropriate diagnosis.<sup>7,8</sup> A multidisciplinary approach towards brucellar spondylodiscitis with early commencement of appropriate antibiotic treatment is the way to go to ensure complete recovery.

### References

- [1]. Smailnejad Gangi SM, Hasanjani Roushan MR, Janmohammadi N, Mehraeen R, Soleimani Amiri MJ, Khalilian E. Outcomes of treatment in 50 cases with spinal brucellosis in Babol, Northern Iran. *J Infect Dev Ctries*. 2012;**6**:654–659.
- [2]. Lim KB, Kwak YG, Kim DY, Kim YS, Kim JA. Back pain secondary to Brucella spondylitis in the lumbar region. *Ann Rehabil Med*. 2012;**36**:282–286.
- [3]. Ulu-Kilic A, Karakas A, Erdem H, Turker T, Inal AS, Ak O, Turan H, Kazak E, Inan A, Duygu F, Demiraslan H, Kader C, Sener A, Dayan S, Deveci O, Tekin R, Saltoglu N, Aydın M, Horasan ES, Gul HC, Ceylan B, Kadanalı A, Karabay O, Karagoz G, Kayabas U, Turhan V, Engin D, Gulsun S, Elaldı N, Alabay S. Update on treatment options for spinal brucellosis. *Clin Microbiol Infect*. 2014 Feb;**20**(2):O75-82.
- [4]. Tekaya R, Haj Tayeb M, El Amri N, et al. THU0257 Brucella Spondylodiscitis: A Study of Nineteen Cases. *Annals of the Rheumatic Diseases* 2015;**74**:290.
- [5]. Andrabi SA, Hamid S, Ajjaz S. Brucellosis masquerading as spondylodiscitis with multiple intervertebral disc prolapse. *J Glob Infect Dis*. 2012;**4**(3):184-185.
- [6]. Pappas G, Akritidis N, Bosilkovski M, Tsianos E. Brucellosis. *N Engl J Med*. 2005 Jun 2;**352**(22):2325-36.
- [7]. Aydin G, Tosun A, Keles I, Ayaşlıoglu E, Tosun O, Orkun S. Brucellar spondylodiscitis: a case report. *Int J Clin Pract*. 2006 Nov;**60**(11):1502-5.
- [8]. Esmailnejad-Ganji SM, Esmailnejad-Ganji SMR. Osteoarticular manifestations of human brucellosis: A review. *World J Orthop*. 2019 Feb 18;**10**(2):54-62.