

Atypical vogt koyanagi harada(clinical image)

Dr Erradi/Dr Hjira/ Pr L.Serghini/Pr Berraho

Abstract

This is a 30-year-old patient with an antecedent 0 who presents with bilateral uveo-meningitis with occlusive vasculitis right eye

Keys words: Uveo meningitis,vogt koyanagi harada

Date of Submission: 15-05-2022

Date of Acceptance: 30-05-2022

I. Case Report

A 32-year-old Caucasian woman developed bilateral IU, primarily diagnosed as "idiopathic" since a detailed etiologic work-up was not indicative of underlying disease. two months later, he presented with poliosis and vitiligo. Lumbar puncture revealed cerebrospinal fluid pleocytosis. Optical coherence tomography showed bilateral subclinical macular edema (ME). The visual acuity was still 20/20 in both eyes. Clinical, laboratory and radiological results did not fit into any known syndrome.

RE: papillary hyperhemia, surtt nasal, macula of bad reflection ,vx diffuse retinal folds

LE: Papillar oedema 1,depigmented aspect of pole post; retinal folds

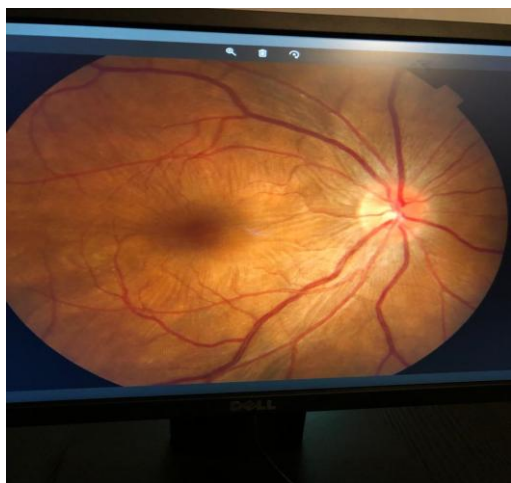

Figure 1. RIGHT EYE

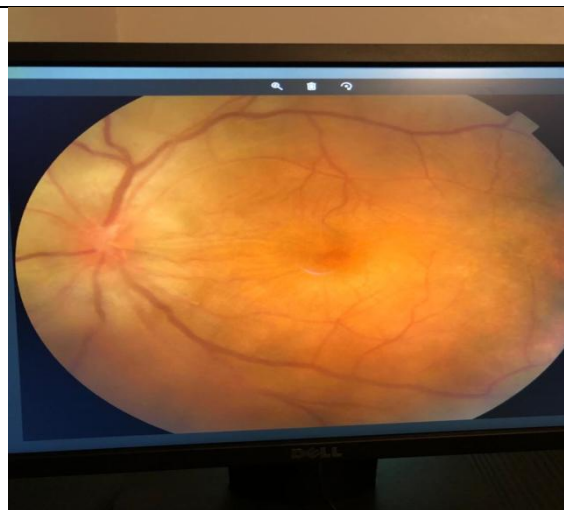


FIGURE 2 ; left eye

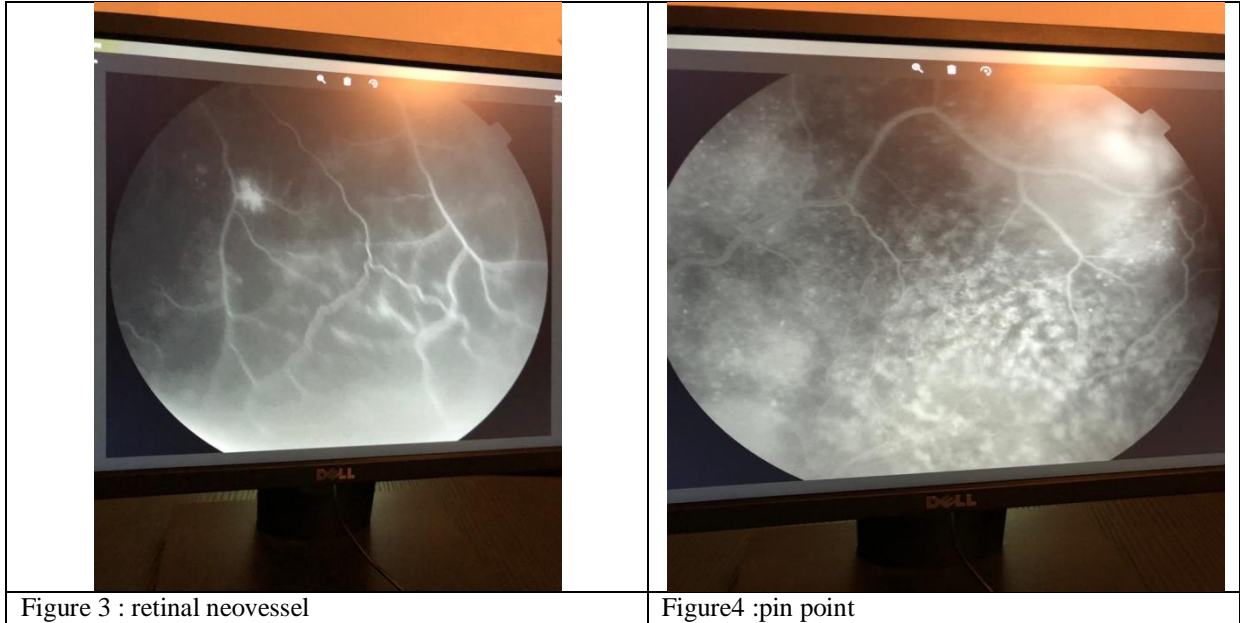


Figure 3 : retinal neovessel

Figure4 :pin point

References :

- [1]. Read RW, Holland GN, Rao NA, Tabbara KF, Ohno S, Arellanes-Garcia L, et al. Revised diagnostic criteria for Vogt-Koyanagi-Harada disease: report of an international committee on nomenclature. *Am J Ophthalmol.* 2001; 131(5): 47-52. **PubMed** | **Google Scholar**
- [2]. Toutou V, Escande C , Bodaghi B,Cassoux N. Prise en charge diagnostique et thérapeutique du syndrome de Vogt-Koyanagi-Harada. *J Fr Ophtalmol.* 2005; 28(1): 9-16. **PubMed** | **Google Scholar**
- [3]. Forster DJ, Cano MR, Green RL, Rao NA. Echographic features of the Vogt-Koyanagi-Harada syndrome. *Arch Ophthalmol.* 1990; 108(10): 1421-6. **PubMed** | **Google Scholar**
- [4]. Read RW. Vogt-Koyanagi-Harada disease. *Ophthalmol Clin North Am.* 2002; 15(5): 333-41. **PubMed** | **Google Scholar**

Dr Erradi, et. al. "Atypical vogt koyanagi harada(clinical image)". *IOSR Journal of Dental and Medical Sciences (IOSR-JDMS)*, 21(05), 2022, pp. 10-11.