

Efficacy of Two Perpendicular Mini-Plate for the Treatment of Mandibular Angle Fracture

Md. Mamunur Rashid¹, K S M Bayazid², Md. Abdur Razzak³,
Tarin Rahman⁴, Nurul Amin⁵

¹Assistant Professor, Department of Oral & Maxillofacial Surgery, Sapporo Dental College & Hospital, Dhaka, Bangladesh

²Classified Specialist in Oral & Maxillofacial Surgery, Military Dental Center, Chattogram, Bangladesh

³Assistant Professor, Department of ENT & Head-Neck Surgery, City Medical College, Gazipur, Bangladesh

⁴Associate Professor, Department of Oral & Maxillofacial Surgery, Dhaka Dental College, Bangladesh

⁵ Professor, Department of Oral & Maxillofacial Surgery, Sapporo Dental College & Hospital, Dhaka, Bangladesh

Corresponding Author: Md. Mamunur Rashid¹

Abstract

Background: Mandibular angle fractures are treated surgically by either rigid or semi-rigid fixation. Treatment of angle fractures has more complications because of the complex biomechanics of the angle region, including a thin cross-sectional area, abrupt change in the curvature, attachment of masticatory muscles, and the presence of third molar teeth. It requires three-dimensional stability. The two perpendicular mini-plate techniques can three-dimensionally control the fracture lines. There are various treatment options for angle fracture but no well-accepted protocol has yet been developed. This study was designed with the aim of evaluating the efficiency of two perpendicular non-compression mini plates as an effective fixation method for mandibular angle fracture.

Objective: To evaluate the efficacy of two perpendicular non-compression miniplates as a treatment modality for mandibular angle fracture.

Method: This Quasi-experimental study was done on 30 patients with unfavorable mandibular angle fractures. Two perpendicular non-compression miniplate were used for fixation. The efficacy of two perpendicular miniplate was evaluated in terms of the state of occlusion, chewing ability, and postoperative complication. The study was conducted in the Oral and Maxillofacial surgery department, Dhaka Dental College & Hospital in the period between 1st September 2018 to 30th August 2019.

Results: In this study most of the patients (87%) were male and the mean age was 24.5 years. In the fracture line, a third molar was present in 53% of cases. At the 4th post-operative weeks occlusion, chewing ability improved to almost normal, which was statistically significant. Infection occurred in two cases and facial nerve injury and hardware failure were not observed in any case.

Conclusion: The two perpendicular miniplate systems had adequate stability after fixation of mandibular angle fracture. The two perpendicular miniplate systems had several advantages such as three-dimensionally control the fracture line, rapid recovery of normal occlusion, and chewing ability. Thus two perpendicular miniplate can be used for fixation of mandibular angle fracture. The system is a reliable and effective treatment modality for mandibular angle fracture management.

Key-words: Perpendicular, Mini-Plate, Mandible, Angle Fracture, Treatment

Date of Submission: 02-06-2022

Date of Acceptance: 15-06-2022

I. Introduction

The present era of fast-moving, result-oriented life has made a definite impact on the common man. Traffic accidents – road, or rail, violence- communal or otherwise, sports accidents etc, have had an alarming increase in the past few decades and are a case of grave concern. Maxillofacial trauma is very common in all these unforeseen events and the unique position of the mandible on the face makes it vulnerable. It is therefore, one of the most commonly fractured facial bone. Mandible is the only mobile bone of the facial skeleton which plays an important role in mastication, speech and deglutition. Fracture in the mandible causes severe loss of function and disfigurement^[1]. A road traffic accident is the leading cause of mandibular fracture in third world countries, while interpersonal violence is the leading cause in developed countries^[2,3]. The incidence of mandible fracture according to anatomic distribution were body- 30.2%,symphysis-25.3%,and angle-18.5% in

Bangladesh whereas in India was parasymphysis-23.25%, angle-17.44% and body-12.74%^[4] and in Pakistan was parasymphysis-27.4%, angle-23.3% and body-22.2%^[5]. The most common causes of mandibular fracture in Bangladesh was RTA-58.4%, fall-13.6%, work related-12.8% whereas in India was RTA-48.83%, assault-26.74%, sports-13.95%^[4] and in Pakistan was RTA-42.6%, fall-28%, firearm injures-16.6% and assault-4.6%^[5]. The angle of the mandible fractures is common for some reasons that include: 1) the presence of third molars 2) a thinner cross-sectional area than the tooth-bearing region and 3) biomechanically the angle can be considered a "lever" area^[6]. Maxilla and mandible are the keystones to the bony architecture of the face, and the presence of teeth in maxillofacial region makes the management of maxillofacial trauma unique compared to long bones. The history of the treatment of facial bone fractures parallels the development of modern oral and maxillofacial surgery. If put on the timeline the management of trauma has evolved greatly over the years from supportive bandages, splints, circummandibular wiring, and extra oral pin to rigid fixation and more lately semi-rigid^[7].

The ideal method of mandible fracture osteosynthesis should be an accurate anatomical reduction, restoration of pre-morbid occlusion, restoration of aesthetic, phonetics, and masticatory function, atraumatic operative technique, and early and safe mobilization and rehabilitation of the injured part and the patient^[7,8]. The way in which mandible angle fractures are treated has undergone a gradual evaluation, ranging from Closed reduction i.e. -Maxillo-mandibular fixation (MMF) to Open reduction and internal fixation (ORIF) using transosseous wiring, lag screw and plate fixation^[9]. The close reduction technique is non-compliant for many patients due to prolonged restricted mouth opening, difficulty to maintain nutrition and oral hygiene, communication problem, social embarrassment, in case of children chances of ankylosis etc.^[10]. Worldwide the conventional non-compression miniplate or Champy's miniplate is most commonly used for osteosynthesis in mandible fracture as it allows early recovery of jaw function, easier maintenance of oral hygiene and better nutrition, reduced the chance of postoperative morbidity in polytraumatized and immobilized patients, decrease hospital stay time and overall patient's comfort and satisfaction^[11,12]. Although it is simple, quicker and still in practice but has got some limitations i.e.: -Fracture reduced by the conventional system is vulnerable to torsional and bending movement along the long axis of mandible, particularly when loaded close to the fracture site, which may lead to loss of functional lock and result in reduced primary stability. Furthermore, an inaccurate adaptation of plate causes displacement of mobile bony fragments when screws are tightened and thereby need for further intermaxillary fixation^[7]. There are various treatment modalities for angle fracture and the treatment ranges from closed reduction, to open reduction with non-rigid fixation by means of transosseous wires, or small positional bone plates, to AO reconstruction plates, and dynamic compression plates, mini/dynamic compression plates, lag screws and non-compression plates. Despite a great deal of research, treatment modalities and philosophies are conflicting, and no well-accepted protocol has been developed yet^[13].

Two main procedures are basically used. Internal fixation uses a miniplate placed on the external oblique ridge intraorally with or without another miniplate through an intraoral and extraoral approach. Rigid internal fixation of mandibular angle fractures by miniplate osteosynthesis is accomplished by a four- or six-hole miniplate ventral to the oblique line of the buccal cortex of the mandible and numerous authors have documented low complication rates with monocortical miniplate fixation^[7]. However, questions concerning the stability provided by miniplate fixation of mandibular angle fractures have become a point of contention among surgeons, based on recent clinical and experimental studies. In an experimental setting, described inferior distraction of the lower mandibular margin caused by the loading forces model^[14] demonstrated that a second miniplate at the inferior border provides stable fixation under functional loading^[15] found an unacceptably high (28%) rate of complications of treatment using two non-compression miniplates, while reported the lowest complication rate of any fixation method technique using a two-miniplate technique where one miniplate is contoured to the external oblique line. A second miniplate was placed at the superior buccal cortical area of the mandible. Treatment of angle fractures is full of complications because of the complex biomechanics of the angle region, including a thin cross-sectional area, abrupt change in the curvature, attachment of masticatory muscles, and the presence of third molar teeth^[16]. It requires three-dimensional stability. The 3D plating system is based on quadrangle geometry and a newer option to achieve it^[17] whereas in a perpendicular plating system three-dimensional stability can be achieved by a conventional miniplate screw system used in a different direction^[18]. The two perpendicular mini-plate techniques can three-dimensionally control the fracture lines. This technique has a low cost, low-stress shielding, and low plate profile^[18]. So the aim of the current study is to evaluate the efficacy of two perpendicular miniplate for the treatment of angle fracture that will provide sufficient information for better treatment planning and the management of mandibular angle fracture.

II. Objective

General Objective: To evaluate the efficacy of two perpendicular non-compression miniplates as a treatment modality for mandibular angle fracture

Specific objectives:

To assess post-operative occlusion.

To assess post-operative chewing ability.

To assess post-operative complications.

III. Materials And Methods:

Type of study: Quasi experimental study.

Place of study: Department of Oral and Maxillofacial Surgery, Dhaka Dental College & Hospital, Mirpur-14, Dhaka.

Period of study: 1st September 2018 to 30th August 2019.

Study population: Patients who attend to the Department of Oral and Maxillofacial Surgery, Dhaka Dental College & Hospital as a diagnosed case of mandibular angle fracture clinically and radiologically were included in this study.

Sampling method: Purposive sampling.

Sample Size: In our study 30 patients with mandibular angle fractures were taken on the basis of some inclusion criteria.

Study Design: The study was a quasi-experimental study of patients attending the Dept. of Oral and Maxillofacial surgery in Dhaka Dental college hospital with mandibular angle fractures from September 2018 to August 2019. All the parameters for functional outcome were evaluated separately for each patient and put in tabulated form for detailed qualitative analysis. All the patients were followed up for at least 4 months and on each follow-up occlusion, chewing ability, and all other post-operative parameters were evaluated.

Selection of the cases: Patients who were attended in the Department of Oral and Maxillofacial Surgery, Dhaka Dental College & Hospital, Dhaka with mandibular angle fracture undergoing open reduction and internal fixation (ORIF) were selected. The selections were based on certain inclusion and exclusion criteria.

Inclusion criteria: Age group between 18 to 60 years, Patients with unfavorable angle fracture, and those who will be fulfilled and consented to the study and agreed to return for follow-up care to be enrolled for the study.

Exclusion criteria: Patient with condylar, subcondylar and ramus fracture of mandible, Patient associated with midfacial fracture and polytrauma, Patients having a systemic illness (Diabetes Mellitus, Vascular diseases, Bleeding disorders, Severe anemia, MI, Renal failure, Liver failure, etc.) and patients having pathology like osteoporosis, osteopetrosis, Hamartoma etc.

Ethical consideration: The protocol was approved by the "Research Review Committee" of the Department of Oral and Maxillofacial Surgery of Dhaka Dental College and Hospital. Finally, ethical clearance was taken from the "Ethical Committee" of Dhaka Dental College. Patients, included in the study, were explained about the procedure and outcome of the research in detail and written consent was obtained.

Data collection technique: A standardized structured data collection was used to collect necessary information about the subject group. The data sheet included all of the variables regarding the study.

Data analysis: Data were screened and cleaned for any discrepancy. After cleaning data were entered into the template of SPSS @20 software. Demographic characteristics were expressed as frequency using a tabular and graphical pattern. Assessment of Occlusion, chewing ability, and post-surgical complications was reported. Level of significance was tested using chi-square test for categorical variables and analysis of variants. After cleaning the data were recorded on a predesigned data collection sheet and analyzed by SPSS statistics (version 20) software. After fulfilling the collection procedure of data, all data were entered into the template of SPSS@20 tool. Then the data were analyzed as per the requirement of the study.

IV. Result

The study was conducted in the Dept. of Oral and Maxillofacial Surgery, Dhaka Dental College Hospital and was diagnosed case of mandibular angle fracture clinically and radiographically. A total of 30 patients were included in this study. The results of the study were shown below in different tables and figures.

Figure 1: Distribution of age (n=30)

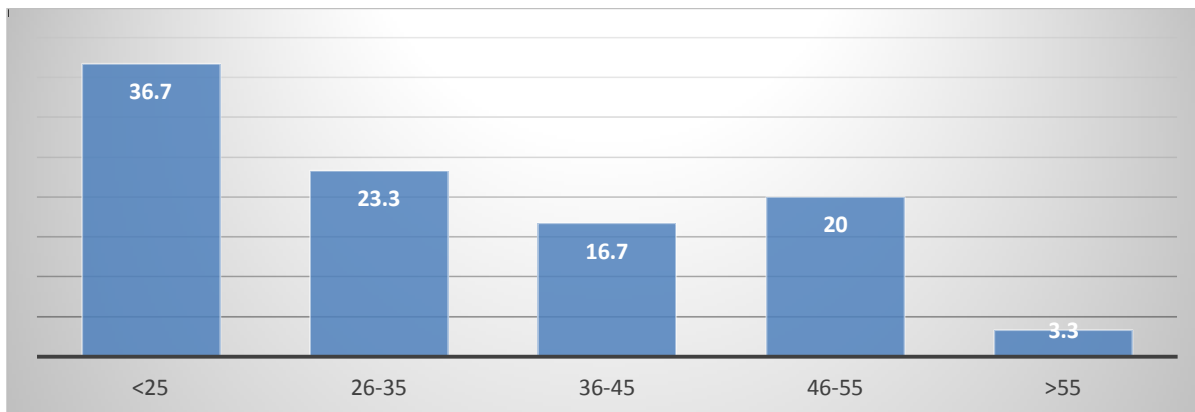
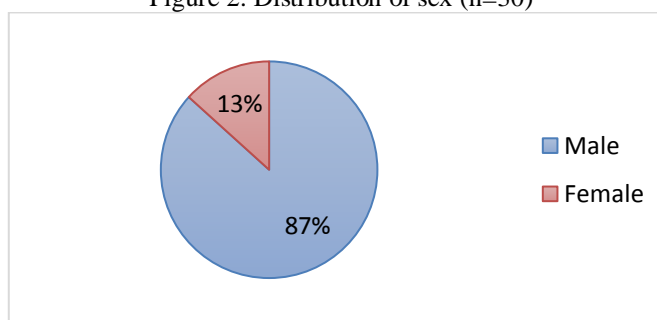


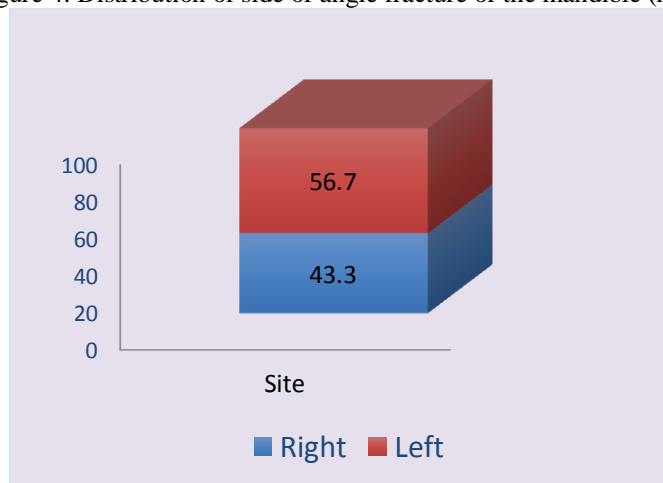
Figure1: The distribution of age group among sample. The age ranged from 18 years to 60 years, Mean age was 24.5 years. The most affected groups (37%) were <25 years of age and, whereas the least affected group (4%) were >55 years of age.

Figure 2: Distribution of sex (n=30)



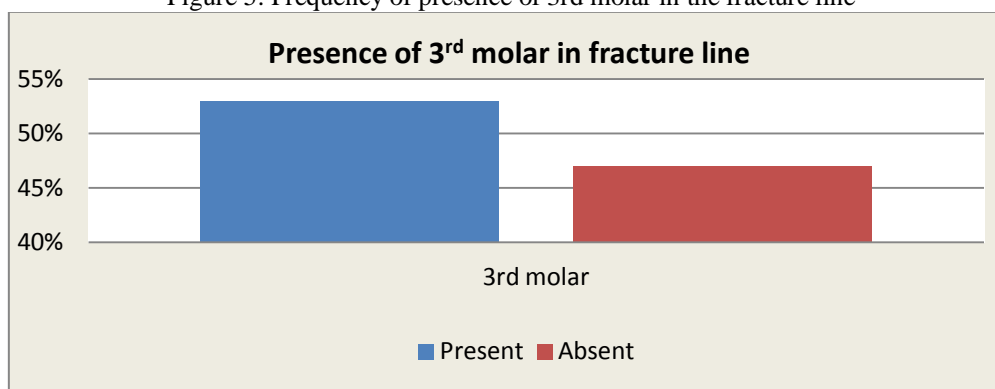
The sex distribution in our study sample among 30 patients, the number of male patient=26 (87%) and Female=04 (13%).

Figure 4: Distribution of side of angle fracture of the mandible (n=30)



The distribution of site of angle fracture among 30 patients, 57% were on the left side and 43% were on the right side.

Figure 5: Frequency of presence of 3rd molar in the fracture line



Distribution of presence of 3rd molar in fracture line among 30 patients, 53% were present and 47% were absent on fracture line.

Table 1: Cross-tabulation of occlusion at pre-operative and post-operative (after 4th week) evaluated by surgeon

	Occlusion		Total	p-Value	Result
	Disturbance	No disturbance			
Pre-operative	30 (100%)	0	30	<0.0001	Significant
Post-operative (after 4 th week)	02 (7%)	28 (93%)	30		

Table 2: Cross-tabulation of occlusion at pre-operative and post-operative (after 4th week) evaluated by the patient

	Occlusion		Total	p-Value	Result
	Disturbance	No disturbance			
Pre-operative	30 (100%)	0	30	<0.0001	Significant
Post-operative (after 4 th week)	03 (10%)	27 (90%)	30		

Table 3: Evaluation of occlusion by the patient (n=30)

	Occlusion		
	4 th week after surgery	12 th week after surgery	16 th week after surgery
Same as before injury	27 (90%)	30 (100%)	30 (100%)
Adequate on both the sides but not the same as before injury	03 (10%)	00 (0%)	00 (0%)

Table 4: Cross-tabulation of chewing ability at pre-operative and post-operative (after 4th week) evaluated by the patient

	Chewing ability		Total	p-Value	Result
	On soft diet	On a normal diet but chew only one side			
Pre-operative	30 (100%)	0	30	<0.0001	Significant
Post-operative (after 4 th week)	09 (30%)	21 (70%)	30		

Table 5: Evaluation of chewing ability (n=30)

	Chewing ability			
	1 st week after surgery	4 th week after surgery	12 th week after surgery	16 th week after surgery
On soft diet	30 (100%)	09 (30%)	00 (00%)	00 (00%)
On a normal diet, but can chew only on one side	00 (00%)	21 (70%)	00 (00%)	00 (00%)
On normal diet, on both side	00 (00%)	00 (00%)	30 (100%)	30 (100%)

Table 6: Evaluation of postoperative complications (n=30)

	Infection				Nerve injury	Hardware failure
	1 st week after surgery	4 th week after surgery	12 th week after surgery	16 th week after surgery		
Present	06%	0%	0%	0%	0%	0%
Absent	94%	100%	100%	100%	100%	100%

V. Discussion

Fractures of the mandibular angle account for 23-42% of all mandibular fractures. Due to the biomechanics of the mandible, these fractures are associated with the highest incidence of postsurgical complications. Recent three-dimensional *in vitro* experiments suggest two-miniplate fixation be used in order to avoid opening of the inferior fracture gap, which was observed and suspected to contribute to the occurrence of complications^[14]. The main idea of these authors was to reduce the separation of the fracture line and lateral displacement of the lower mandibular border-frequently observed on postoperative radiographs in our clinical routine-- by establishing a second line of osteosynthesis in order to protect against rotational forces. However, the actual results of clinical series using two-miniplate fixation techniques are controversial. While^[15] found an unacceptably high rate (28%) of complications of treatment using two non-compression miniplates, reported excellent results and the lowest complication rates (3.1%) using a second six-hole miniplate placed at the superior buccal cortical area of the mandible. Fracture of the mandibular angle is common and is difficult to treat, as there is no universal standard protocol to treat angle fractures. Various types of plates have been designed, claiming to be superior to other types in terms of stability and complications. In osteosynthesis technique, there has been a metamorphosis and change in trends from rigid fixation in 1968 to semi-rigid fixation in 1973. In the angle region of mandible where horizontal and vertical rami of mandible meet and powerful elevators muscles are attached to the ramus, strong distractive forces are created; therefore to counteract these forces, a strong device is required. The two perpendicular mini- plates are placed in a different directions, which may increase the resistance to the torsional forces along the axis of the plate^[19].

In this study, 30 patients with mandibular angle fractures were operated and studied for their pre and postoperative outcome. The mean age of the patients was 24.5 years (range, 18 to 60 years), there were 26 male patients (87%) and 4 were female (13%), and fracture on the left side 57% and right side 43%. Of the patients, 2 (6%) had minor occlusal disturbances that have been resolved with small occlusal adjustments. Regarding complications, infection developed after surgery in 2 patients and other complications such as nerve injury and plate removal were not found in this study. The mean age of patients was 24.5 years, and the age range of the study population was from 18 to 60 years. But mostly affected (37%) age group was <25 years and the lowest affected group (3.3%) was >55 years. Various studies done on angle fracture had subjects in similar mean age^[15,20,21,22,23,24,25,26,27]. The possible explanation for the higher frequency of fractures in the age group 21-30 years is that the second and third decades of human life are the most active decades in life and thus people in these decades are vulnerable to trauma. These age groups show more activity in sports, fights, violent activities, industry, and high-speed transportation. The sex distribution in our study was shown male (87%) and female (13%) ratio (26:4). The relatively high number of male to female is due to the fact that male are engaged more in outdoor activities while female are confined to indoor activities. The fracture mandible is predominantly common in the male population in this part of the world. This finding is consistency with the results of previous studies conducted all over the world^[28,29,30]. A tooth in the line of fracture was identified in (53%) of angle fractures; the remaining angle fractures (47%) did not have a tooth in the line of fracture.

The occlusion was evaluated by the surgeon and patient postoperatively at regular intervals at 1st week, 4th week, 12th week, and 16th weeks intervals. The present study had shown, the state of occlusion in 4th postoperative week, Out of 30, 28 patients had normal pre-morbid occlusion and 2 patients (6%) had postoperative mild occlusal discrepancy which was treated successfully by selective occlusal grinding. This mild occlusal derangement could be the result of associated contralateral parasymphiseal fracture with severe displacement and the delay in treatment as it operated on the 12th-day post-injury. In the 4th post-operative week, statistically significant difference was found between pre-operative and post-operative occlusion. In 12th week and 16th week's interval follow-up, No occlusal disharmony was detected in surgeons and self-evaluation. Self-evaluation of chewing was performed by the patient at 1st week, 4th week, 12th week and 16th postoperative week. In the 4th post-operative weeks, a statistically significant difference was found between pre-operative and post-operative chewing. In this study on 12th and 16th week, all patients were able to masticate their regular normal meals. The possible causes of chewing improvement is no movement of fracture fragment after fixation and three dimensional stability of fracture fragment which helps in proper bone healing. The study conducted by Bhatnagar et al has shown in 8 weeks follow up they found all patients were able to masticate their regular normal meals other than hard objects.

In this study postoperative complication also evaluate at regular interval in 1st week, 4th week, 12 weeks and 16 weeks. The incidence of infection in the form of swelling, pus discharge and wound dehiscence. Out of 30, 28 patients had no experience of postoperative infection, only 2 cases (6%) was present mild infection. The particular cases, patients were kept on antibiotics for 7-10 days and continuous follow up in the OPD for normal saline irrigations which lead to satisfactory healing. Here also our results fell within the range of other studies on two-miniplate fixation of mandibular angle fracture that showed infection rates ranging from 2.9% to 28%^[31,32]. Variation in the rate of postoperative infection could be related to the status of a 3rd molar in the fracture line, the time delay between trauma and the operation, improper adaptation of the miniplate, and inadequate stability of fracture fragment. In this study there was no patient who had paresthesia or anesthesia of

lower lip due to injury to the marginal mandibular branch of facial nerve, the possible reason is due to proper anatomical knowledge and competence of the surgeon and this result is consistent with the study of [16,18]. In this study, there is no hardware failure the possible reason is due to three-dimensional stability of fracture fragments and this result is consistent with the study of [18] where they also found no screw loosening. But some other study has shown hardware failure in their study [16].

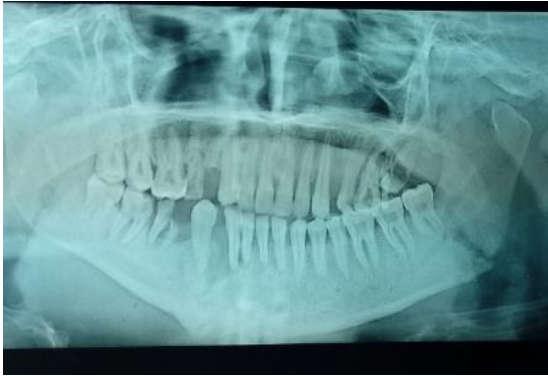

Fig 1: Titanium miniplate with screw



Fig 2: Preoperative Radiograph of angle fracture

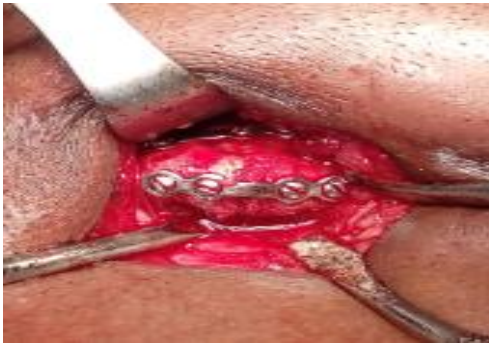

Fig 3: Two perpendicular miniplate fixation

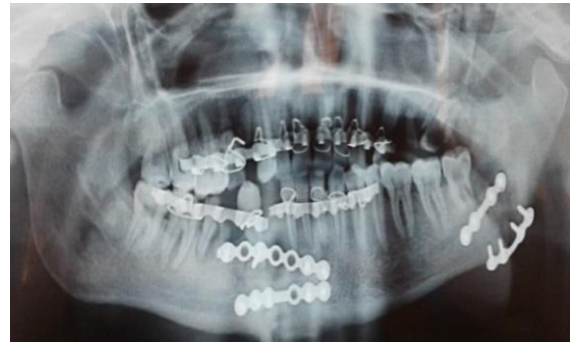

Fig 4: Postoperative Radiograph

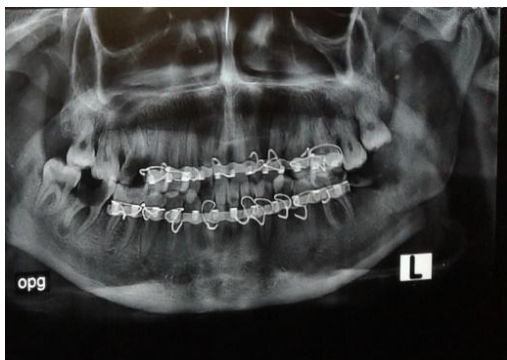


Fig 5: Preoperative Radiograph of angle fracture

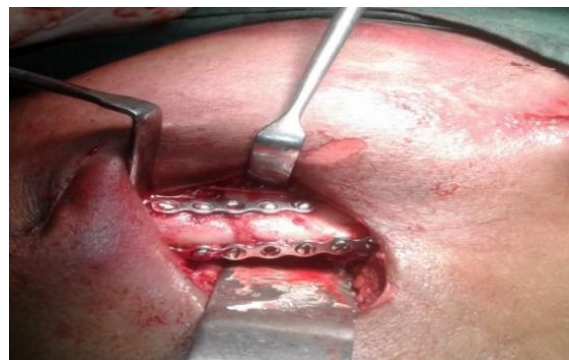

Fig 6: Two perpendicular miniplate fixation

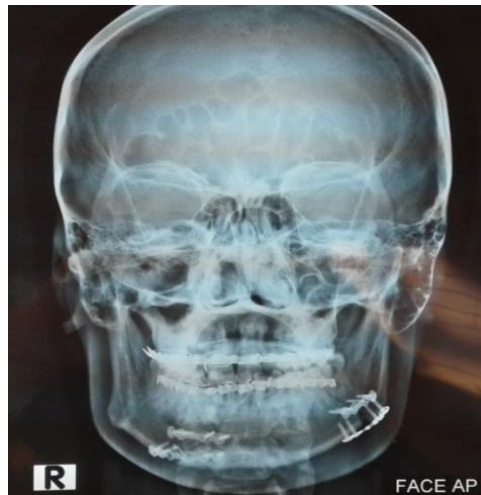


Fig 7: Postoperative Radiograph

Limitation of the study: The study was conducted among the patients of Dhaka Dental College Hospital for one year period. The study sample was small and short-time follow-up. The operations were performed by several surgeons and there was no control group.

VI. Conclusions

The two plating systems had adequate stability after fixation of mandibular angle fracture. Overall postoperative complications were less in our study. The two perpendicular miniplate systems had several advantages. The two perpendicular mini-plate techniques can three-dimensionally control the fracture line, rapid recovery of normal occlusion and chewing ability. Thus two perpendicular manipulate can be used in mandibular angle fracture management. The system is a reliable and effective treatment modality for mandibular angle fracture management. A more extensive clinical study is recommended including different treatment centers in Bangladesh with a larger sample and long-term follow-up for better evaluation of treatment outcomes and postoperative complications.

References:

- [1]. SUBHASHRAJ, K., NANDAKUMAR, N. & RAVINDRAN, C.2007. Review ofmaxillofacial injuries in Chennai, India: A study of 2748 cases. *British Journal of Oral Maxillofacial.Surgery*, 45(8), 637-9.
- [2]. SAKR, K., FARAG, I. A. & ZEITOUN I. M., 2006. Mandibular fractures treated at the University Hospital, Alexandria, Egypt.*British journal of Oral Maxillofacial Surgery*, 44(2), 107-11.
- [3]. SHAYYAB, M.; ALSOLEIHAT, F.; RYALAT, S. & KHRAISAT, A. 2012. Trends in the pattern of facial fractures in different countries of the world. *International. Journal of .Morphol.*, 30(2), 745-756.
- [4]. MALIK SUNITA, SINGHGURDARSHAN,2004. Incidence Aetiology and pattern of mandible fractures in sonapat,Haryana. *International journal of medical dentistry*,4, 51-59.
- [5]. KHAN AHMED,ABDUSSALAM,Khitabumar 2009. Pattern of mandibular fractures. *Pakistan oral and dental journal*,29(2),221-224.
- [6]. E. ELLIS III,1999. Treatment methods for fractures of mandible angle. *International Journal of Oral Maxillofacial Surgery*. 28,243-252.
- [7]. CHAMPY, M., LODDE, J. P., SCHMI, T. T., JAEGER, J.H., MUSTER, D., 1978. Mandibular osteosynthesis by miniplate screwed plates via a buccal approach. *Journal of oral and maxillofacial surgery*, 6, 14-21.
- [8]. WINSTANLEY, R.P., 1984.The management of fractures of mandible.*British journal of Oral and Maxillofacial surgery*, 22(3), 170-7.
- [9]. MUKERJI, R., MUKERJI, G., McGURK, M., 2006, Mandibular fracture: Historical perspective. *British Journal of Oral and Maxillofacial surgery*, 44(3), 222-228.
- [10]. MORENO, J.C., FERNANDEZ, A., ORTIZ, J. A.,MONTALVO, J. J., 2000. Complications
- [11]. RENTON, T. F., WIESENFELD, D., 1996. Mandibular fractures osteosynthesis:a comparison of three techniques. *British Journal & Oral MaxillofacialSurgery*, 34, 166-73.
- [12]. LIN, Y., WANG, X., Y, B., 2000. Miniplate osteosynthesis in mandibular fracture. *Chinese journal of stomatology*, 35(2), 85-87.
- [13]. PASSERI LA, ELLIS 3rd E, SINN DP.,1993. Complications of nonrigid fixation of mandibular angle fractures. *J Oral Maxillofac Surg* 51(4),382-4
- [14]. CHOI BH, KIM KN, KANG HS., 1995. Clinical and in vitro evaluation of mandibular angle fracture fixation with the two-miniplate system. *Oral Surg Oral Med Oral Pathol Oral Radiol Endod* 79(6),692-5.
- [15]. ELLIS 3rd E, WALKER L., 1994. Treatment of mandibular angle fractures using two noncompression miniplates. *J Oral Maxillofac Surg* 52(10),1032-6.
- [16]. SINGH V.,KHATANA S.,BHAGOL A,2014. Superior border versus inferior border fixation in displaced mandibular angle
- [17]. Al-Tairi, N.H., SHOUSHAN, M.M.,SAAD, KHEDR M.M., ABD-ALAL, S.E.,2015. Comparison of three-dimensional plate versus double miniplateosteosynthesis for treatment of unfavorable mandibular angle fracture.*Tanta Dental journal*,12,89-98.

- [18]. RAHPEYMA AMIN, KHAJEHAHMADI SAEDEH and BARKHURI SADEGH,2014.Treatment of mandibular fractures by two perpendicular mini-plates. Iranian journal of Otorhinolaryngology,45,234-236.
- [19]. ALKAN, A., CELEBI, N., OZDEN, B., INAL, S., 2007. Biomechanical comparison of differnt plating tecnique in repair of mandibular angle fracture. *Journal of oral surgery oral medicine oral pathology oral radiology*, 104(6), 752-6.
- [20]. GUIMOND. C., JOHNSON, J., MARCHENA. J., 2005. Fixation ofmandibular angle fractures with a 2.0-mm 3-dimensional curved angle strut plate. *Journal of Maxillofacial Surgery*,63, 209-14.
- [21]. POTTER J, ELLIS 3rd E.1999. Treatment of mandibular angle fractures with a malleable noncompression miniplate. *J Oral Maxillofac Surg* 57(3),288-92.
- [22]. ABBAS, I., ALI . K., MIRZA , YB., 2003. Spectrum of mandibular fracture at a tertiary care dental hospital in lahore, *Journal of AyMedical college*, 15, 12-14.
- [23]. MUZZAFAR, K, 1998. Management of maxillofacial trauma, *AFID Dental journal*, 10, 18-21.
- [24]. SCHON, R., ROVEDA SIL, CARTER, B. , 2001. Mandibular fractures inTownsville, Australia: incidence, aetiology and treatmentusing the 2.0 AO/ASIF miniplatesystem. *Brithish Journal of Oral MaxillofacialSurgery*, 39, 145-8.
- [25]. HUSSAIN, S., AHMAD, M., KHAN, I., ANWAR, M., AJMAL. S.,et al. 2003. Maxillofacial trauma: current practice in management atPakistan Institute of Medical Sciences. *Journal ofAyubMedical College*, 15, 8-11.
- [26]. CHEEMA S.A., CHEEMA, S.S., 2004. An analysis of etiologies, pattern andtreatment modalities of fracture mandible.*Journal of Ann King EdwardMedical College*, 10, 397-40.
- [27]. WONG, K. H., 2000. Mandible fractures: a 3 –year retrospective studyof cases seen in an oral surgical unit in Singapore. *SingaporeDental Journal*, 23, 6-10.
- [28]. TELFER, M.R., JONES G. M., SHEPHERD, J.P.,1991.Trends in the aetiologyof maxillofacial fractures in the United Kingdom (1977-1987).*British Journal of Oral &Maxillofacial Surgery*, 29, 250-5.
- [29]. ANSARI, S.R., KHITAB. U., QAYYUM Z, KHATTAK, A., 2004. Retrospectiveanalysis of 268 cases of fractures of mandible.*Pakistan Oral & Dental Journal*, 24, 135-8.
- [30]. EDWARD, T.J., DAVID, D.J., SIMPSON D. A., ABBOTT, A. A., 1994. Pattern of mandibular fractures in Adelaide, South Australia. *Australia NewZeland Journal of Surgery* , 64, 307-11.
- [31]. DANDA AK.,2010. Comparison of a single noncompression miniplate versus 2 noncompression miniplates in the treatment of mandibular angle fractures: a prospective, randomized clinical
- [32]. YAZDANI J, TAHERI TALESH K, KALANTER Motamedi MH, KHORSHIDI R, FEKRI S, HAJMOHAMMADI S.,2013. Mandibular angle fractures: comparison of one miniplate versus two miniplates. *Trauma Mon*18(1),17-20.

Md. Mamunur Rashid, et. al. "Efficacy of Two Perpendicular Mini-Plate for the Treatment of Mandibular Angle Fracture." *IOSR Journal of Dental and Medical Sciences (IOSR-JDMS)*, 21(06), 2022, pp. 31-39.