

Bony Ankylosis Mimicking Benign Chondroma: A clinico-radiographic correlation

Dr Anumita Deka *PG Student Department of Oral Medicine and Radiology K D Dental College and Hospital Mathura*

Dr Anuj Gaur *Reader Department of Oral Medicine and Radiology K D Dental College and Hospital Mathura*

Dr Sameeksha Bhardwaj *PG Student Department of Oral Medicine and Radiology K D Dental College and Hospital Mathura*

Dr Krishna Gopal Sharma *PG Student Department of Oral Medicine and Radiology K D Dental College and Hospital Mathura*

Abstract

Temporomandibular joint ankylosis is the bony or fibrous adhesion of the temporomandibular joint parts causing limitations in opening the mouth, difficulty during mastication, speech and oral hygiene as well as contributing to mandibular growth. Trauma is the leading cause of TMJ ankylosis (TMJA) which is an interaction between bony areas within the TMJ. Chondromas are benign tumors of mature hyaline cartilage, often damaging the anterior maxilla and condyles. When chondromas emerge from the condyles, and depending on the size, it causes a limitation in opening of the mouth. Here, we present a case of a 20-year-old man who had bony ankylosis of the left TMJ. Diagnostic hypotheses of benign chondroma and ankylosis were made. Surgical excision confirmed bony ankylosis with sclerotic exophytic bony overgrowth.

Key Words: Temporomandibular joint, ankylosis, chondroma.

Date of Submission: 08-06-2022

Date of Acceptance: 24-06-2022

I. Introduction

Bony ankylosis of the temporomandibular joint (TMJ) is an interaction between the condyle and the temporal bone, which partially or completely destroys the articular area and causes joint deformities. It may include a part of the condyle of the mandible, a part of the temporal bone, and part of the zygomatic process. Common causes of ankylosis include trauma (31% -98%), infection (10% -49%), and certain systemic diseases [1]. Meanwhile, chondroma is a benign tumor of mature hyaline cartilage of mesenchymal origin and based on their location, chondromas can be classified as (1) enchondromas found in the medullary cavity of the bony skeleton; (2) juxtacortical or periosteal chondromas occurring near the periosteum below the cortical surface; and (3) extra-skeletal or soft tissue chondromas reported on the tongue and buccal mucosa [2]. Embryonic development of the temporo mandibular joint (TMJ), by endochondral ossification, makes this area the most common facial area of bone marrow. It represents about 35% to 50% of all benign tumors, and 8% to 15% of all primary bone tumors. [3]

II. Case Report

A 20-year-old man reported to our department of Oral Medicine and Radiology to be examined for the chief complaint of "limited mouth opening" from the age of 7-8 years. His previous medical history was significant because he reported 8 year old history of trauma with a condylar fracture, which was not treated at the time. Further extraoral examination showed horizontal asymmetry of the lower third of the face with the shape of a dolicocephalic head and the appearance of a "bird's face". The mandible had a retrognathic rudimentary chin and sharp antegonial notches with a regular maxilla. On examination of the TMJ, minimal movement present with a depressed presentation. There was a slight deviation of the mandible to the right side while opening mouth but there was no tenderness present, clicking and crepitation sounds were present on auscultation. The width of the movement was noted; vertical - 7mm (interincisally), protrusion - absent, lateral movement - absent. There was no significant intraoral finding.

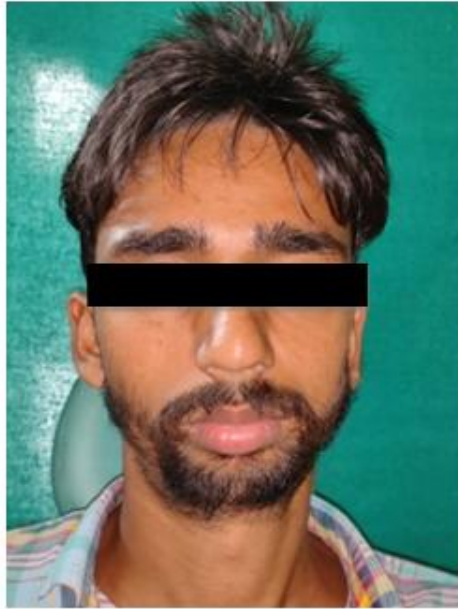

Fig 1: Preoperative extraoral

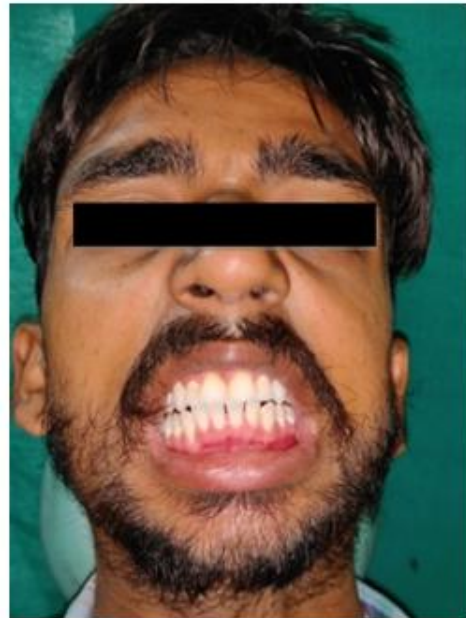

Fig 2: Preoperative mouth opening

RADIOGRAPHIC EXAMINATION

An orthopantomogram was taken that revealed radiopacity in the condylar region on the left side, and an increase in condylar neck length and sharp antegonial notches bilaterally.

A computed tomography with 3-D reconstruction was done which revealed sclerotic lesion in the left ramus and left mandibular condyle with thickening of the left body and ramus. The lesion appeared to be exophytic and sclerotic with cortical irregularity. It also progressed with the zygoma indenting the pterygoid muscle medially and compresses it and then extends to the parapharyngeal space.

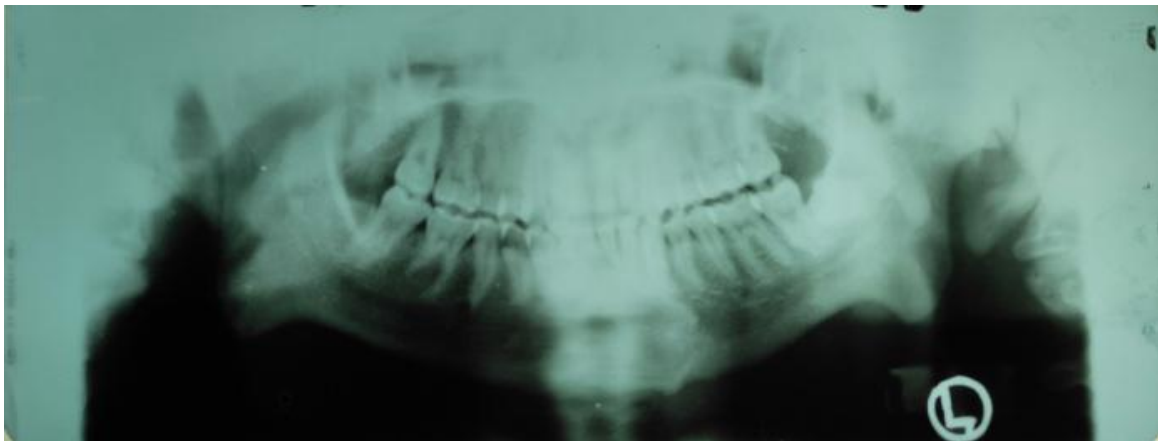


Fig 3: Pre operative orthopantomogram

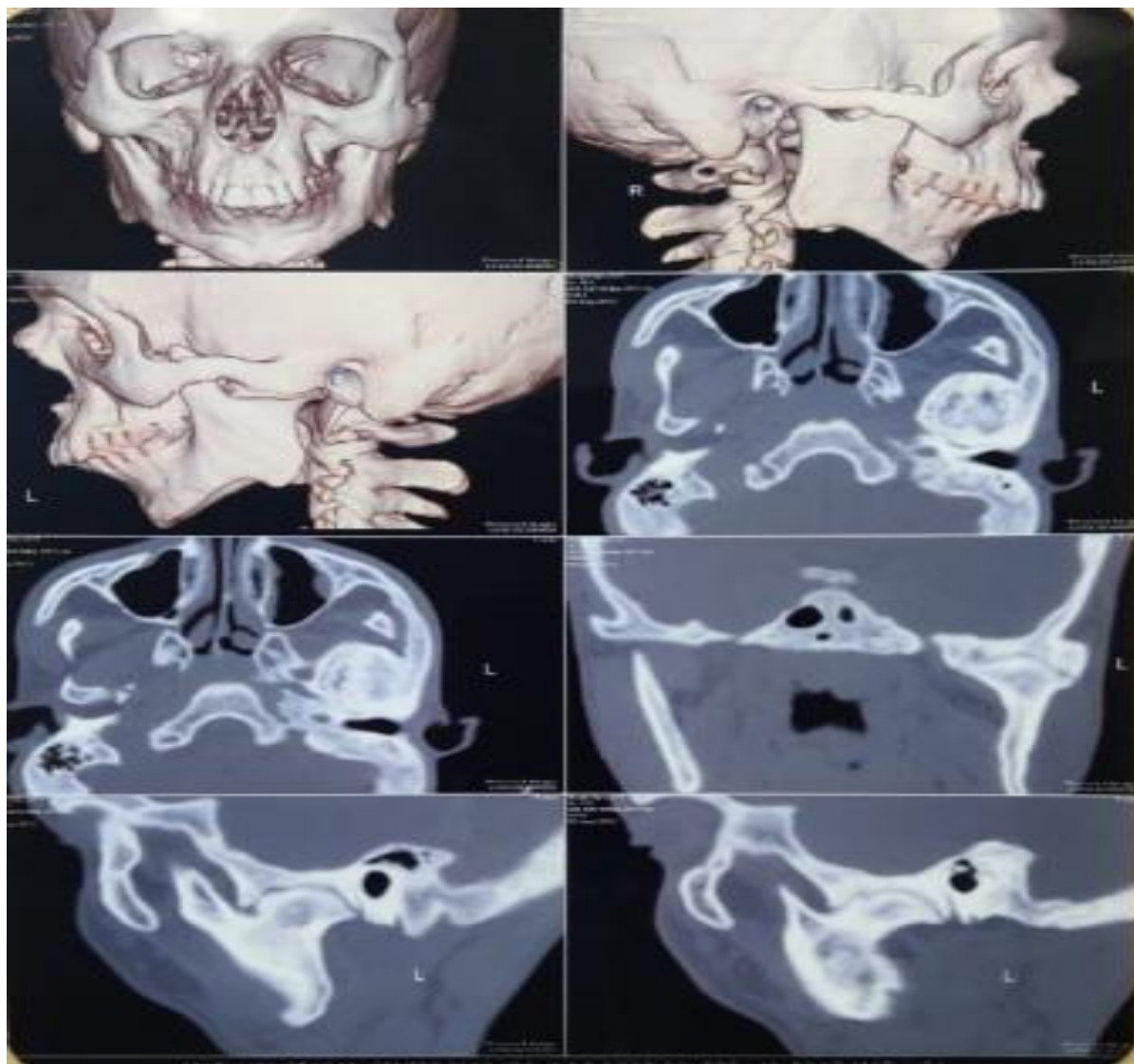


Fig 4: Preoperative CT scans with 3D reconstruction

TREATMENT PLAN

Based on clinical and radiographic analysis, a provisional diagnosis of TMJ ankylosis of the left side with benign chondroma in the left condyle was made. **Differential diagnosis** included (a) condylar hyperplasia, (b) osteochondroma, (c) osteoma, (d) chondroma, (e) osteoblastoma, (f) fibrous dysplasia, (g) ossifying fibroma, (h) chondromyxoid fibromas, (i) synovial chondromatosis, (j) chondroblast, (k) chondrosarcoma, and (l) osteosarcoma [2]. A surgical resection of the growth under general anesthesia was performed. Post operative OPG with open mouth was taken. 2 weeks post surgery his mouth opening was wide enough for a good range of motion.

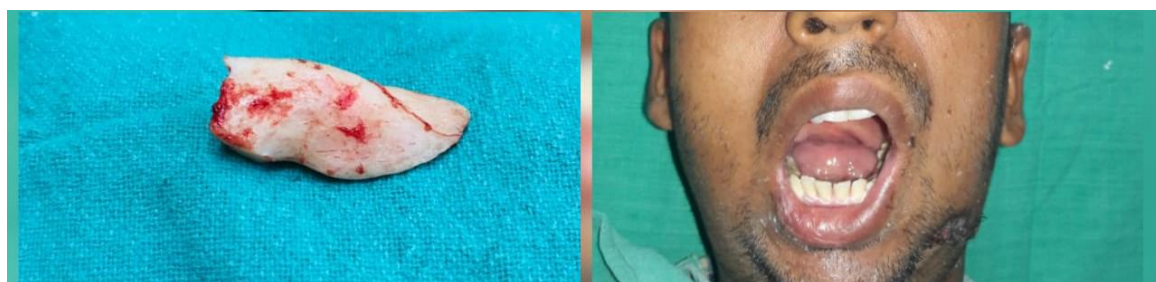

Fig 5. I. Exophytic bony growth extracted from **Fig 5.II. Post operative mouth opening of the patient**
patient

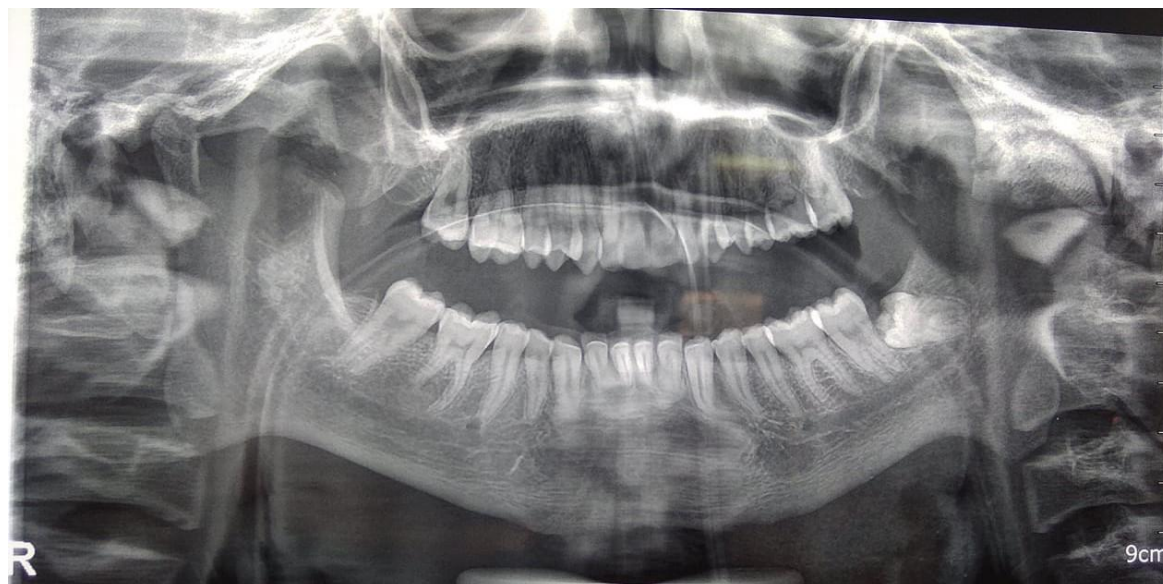

Fig 6. Post surgical OPG

III. Discussion

There is no significant correlation between a tumor development and trauma. [2]

Chondroma has no special sex predilection; are rare and are usually found in the third and fourth decade of life. Most chondromas are undetectable. Chondromas involving TMJ may be undetectable or clinically confusing, due to their rarity. This condition may be associated with a variety of symptoms ranging from clicking, limited mouth opening, deviation, and mild symptoms of condylar dislocation. They almost always grow slowly in nature. [2]

In our case, the patient's main concern was the limited opening of the mouth. Following surgery, his complaint was completely resolved. [2]

Radiographically, chondromas are mostly radiolucent, abnormal masses. They may have calcified foci with powder like or thick aggregates. [2]

Surgical resection is the preferred treatment for mandibular condyle chondroma. The surrounding area of normal tissue should also be cut to prevent recurrence. After condylectomy, usually, reconstruction is performed to restore the height of the ramus and to establish the proper function of TMJ. [2]

It is very important in such cases to maintain long-term follow-up. It is also important to report such cases to take into account the type, behavior and pattern of disease progression, the views of surgeons and any changes in the treatment line of those rare cases. [2]

References

- [1]. Song JY, Kim SG, Choi HM, Kim HJ. Severe bony ankylosis of the temporomandibular joint on one side and contralateral adhesion: A case report. *Imaging Sci Dent*. 2015 Jun; 45(2):103-8. doi: 10.5624/isd.2015.45.2.103. Epub 2015 Jun 19. PMID: 26125005; PMCID: PMC4483616.
- [2]. Dhirawani RB, Anand K, Lalwani G, Pathak S, Thakkar B. True chondroma of the mandibular condyle: A rare case. *Ann Maxillofac Surg*. 2014 Jul-Dec; 4(2):220-3. doi: 10.4103/2231-0746.147152. PMID: 25593880; PMCID: PMC4293851.
- [3]. More CB, Gupta S. Osteochondroma of mandibular condyle: A clinic-radiographic correlation. *J Nat Sci Biol Med*. 2013 Jul;4(2):465-8. doi: 10.4103/0976-9668.116969. PMID: 24082753; PMCID: PMC3783801.

Dr Anumita Deka, et. al. "Bony Ankylosis Mimicking Benign Chondroma: A clinico-radiographic correlation." *IOSR Journal of Dental and Medical Sciences (IOSR-JDMS)*, 21(06), 2022, pp. 01-04.