

# Clinical Review of the Experience with Various Reconstructions Done Immediately Post Resection of Cancer in the Head and Neck Region

Dr. Dhrumil Sarkar

<sup>2nd</sup> Dr. Arvind Patel { HOD Dpt Plastic surgery }

<sup>3rd</sup> Dr. Shamshudin Virani {HOD Dpt. Surgical Oncology Kiran Hospital }

<sup>4th</sup> Dr. Raghvender kurdeker {Dean Vyas dental college and hospital ,Hod Oral and maxillofacial surgery Dept. }

<sup>5th</sup> Dr. Ashish Vyas { Associate Professor Dpt Oral and maxillofacial surgery Vyas Dental college }

<sup>6th</sup> Dr. Sheetal Raju {Post Graduate student oral surgery vyas dental college }

---

## Abstract:-

### Background:-

Following a radical cancer surgery resection, reconstruction of the defect by microvascular free flaps seems to be an ideal procedure for reconstruction in the head and neck region. These provide ample amount of tissue for large and even complex defects and enhance reconstruction. Microvascular-free flaps have also provided flexibility for the onco- surgeon for extensive surgical resections.

### Method:-

There were about 48 free flaps performed in a span of 3 months from December 2020 to February 2021 in the surgical oncology department of kiran multispecialty hospital, Surat. For reconstruction of both bony and soft tissue defects. The choice of free flaps was the Free fibula flap along with the Radial and Anterio-lateral thigh flap.

**Results:-** the success rate of the viability with the proper clinical outcome of the reconstructive flaps was 85.41% with 14.5% of Cases ending up in some complications {major and minor} and could be corrected with no major salvage surgery required and the minor complications which were seen during the period were **OCF (ORO CUTANEOUS FISTULA), partial flap necrosis, etc.**

**Conclusions:-** Free flap reconstruction is a robust and highly reliable option for head and neck defects, in case of a large defect using the 2 free flap would be a safe option as a choice of treatment to avoid failure. In case of a failed free flap, another free flap should be the choice of treatment after the medical optimization of the patient. Free flap reconstruction is safe in elderly and post-radiotherapy patients.

---

Date of Submission: 26-07-2022

Date of Acceptance: 09-08-2022

---

## I. INTRODUCTION

Free flap reconstruction of the head and neck was introduced by Seidenberg in 1959 with the jejunal free flap.<sup>1</sup> Because of improved knowledge of donor site anatomy<sup>2</sup> and advances in microvascular surgery,<sup>3</sup> it has become the most reliable and efficient method for restoring tissue of regions of the head and neck that have been resected because of pathologies such as cancer and trauma.<sup>4,5</sup> Immediate free flap reconstruction after ablative oncology surgery has proven safe, reliable, and reproducible and has become the standard of care.<sup>6</sup> Acceptable functional and aesthetic outcomes have been achieved with free flap reconstruction. Better magnification and refined instrumentation have improved results with success rates up to 98%<sup>7</sup> These developments have enabled head and neck surgeons to be more skeptical and radical in tumor resections. This in turn has enabled better local control of disease compared with the era before the routine use of free flaps.<sup>8,9</sup> Today, microsurgical free flap is the accepted standard of care for head and neck reconstruction after tumor extirpation.<sup>10-</sup>

<sup>13</sup>. The radial artery forearm flap (RAFF) and anterolateral thigh (ALT)

flap are ideal for soft tissue defect reconstruction in the head and neck region. Free radial forearm flap reconstruction was first introduced by Yang et al.<sup>14</sup> in 1978 and has remained an ideal choice for certain situations that require a small, thin flap. Such situations include small tongue defects where tongue mobility is more important, lip reconstruction, small mucosal defects, nose reconstruction, and palatal reconstruction. Song et al.<sup>15</sup> first described using the ALT flap in 1984, which replaced the radial forearm flap as the most common flap due

to its high reliability and the availability of ample of tissue that can be harvested with less donor site morbidity. In cases with bony defects of the mandible and maxilla, the free fibula has become the flap of choice. The bone stalk is also good for the placement of dental implants <sup>16</sup>

**II. MATERIAL AND METHODS:-**

In the following study, there were a total of 48 patients treated for oral cancer and reconstruction was performed immediately for the patient within a span of 3 months from December 2020 to February 2021 to resolve the defect of the head and neck region. The total surgical time was reduced by using a 2 team approach for harvesting flap and oncologic resection. The anastomosis is carried out by first anastomosing the artery followed by the vein. 46 out of 48 arterial anastomoses were carried out in the facial artery whereas the rest 2 done with the lingual artery. Post-surgery, the patient was monitored for a week for any major or minor complications. Any major complication was defined as any complication which required a major salvage surgery. The minor complication was defined as ones that were managed conservatively.

**III. Result:-**

The mean age for the patient was 47 with male SEX showing more incidence of cancer than females. The medical record including tumor type, flap type, outcomes, and complications was analysed. With most common sites as the mandible or the lower alveolus followed by buccal mucosa followed by the tongue then the maxilla and then the lip (table 1)

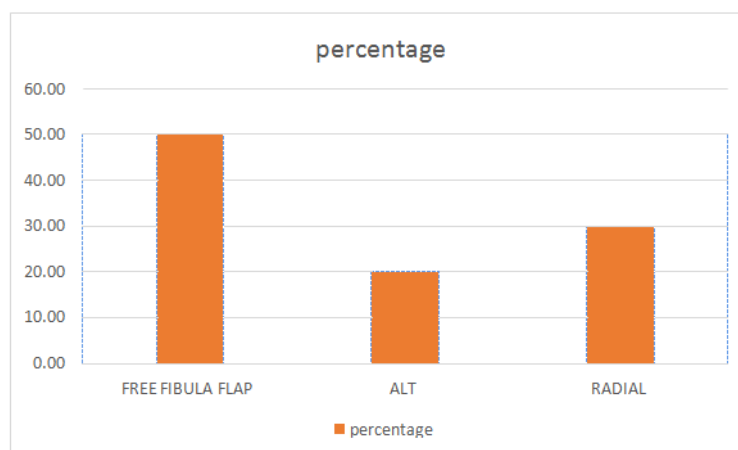
Site	total num	Percentage
buccal mucosa	14	29.16666667
Lip	1	2.083333333
mandible	23	47.91666667
Maxilla	2	4.166666667
Tounge	8	16.66666667
total	48	100

**Table 1 :- Showing the site of malignancy**

In this time period there was a total of 48 patients being treated with all being performed with immediate reconstruction post-onco-resection. A total of about 48 free flaps was performed with 14 radial, 10 alt, and 24 free fibula flaps (table 2, chart 1), no patient underwent a multiple flap approach.

FREE FLAPS	No of Case	Percentage
FREE FIBULA FLAP	24	50.00
ALT	10	20.83
RADIAL	14	29.17
Total	48	100.00

**Table 2 :- number of flaps performed**



**Chart 1 :- frequency of each flap**

There were 2 major complications that required emergency re-exploration and 5 minor complications (table 3 chart 2), which were managed conservatively. The 2 patients were examined for vascular compromise. In both the cases the flaps could be salvaged with no donor site complication observed in any of the patients

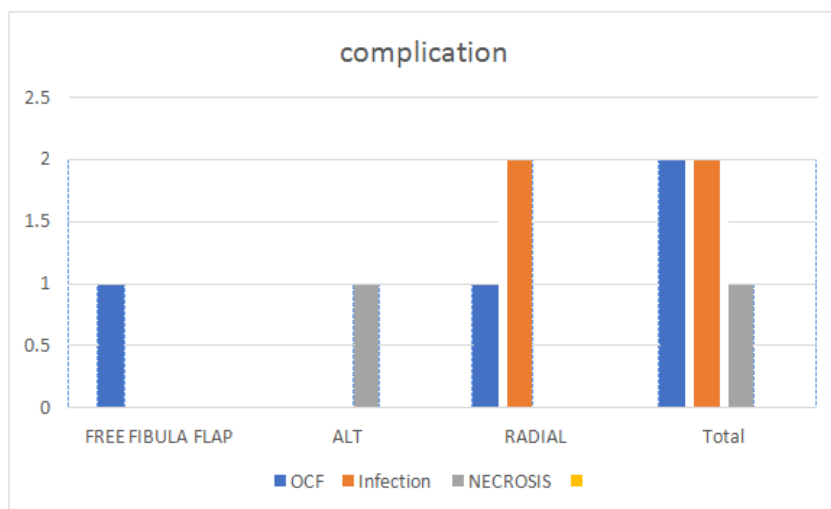


Chart 2 :-showing the incidence of complication

FREE FLAPS	Complication		
FREE FLAPS	OCF	Infection	NECROSIS
FREE FIBULAFLAP	1	0	0
ALT	0	0	1
RADIAL	1	2	0
Total	2.00	2.00	1.00

Table 3:- individual flap with individual complications faced

The average length of intensive care unit stay was around 48 h and the total hospital stay was 5 to 7 days. On the fifth day, oral liquids were allowed and Ryle’s tube was removed between 10 and 14 days.

#### IV. Discussion:-

Free flaps have become the ideal choice for head and neck reconstruction. In high-volume centers, the global success rate of free flap survival is approaching 98%<sup>17-20</sup>. The selection of free flap is difficult, however, for an individual surgeon to be comfortable with the whole spectrum of flaps described. We have consolidated our approach, and have relied on a limited number of “workhorse” flaps for the majority of our reconstructive needs.<sup>21</sup> Currently, workhorse flaps are the anterolateral thigh, radial forearm, and fibula osteoseptocutaneous. These flaps were selected because they allow the versatility of harvesting a variable amount of soft tissue of various components, and they reliably provide a long and sizable vascular pedicle. The fibula provides an unparallel quantity and quality of bone when bony reconstruction is needed. These workhorse flaps have enabled us to reconstruct virtually all types of head and neck defects. These flaps were selected because they allow the versatility of harvesting a variable amount of soft tissue of various components, and they reliably provide a long and sizable vascular pedicle. The fibula provides an unparallel quantity and quality of bone when bony reconstruction is needed. These workhorse flaps have enabled us to reconstruct virtually all types of head and neck defects

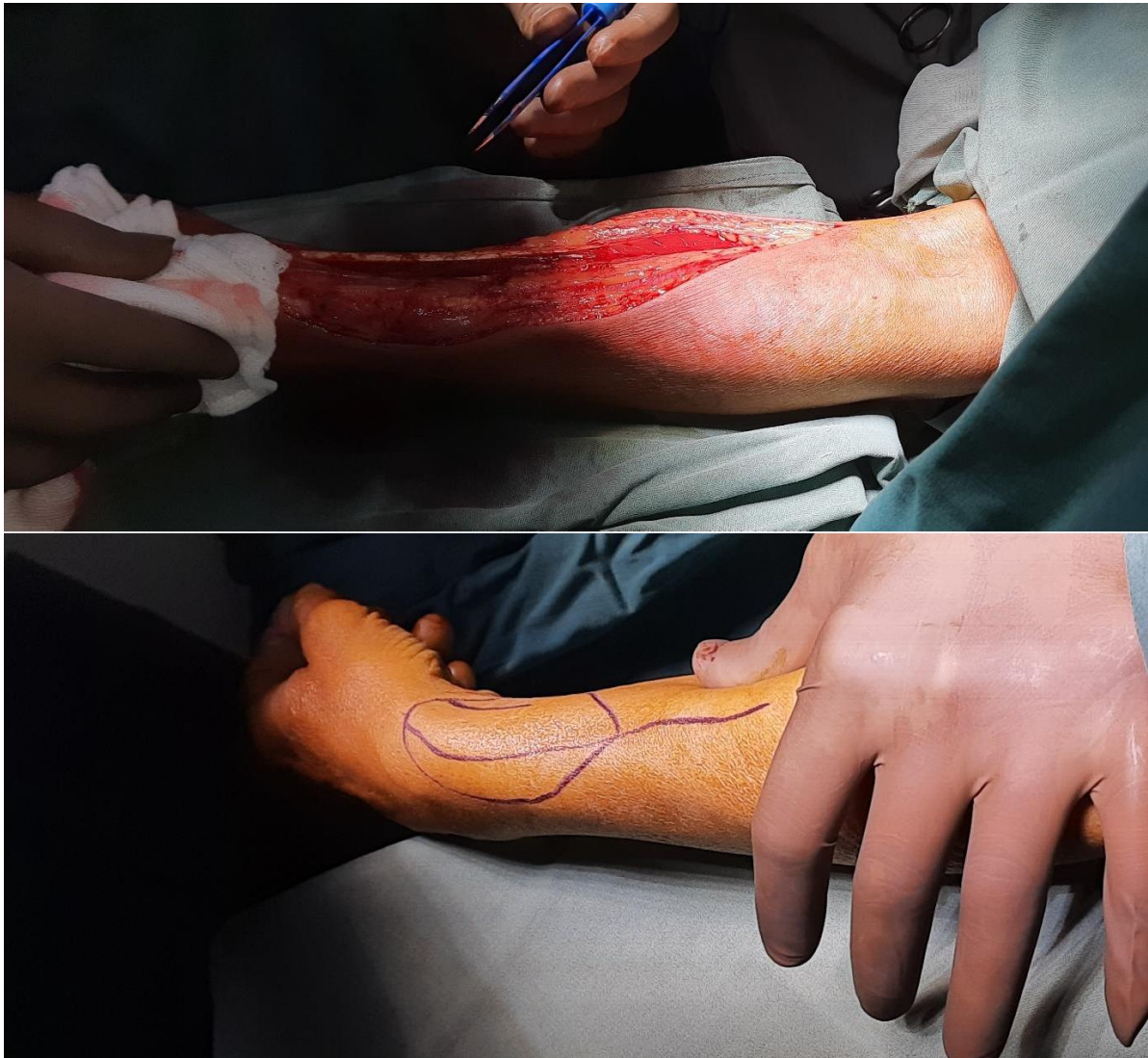At the oncology department of kiran multispeciality hospital, the overall success rate was found to be 98.1%. The exploration of 4.16 % for compromised flaps this data is compared favorably with the available data in the literature for surgical re-exploration for compromised flaps between 3-20%. During the duration of the study venous insufficiency was the most common complication for re-exploration. The finding of the study is consistent with reports published in the literature<sup>22, 23, 24, 25</sup>. This is due to the reason the venous wall is thin as compared to the atrial wall as the venous pressure is less compared to the atrial pressure and therefore there are more susceptible to compression in the reconstruction of the head and neck. Watertight suturing is needed for the cases in the head and neck because the flap edema exerts pressure as compared to loss suturing in any other

region. There are various reasons for vascular compression including narrow subcutaneous or submandibular tunnel, wound bed hematoma, excessive pedicle length leading to vessel kinks, improper positioning of the artery over the veins, tight dressing over the neck, acute neck flexion, and the body posture of the patient. Venous insufficiency was the main cause of re-exploration in our study, but the flap salvage rate was quite high in this group in contrast to arterial insufficiency<sup>26</sup>. Apart from this, venous congestion, bleeding, partial flap necrosis, and orocutaneous fistula formation were more common minor complications.

### References

- [1]. Seidenberg B. Immediate reconstruction of the cervical esophagus by a revascularized isolated jejunal segment. *Ann Surg*1959;149:162.
- [2]. Taylor GI, Razaboni RM. Michel Salmon's anatomical studies. Book 1. Arteries of the muscles of the extremities and the trunk. St Louis: Quality Medical Publishing; 1994.
- [3]. O'Brien BMcC. Microvascular reconstructive surgery. Edinburgh, London, New York: Churchill Livingstone; 1977.
- [4]. Kroll SS, Schusterman MA, Reece GP. Comparison of the rectus abdominis free flap with the pectoralis major myocutaneous flap for reconstructions in the head and neck. *Am J Surg*1992;164:615-8.
- [5]. Kroll SS, Schusterman MA, Reece GP. Costs and complications in mandibular reconstruction. *Ann PlastSurg*1992;29:341-7.
- [6]. Suh JD, Sercarz JA, Abemayor E, et al. Analysis of outcome and complications in 400 cases of microvascular head and neck reconstruction. *Arch Otolaryngol Head Neck Surg*2004;130:962-966.
- [7]. Kesting MR, Holzle F, Wales C et al (2011) Microsurgical reconstruction of the oral cavity with free flaps from the anterolateral thigh and the radial forearm: a comparison of perioperative data from 161 cases. *Ann Surg Oncol* 18(7):1988-1994
- [8]. Blair EA, Callender DL. Head and neck cancer: the problem. *Clin PlastSurg*1994;21:1-7.
- [9]. Silverberg E, Boring CC, Squires TS. Cancer statistics, 1990. *CA Cancer J Clin* 1990;40:9-26.
- [10]. Gurtner GC, Evans GR. Advances in head and neck reconstruction. *PlastReconstrSurg*2000;106:672-682.
- [11]. Ariyan S, Ross DA, Sasaki CT. Reconstruction of the head and neck. *Surg Oncol Clin N Am* 1997;6:1-15.
- [12]. Nabawi A, Gu' rlek A, Patrick CW Jr, et al. Measurement of blood flow and oxygen tension in adjacent tissues in pedicled and free flap head and neck reconstruction. *Microsurgery* 1999;19:254-257.
- [13]. Lutz BS, Wei F-C. Microsurgical workhorse flaps in head and neck reconstruction. *Clin PlastSurg*2005;32:421- 430
- [14]. Yang G (1981) Forearm free skin flap transplantation; report of 56 cases. *Natl Med J China Med J China* 61:139
- [15]. Song Y, Chen G, Song Y (1984) The free thigh flap: a new free flap concept based on the septocutaneous artery. *Br J PlastSurg* 37(2): 149-159
- [16]. Lopez-Arcas JM, Arias J, Del Castillo JL et al (2010) The fibula osteomyocutaneous flap for mandible reconstruction: a 15-year experience. *J Oral MaxillofacSurg* 68(10):2377-2384
- [17]. Wei F-C, Demirkan F, Chen H-C, Chuang DCC, Chen SHT, Lin CH, Cheng SL, Cheng MH, Lin YT (2001) The outcome of failed free flaps in head and neck and extremity reconstruction: what is next in the reconstructive ladder? *PlastReconstrSurg* 108(5):1154-1160
- [18]. Liang J, Yu T, Wang X, Zhao Y, Fang F, ZengW LZ (2018) Free tissue flaps in head and neck reconstruction: clinical application and analysis of 93 patients of a single institution. *Braz J Otorhinolaryngol* 84(4):416-425
- [19]. Mao C, Yu G, Peng X, Guo C, Huang M, Zhang Y (2003) A review of 545 consecutive free flap transfers for head and neck reconstruction in a new microsurgery unit. *Zhonghua Er Bi Yan Hou Ke Za Zhi* 38(1):3-6
- [20]. Bui DT, Cordeiro PG, Hu Q-Y, Disa JJ, Pusic A, Mehrara BJ (2007) Free flap reexploration: indications, treatment, and outcomes in 1193 free flaps. *PlastReconstrSurg* 119(7):2092-2100
- [21]. Lutz BS, Wei F-C. Microsurgical workhorse flaps in head and neck reconstruction. *Clin PlastSurg*2005;32:421- 430
- [22]. Bianchi B, Copelli C, Ferrari S, Ferri A, Sesenna E (2009) Free flaps: outcomes and complications in head and neck reconstructions. *J Cranio-MaxillofacSurg* 37(8):438-442
- [23]. Devine JC, Potter LA, Magennis P, Brown JS, Vaughan ED (2001) Flap monitoring after head and neck reconstruction: evaluating an observation protocol. *J Wound Care* 10(1):525-529
- [24]. Ross G, Yla-Kotola TM, Goldstein D, Zhong T, Gilbert R, Irish J, Gullane PJ, Hofer SOP, Neligan PC (2012) Second free flaps in head and neck reconstruction. *J PlastReconstrAesthetSurg* 65(9): 1165-1168
- [25]. Wu C-C, Lin P-Y, Chew K-Y, Kuo Y-R (2014) Free tissue transfers in head and neck reconstruction: complications, outcomes and strategies for management of flap failure: analysis of 2019 flaps in single institute. *Microsurgery*. 34(5):339-344
- [26]. Issing PR, Kempf HG, Heppert W, Schonermark M, Lenarz T (1996) Reconstructive surgery in the head-neck area with regional and free tissue transfer. *Laryngorhinootologie*. 75(8):476-482

**Radial forearm free flap**



**FREE FIBULA**

