

MRI Imaging features of avascular necrosis of femoral head in patients treated for COVID-19

DR BUSHRA FARHEEN¹, DR.P.SIRISHA NAIDU²

¹(Department of Radiodiagnosis/Maharajahs institute of medical sciences/NTRUHS/India,)

²(Department of Radiodiagnosis/Maharajahs institute of medical sciences/NTRUHS/India)

Abstract:

Background: Avascular necrosis is the condition in which bones die after a diminished blood supply or a total cessation of blood supply (AVN). One of the bones that is frequently impacted is the femoral head. One of the main medical reasons of AVN is the overuse of corticosteroids. Patients who are affected typically express complaints of gradually worsening pain and decreased range of motion.

The study's goals is to examine the imaging characteristics of avascular necrosis (AVN) of the femoral head as seen in MRI scans of people who had COVID-19 treatment

Materials and Methods: The various patterns of AVN of the femoral head findings in 40 patients who underwent COVID-19 treatment and presented to MIMS hospital nellimarla with unilateral or bilateral hip pain can be noticed in the MRI pictures.

Results: Stage IV AVN was seen in 0 cases (0%). Stage I AVN was seen in 11 cases (3%). Stage II AVN was seen in 4 cases (2%). Stage III AVN was seen in 2 cases (1%)

Key Word: Avascularnecrosis (AVN)

Date of Submission: 04-08-2022

Date of Acceptance: 18-08-2022

I. Introduction

• Avascular necrosis is the condition in which bones die after a diminished blood supply or a total cessation of blood supply (AVN). One of the bones that is frequently impacted is the femoral head. One of the main medical reasons of AVN is the overuse of corticosteroids. Patients who are affected typically express complaints of gradually worsening pain and decreased range of motion.

• There is a wealth of diagnostic information available for identifying COVID-19 pneumonia, and many recommendations are being made for early detection and effective treatment.

• In order to better understand the range of AVN of the femoral head as shown in MRI scans of COVID-19 patients, a retrospective analysis was conducted.

Material And Methods

• Following the criteria, patients who had treatment for COVID-19 and experienced hip discomfort within six months were included

• COVID-19 is positive or nasopharyngeal/oropharyngeal swabs are used, SARS-CoV-2 RT-PCR results are positive. Taken steroids during COVID-19 treatment Prior to the COVID-19 MRI scan being altered, there was no new-onset hip pain.

• A total of 40 patients were included in the study.

• All patients were imaged using a multichannel 1.5 T PHILLIPS MRI machine. Coronal 4 mm T1W FSE images were obtained. Other sequences for MRI hip-like T2W and STIR in axial as well as sagittal planes were also obtained, but T1W coronal images were along used for the present study due to wider acceptance and better demonstration of the suspected AVN.

Study Design: retrospective observational study

Study Location: MIMS hospital nellimarla.

Study Duration: June 2021 to May 2022.

Sample size: 30 patients.

Sample size calculation: The sample size was estimated on the basis of a single proportion design. .

Subjects & selection method: The study population was drawn from patients presented with unilateral/bilateral hip pain and back pain after complete treatment for COVID-19.

Inclusion criteria:

Patients with unilateral/bilateral hip pain after complete covid-19 treatment.

Exclusion criteria:

1. Claustrophobic people.
2. Patients with a history of drug or alcohol abuse
3. Patients taking concurrent corticosteroids, hormone replacement therapy.
4. Any electrically, magnetically or mechanically activated implant.
5. Intra cranial aneurysm clips (unless made of titanium)
6. Ferromagnetic surgical clips or staples.

Procedure methodology

Technique:

MR Imaging was done with a 1.5 Tesla Phillips ingenia superconductive scanner

For MR imaging, the following sequences were selected as required:

PD Transverse spin-echo (TR/TE – 3000/34, Slice thickness – 3mm

T2 weighted Transverse spin-echo (TR/TE – 9220/96, Slice thickness – 3 mm

T1 weighted Coronal spin-echo (TR/TE – 800/12, Slice thickness – 3 mm

T1 weighted Coronal FSE (TR/TE – 710/7 10, Slice thickness – 3 mm

T2 weighted Coronal 3D (TR/TE – 17 9/6 6, Slice thickness – 0 8 mm

T1 weighted Coronal STIR (TR/TE – 3500/31, Slice thickness – 3 mm

The intravenous contrast (Gadolinium in a dosage of 0.1

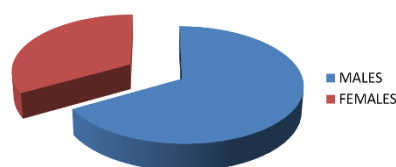
mmol/kg) was administered intravenously as and when necessary based on the MRI findings and contrast-enhanced MRI was performed on T1 weighted Coronal FSE sequence.

II. Result

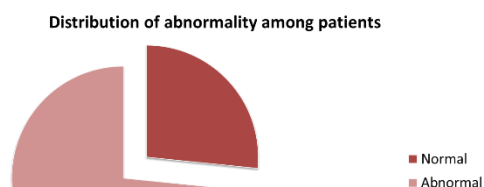
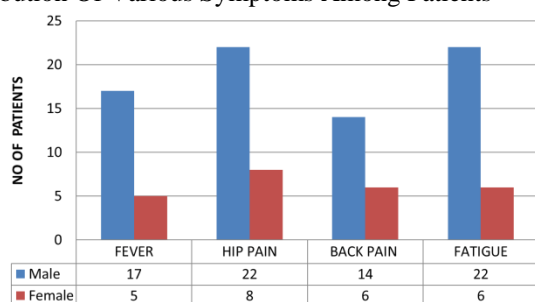
Abnormality was found in 22 patients out of 30 patients Stage IV AVN was seen in 3 cases (13.6%). Stage I AVN was seen in cases 11 (50%). Stage II AVN was seen in cases 5 (22%). Stage III AVN was seen in cases 3 (13.6%).

Criteria	Male	Female	Total
Gender	22	8	30
Symptoms			
Fever	17	5	22
Hip pain	22	8	30
Backache	14	6	20
Fatigue	22	6	28
Comorbidities			
Diabetes	4	0	04
Hypertension	5	2	07

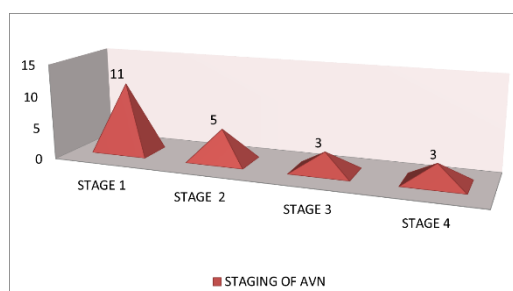
Sex distribution among patients



Distribution Of Various Symptoms Among Patients



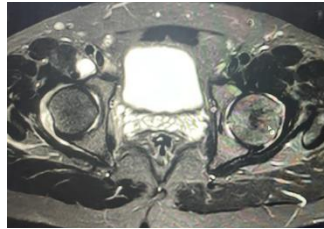
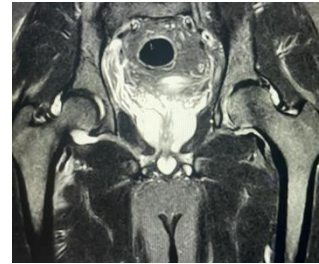Features on MRI	n=30(%)
Stage 0: Normal study: No abnormality	8
Stage 1: Edema in femoral head	11
Stage 2: Geographic defect in femoral head	05
Stage 3: Collapse of femoral head	03
Stage 4: Secondary changes of osteoarthritis	03



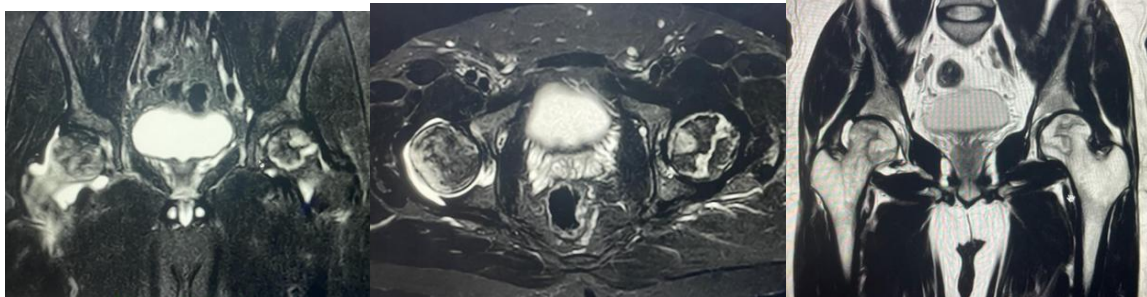
III. Discussion

- The vascularity of the femoral head is inadequate in osteonecrosis (ONFH), which results in the loss of the osteocytes and bone marrow. In majority of instances of this illness, which often affects young people, begin unilaterally, while up to 75% of cases might also have bilateral affection. Its etiology, which is induced by the use of corticosteroids or excessive alcohol use, can be primary or secondary. While the early stages of ONFH cannot be seen on simple hip radiographs, MRI is the investigation of choice.
- Glucocorticoids hinder the blood vessel's ability to respond to substances that are vasoactive, which results in vascular constriction that affects the femoral head and worsens the ischemia.
- Recent studies have suggested that people with mild to moderate COVID-19 sickness shouldn't receive corticosteroids. Only individuals with serious illnesses should be given steroids.
- It must be kept in mind that as COVID-19 recovery progresses, we will notice an increase in post-convalescence problems such AVN, which can severely impede the return to normal in such individuals. We are therefore better able to diagnose and treat AVN the earlier we evaluate any newly developed big joint discomfort in such individuals.
- Timely therapy is ensured by prompt diagnosis. Therefore, it has been discovered that periodic MRI scans for potential AVN of the hip, especially in high-risk individuals, are 93–100% sensitive. After using glucocorticoids for a period of time, it has been shown that MRI scans should be done 3, 6, and 12 months later.
- This is owing to the early detection of every case thanks to the affected patients' prompt presentation. The most prevalent stage, Abnormality was found in 22 patients out of 30 patients Stage IV AVN was seen in 3 cases (13.6%). Stage I AVN was seen in cases 11 (50%). Stage II AVN was seen in cases 5 (22%). Stage III AVN was seen in cases 3 (13.6%).
- In the current study, those aged 40 and older were the most often impacted age group. Given that they belonged to the active working-age group, it is likely that this specific age group resumed to their normal tasks after receiving treatment for COVID-19. Hip lesions were not developed till that time since MRI was still in its early stages. Despite the patients' symptoms, it's also conceivable that they weren't caused by hip-related issues in the first place.

Classification and staging systems for osteonecrosis	
Ficat and Arlet	
Stage I	Normal
Stage II	Sclerotic or cystic lesions
	A) No crescent sign B) Subchondral collapse (crescent sign) without flattening of the femoral head
Stage III	Flattening of femoral head
Stage IV	Osteoarthritis with decreased joint space with articular collapse



Small ill-defined focal area of oedema involving medial portion of left femoral head –s/o early changes of avascular necrosis.



RIGHT FEMORAL HEAD-

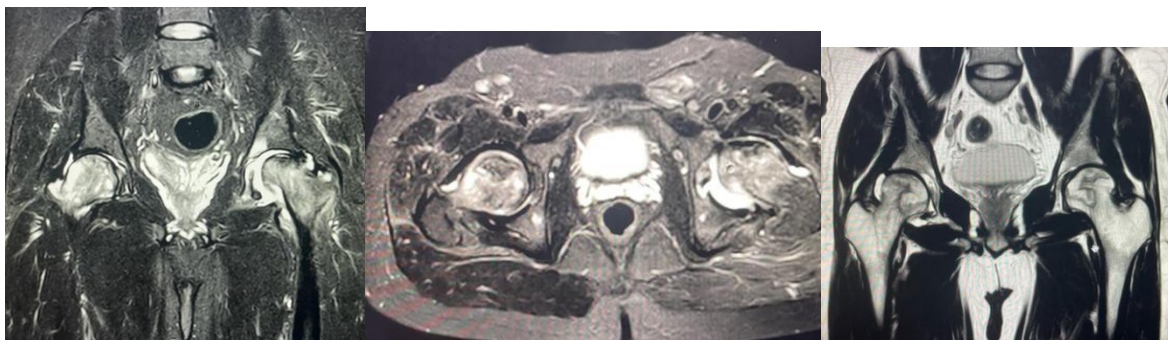Serpiginous areas of abnormal heterogeneous signal intensity on all sequences showing double line sign and subchondral crescentsign. ill-defined marrow edema is seen involving femoral head. Mild joint effusion.

LEFT FEMORAL HEAD-

Serpiginous area of abnormal heterogeneous signal intensity on all sequences showing double line sign. however femoral head contour is maintained.

BILATERAL AVASCULAR NECROSIS OF FEMORAL HEAD

Ficatand arletclassification (stage III on right side and stage II on left side.)



RIGHT FEMORAL HEAD

Geographic area of altered signal intensity (T2/STIR hyperintense with focal areas of hypo intensity) lined by thin sclerotic rim and double line sign is Seen. Bone marrow oedema is noted in femoral head and neck.

LEFT FEMORAL HEAD

Joint effusion.

Geographic area of T2/STIR hypo intensity with serpiginous rim is noted in anteromedial aspect of left femoral head with surrounding bone marrow oedema in femoral head, neck, Femoral head contour appears irregular with subchondral collapse.

BILATERAL AVASCULAR NECROSIS ficat and arlet stage IV on left side and stage II on right side.

IV. Conclusion

As more individuals who recently underwent treatment for COVID-19 develop AVN of the hips, the number of cases is likely to rise. For prompt diagnosis and treatment, the medical community should be aware of this potential and notify the patients about this entity.

- *Financial support and sponsorship*

Nil.

- *Conflicts of interest*

There are no conflicts of interest.

References

- [1]. Ligong F, Liu H, Lei W. MiR-596 inhibits osteoblastic differentiation and cell proliferation by targeting Smad3 in steroid-induced osteonecrosis of femoral head. *J Orthop Surg Res.* 2020;15:173.[CrossRef] [PubMed] [Google Scholar]
- [2]. Yamasaki K, Nakasa T, Miyaki S, Yamasaki T, Yasunaga Y, Ochi M. Angiogenic microRNA-210 is present in cells surrounding osteonecrosis. *J Orthop Res.* 2012;30:1263-70.[CrossRef] [PubMed] [Google Scholar]
- [3]. Jia J, Feng X, Weihua X, Yang S, Zhang Q, Liu X, et al. MiR-17-5p modulates osteoblastic differentiation and cell proliferation by targeting SMAD7 in non-traumatic osteonecrosis. *Exp Mol Med.* 2014;46:e107.[CrossRef] [PubMed] [Google Scholar]
- [4]. Hui L, de Vlas SJ, Liu W, Wang TB, Cao ZY, Li CP, et al. Avascular osteonecrosis after treatment of SARS: A 3-year longitudinal study. *Trop Med Int Health.* 2009;14:79-84.[CrossRef] [PubMed] [Google Scholar]
- [5]. Shibata M, Fujioka M, Arai Y, Takahashi K, Ueshima K, Okamoto M, et al. Degree of corticosteroid treatment within the first 2 months of renal transplantation has a strong influence on the incidence of osteonecrosis of the femoral head. *Acta Orthop.* 2008;79:631-6.[CrossRef] [PubMed] [Google Scholar] Turner DA, Templeton AC, Seizer PM, et al. Femoral capital osteonecrosis: MR findings of diffuse marrow abnormalities without focal lesions. *Radiology.* 1989;171:135-140. [PubMed] [Google Scholar]
- [6]. Totty WG, Murphy WA, Canz WI, Kumar B, Daum WJ, Siegel MA. Magnetic resonance imaging of the normal and ischemic femoral head. *AJR.* 1984;143:1273-1280. [PubMed] [Google Scholar]
- [7]. Comoni JM, Grossman RI, Goldberg HI, Zimmerman RA, Bilaniuk LT. Intracranial hematomas: imaging by high field MR. *Radiology.* 1985;157:87-93. [PubMed] [Google Scholar]
- [8]. Rupp VN, Reiser M, Hipp H, et al. The diagnosis of bone necrosis by magnetic resonance (MR) tomography: possible early diagnosis. *ROFO.* 1985;142:131-137. [PubMed] [Google Scholar]
- [9]. Collier BD, Carrera GF, Johnson RP, et al. Detection of femoral head avascular necrosis in adults by SPECT. *J Nucl Med.* 1985;26:979-987. [PubMed] [Google Scholar]
- [10]. Lee MH, Moon DH, Na HW. Diagnosis of femoral head avascular necrosis by triple head high resolution. *J Nucl Med.* 1992;33:936-941. [Google Scholar]

DR BUSHRA FARHEEN, et. al. "MRI Imaging features of avascular necrosis of femoral head in patients treated for COVID-19." *IOSR Journal of Dental and Medical Sciences (IOSR-JDMS)*, 21(08), 2022, pp. 60-64.