

# RhinocerebralMucormycosis: Our Institute Experience And Case Series

## Authors

1. DrGunjan Shah MDS(OMFS) associate professor dept of maxillofacial head neck surgery  
(Corresponding author )  
Email ghs\_48@yahoo.com
2. DrDharaShukla Shah resident dept of general medicine
3. Dr B D Mankad MD (medicine) professor dept of general medicine

---

## Abstract

*Introduction: Rhinocerebralmucormycosis (RCM) has been challenging infection specially occurring in diabetic and immunocompromised patients. Its clinical manifestation varies from mild cases to very severe fatal infection with toxemia and septicemia. Especially in the background of covid 19 RCM infections has increased drastically.*

*Aims and objectives: We are proposing novel grading system for RCM which can help to categorize these patients and provide systemic treatment guidelines as per their stage.*

*Patients and methods: 40 patients attended and managed by our team with diagnosis of RCM; we have classified them in to grade I to grade IV according to their clinical and radiological findings and as per their local or systemic symptoms.*

*Results: we could classify the patients and accordingly the treatment and approach could be planned. Prognosis can also be explained from their grades.*

**Key words:** *Rhinocerebralmucormycosis (RCM), diabetes, immunocompromised, covid 19, grading system*

---

Date of Submission: 17-10-2023

Date of Acceptance: 27-10-2023

---

## I. Introduction

Rhinocerebralmucormycosis (RCM) is rare opportunistic infection causing morbidity as well mortality in immunocompromised patients. It is also known as zygomycosis. It spreads rapidly in immunocompromised host and involves paranasal sinuses, midface bones as well orbit and brain. It is an acute fungal infection but it may also present as chronic occurrence that is indolent slowly progressing over several weeks.[1]

It is commonly found in patients with uncontrolled diabetes mellitus, HIV infection, steroid therapy burns, organ transplant, hemochromatosis, neutropenia, hematological malignancies. But the occurrence can also be there in absence of predisposing factors.[2] Recent pandemic of COVID 19 is found to be the major risk factor for RCM infection. As the triad of viral infection, steroid therapy and diabetes predisposes host for such opportunistic infection.

## II. Patients and methods

Permission form institutional ethical committee was taken before starting the study. Informed consent was taken from all patients as per declaration of Helsinki.

We have taken 40 patients attended by our team. Clinical examination was done followed by diagnostic swab for microbiological confirmation. In patients with negative swab but high clinical suspicion or chronic indolent cases biopsy was taken from palate to confirm diagnosis.

Patient with fever tachycardia and other toxic signs were advised immediate admission and supportive care with antifungal therapy was started.

Patients were then subjected to blood examination chest xray and ECG. Additional tests were done if required. Strict monitoring of blood sugar levels and electrolytes was done and short acting insulin was given subcutaneously or intravenous as per indication. Patients were subjected to plain CT scan and MRI of paranasal sinus area. Orbital cuts were added if indicated. Extension of disease was mapped on scans and from that they were divided into grades

From overall evaluation we had observed that all patients do not require radical approach while some must go for radical sequestrectomy to stop progression of disease. We hereby propose a grading system which helps to evaluate severity of disease so that we may plan treatment. This also helps to explain severity of the disease and know prognosis ie, higher the grade worse the prognosis. To add presence of B symptoms add to worse prognosis.

#### **A Symptoms: local symptoms**

Grade I: mild cases, no bone involvement, restricted only to mucosa

Grade II: moderate, small area of bone involved. Maxilla unilateral without involvement of orbital floor

Grade IIIa: severe cases with extensive involvement of uni/bilateral maxilla, and pan sinuses, extending to orbit without necrosis of orbital contents

Grade IIIb: with necrosis of orbital contents

Grade IV: very severe cases infection extending beyond orbit and skull base to cranial cavity

#### **B symptoms: systemic symptoms**

Presence of systemic symptoms like fever, raised total leukocyte counts, irritability, dyspnea, loss of consciousness

#### **Management guidelines**

Presence of B symptoms should be taken as priority and considered immediate admission and vital monitoring. All routine investigations should be carried out including hemogram, liver function tests, renal function tests, HIV, HbsAg, HCV antibodies. History of Covid 19 infection and severity should be taken including dose and duration of steroid therapy. Blood sugar monitoring must be done frequently and insulin should be started as per sliding scale. Ketoacidosis should be ruled out. Intravenous fluids should be administered as per requirements. Supportive antibiotic therapy should be started as per culture and sensitivity report. All other supportive therapy should be started.

Multispecialty team approach is needed for better care including physician, critical care physician, infectious disease specialist, maxillofacial surgeon, ENT surgeon, dentist, ophthalmologist, and neurosurgeon.

Nasal or palatal swabs should be collected for KOH smear to diagnose and confirm RCM. Imaging should be done in stable cases to know extent and spread of infection.

Intravenous amphotericinB should be started on early basis with strict monitoring of vital parameters.

Once patient is vitally stable A symptoms should be addressed and if B symptoms are absent early surgery is recommended. Patient should be assessed for general anesthesia per ASA grading. High risk consent should be obtained from all. Oral intubation and less use of IPPV are recommended to prevent spread to lower airway. Early surgery is recommended on priority basis to reduce fungal load and remove necrosed contents so that antifungal can penetrate better.

Grade I: transnasal endoscopic approach should be selected.

Grade II: transnasal endoscopic approach with correlation to endoscopic findings sequestrectomy may be considered.

Grade III: most of these patients present with exposed bone or pus discharge. Open per oral approach should be done, mucosal flaps should be raised to expose necrotic bone and all necrotic bone should be sacrificed along with curettage of sinus contents. Frontal and sphenoid sinus may be approached by endoscope.

Grade IV: after these patients become stable and few days of amphotericinB therapy early radical surgery is recommended. Per oral maxillectomy and removal of all necrosed contents is recommended. Exenteration of necrosed orbital contents should be considered.

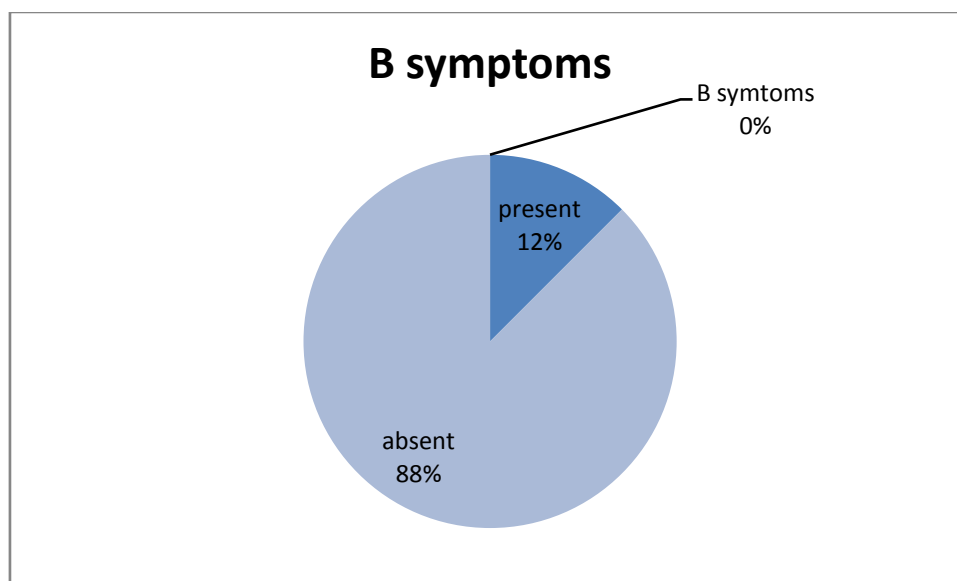
Final reconstruction must be delayed to assess outcomes. Primary mucosal suturing is always preferred whenever possible. In cases with mucosal defects palatal plates should be designed to prevent nasal regurgitation. Removal of naso-gastric tube should be done on earlier bases to avoid colonization around it. Temporalis flap is also being recommended by some authors; still we do not prefer to do primary reconstruction in RCM cases.

RCM presents to us in 2 ways: one is rapid fulminant way with severe systemic symptoms and second is chronic presentation with only local symptoms. So main aim of this grading is to judge severity of disease and explain about survival probabilities. This also explains whether to start with medical therapy or upfront surgery followed by antifungal therapy.

### **III. Results**

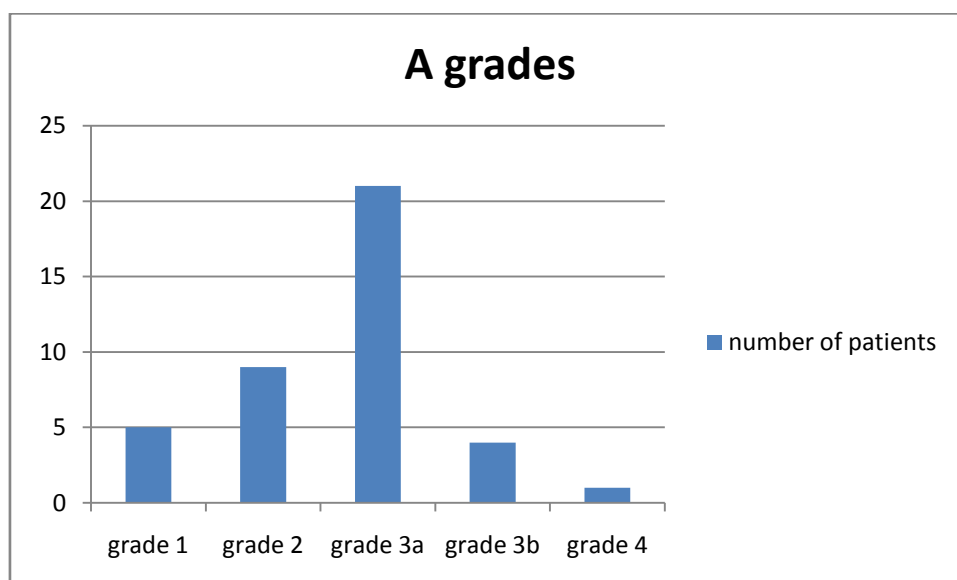
Out of 40 subjects 31 years was minimal age and 70 years was maximum age. 51.7 was average age. 15 patients were females and 25 patients were male. Diabetes was present in all patients. Grading were as per below table.

B symptoms	Present	Absent
Number of patients	5	35



A grades are as per table

grades	grade 1	grade 2	grade 3a	grade 3b	grade 4
number of patients	5	9	21	4	1



Patients presented to us with B symptoms were managed first by starting antifungal therapy. We have started liposomal amphotericin B in our patients. In those patients we had done surgery once they become hemodynamically stable. In 2 of our patients we had given amphotericin B lipid formulation due to non-availability. Rest all patients were managed by surgery first approach and antifungal therapy was given for 21 days as soon as culture reports were received within 3 to 5 days. Close monitoring of renal functions were done and dosage were adjusted if creatinine showed increasing trend. 5 of our patients did not complete post-operative antifungal therapy. In 10 of our patient from surgery first group amphotericin B was not given and managed by oral isavuconazole due to non-availability.

Form our series 1 patient had progression to intracranial area which was managed conservatively and antifungal therapy was given for prolonged period of 45 days. All our patients were followed up for 2 years

period. Radiological examinations MRI and plain CT scans were repeated after 3 months and 6 months and then if clinical suspicion present.

All of our patients had good response to therapy. On patient with intracranial extension is alive with intracranial disease which is stable and no progression was seen on post op radiological examination. Rest all our patients are free of disease.

#### **IV. Discussion**

RCM is invasive fungal infection caused by group of septate and aseptate filamentous fungi Mucoraceae family [1]. Mucormycosis is a general term for infections caused by a group of filamentous fungi belongs to the class Glomeromycetes, which has replaced the former class name Zygomycetes. In a review of more than 900 reported human cases of mucormycosis, Roden and colleagues found the majority of human mucormycosis cases were caused by fungi classified under the following genera [2]:

- Rhizopus (47%)
- Mucor (18%)
- Cunninghamella (7%)
- Apophysomyces (5%)
- Absidia species (5%)
- Saksenaea species (5%)
- Rhizomucorpusillus (4%)

Other genera belonging to Mucorales represented less than 3% of culture confirmed cases.

The first case of mucormycosis was described in 1885 by Paltauf, who created the term mycosis mucorina and later coined as Mucormycosis in 1957 by Baker[3]

Mucormycosis is primarily a disease of subjects with altered host defenses associated with the underlying conditions and predisposing factors such as diabetes mellitus, hematologic malignancies, chemotherapy, corticosteroid therapy, organ transplantation, and so on. Diabetic patients are predisposed to mucormycosis because of the decreased ability of their neutrophils to phagocytize and adhere to endothelial walls. High blood sugar level may also alter the ability of macrophages [4].

Infection occurs following inhalation of spores of Mucorales into the oral and nasal mucosa. Their germination is preferred by low oxygen, high glucose, acidic medium and high iron levels [5]

Importantly, DM has been the most common risk factor linked with mucormycosis in India, although hematological malignancies and organ transplant takes the lead in Europe and the USA [6]

From the recent studies it has been observed that uncontrolled blood sugar levels are most common factor associated with RCM, other factors seen along with covid 19 infections were steroid therapy, ramdesivir, tocilizumab, oxygen therapy in decreasing order [7].

Although mucormycosis is an extremely rare in healthy individuals but several immunocompromised conditions predispose it. This includes uncontrolled DM with or without DKA, hematological and other malignancies, organ transplantation, prolonged neutropenia, immunosuppressive and corticosteroid therapy, iron overload or hemochromatosis, deferoxamine or desferrioxamine therapy, voriconazole prophylaxis for transplant recipients, severe burns, acquired immunodeficiency syndrome (AIDS), intravenous drug abusers, malnutrition and open wound following trauma [8].

Patients usually present with symptoms like one sided headache, rhinorrhea, nasal congestion, hyposesthesia, epistaxis, facial pain, nasal discharge. Systemic symptoms like fever, lethargy, nausea may also be seen. Orbital symptoms include retro orbital pain, diplopia, blurring of vision. CNS involvement usually presents with convulsions, dizziness, altered mental status, and gait. Respiratory symptoms include difficulty in breathing, cough and hemoptysis [9].

High index of suspicion should be made in the existence of risk factors as clinical signs are nonspecific.

On examination signs of erythema on paranasal areas are evident and may be with swelling of cheek. Extra oral sinus may also be present with pus discharge. In severe cases blackening of skin of nose or cheek may also be present. On nasal examination black Escher may be visible with or without bleeding and blocked nose. All signs of sinusitis will be present. On oral examination foul smell with inflamed mucosa and discharge may be present. Loose teeth or mobile segment of bone may be seen. In chronic cases exposed necrotic bone may be evident. Orbital signs include proptosis with conjunctival chemosis. Altered or lost vision and ophthalmoplegia may also be present. Patients with neurological involvement may show neurological signs.

Imaging of choice is MRI for better soft tissue delineation and should be combined with plain CT cuts for better bony visualization. Orbit may be evaluated better by MRI. CT will show signs of sinusitis with present of sequestrum and fungal balls. MRI can show muscle edema and extension to skull base with neural involvement. Orbital collection and amount of necrosis in orbital cavity can also be evaluated. MRI at times may also show false positive results [10].

As the disease is aggressive, definitive therapy and a sequential plan of management is needed. Yet comprehensive clinical trial is required to confirm the unambiguous therapy and define optimal management strategies.

Primary first line antifungal monotherapy for mucormycosis should be based in polyenes. Amphotericin B deoxycholate (AmB) was the cornerstone of mucormycosis therapy for decades [11]; yet the use is now restricted due to availability of better molecules. Recent studies have shown that amphotericin B lipid formulations (ABL) are relatively less nephrotoxic and can be administered for a longer duration [12]. As per recent guidelines, treatment of mucormycosis with liposomal amphotericin B (LAmB) was associated with a 67% survival rate, compared to 39% survival when patients were treated with AmB ( $p=0.02$ ) so it is now preferred as initial therapy for RCM [13, 14]. Studies have shown advantages of LAmB over ABL for the treatment of CNS mucormycosis while ABL has better penetration in lung [15]. There is no definitive data on doses of polyene but 5–7.5 mg/kg/d of lipid polyenes are reasonable for most cases of mucormycosis. There is advantage of higher doses up to 10mg/kg/d for LAmB in CNS involvement. LAmB can be safely given up to higher doses without significant nephrotoxicity [16]. Duration of antifungal therapy is also debatable from 21 days to 50 days but for cases with CNS involvement need longer therapy with LAmB.

Fluconazole, voriconazole, and itraconazole do not have reliable activity against mucormycosis. posaconazole is also failed to show significant results as a first line therapy for RCM. Still, it may be used as salvage therapy for resistant cases or as step-down therapy [16-19].

There are many studies showing improved outcomes from combination therapy [20]. But if used in combination therapy then dose escalation is not recommended due to paradoxical loss of efficacy [21, 22]. Combination therapies of deferasirox and LAmB have shown 100 fold decreases in brain fungal burden and significantly superior outcomes [23]. The main problem associated with deferasirox therapy are nephrotoxicity yet exact pathogenesis is not clear [24]. Combination of posaconazole with polyenes has not shown any significant benefit in recent studies [25]. Role of colistin as antifungal agent was also studied but had failed to show any benefit in combination therapy [26].

Proinflammatory cytokines, such as interferon (IFN)- $\gamma$  and G-CSF was also used effectively in combination therapy; they enhance the ability of granulocytes to damage the fungus. Still their role in primary therapy is debatable yet for resistant cases and in neutropenic host they may be used as life saving agents [27, 28].

Hyperbaric oxygen therapy was also proposed and used for RCM [29].

Posaconazole, deferasirox and G-CSF may be used as salvage therapy in refractory cases with some benefits [19, 23, and 28].

The surgical management of RCM is either endoscopic debridement or open sequestrectomy. If there is presence exposed maxillary alveolus in oral cavity open approach is always preferred which saves time of anesthesia. After maxillary alveolus had been removed all the sinuses can be approached. If require endoscopic debridement may be combined with open sequestrectomy. All the bones should be removed till active bleeding is seen from fresh margins. After thorough wash cavity should be packed with antral pack that should be removed within 48 hours. [1, 3, 7]

## V. Conclusion

In present study the purpose of grading system is depending upon symptoms and severity local or systemic and management guidelines as per the stage of involvement; which is quite simple for Indian subcontinent as well may be used globally.

## References

- [1]. Rasoul Mohammadi, Mehdi Nazeri, Sayed Mohammad Amin Sayedayn, and Hassan Ehteram. A successful treatment of rhinocerebral mucormycosis due to *Rhizopusoryzae*
- [2]. Infectious Diseases Agents of Mucormycosis (Microbiology) Res Med Sci. 2014 Jan;19(1): 72–74.
- [3]. Prabhu Rm, Patel R. Mucormycosis and entomophthoromycosis: A review of the clinical manifestations, diagnosis and treatment. Clin Microbiol Infect. 2004;10:31–47.
- [4]. Ammari L, Kilani B, Tiouiri H, Kanoun F, Goubontini A, Mnif E, et al. Mucormycosis: Four case reports. La Tunisie Med. 2008;86:165–8.
- [5]. Peleg AY, Weerathna T, McCarthy JS, Davis TM. Common infections in diabetes: Pathogenesis, management and relationship to glycaemic control. Diabetes Metab Res Rev. 2007;23:3–13. [PubMed]
- [6]. Alan MS. Mucormycosis. Clin Infect Dis. 1992;14:126–9
- [7]. Prakash H., Chakrabarti A. Global epidemiology of mucormycosis. J Fungi. 2019;5:26.
- [8]. Awadhesh Kumar Singh, Ritu Singh, Shashank R. Joshi, and Anoop Misra. Mucormycosis in COVID-19: A systematic review of cases reported worldwide and in India. Diabetes Metab Syndr. 2021 July-August;15(4):102-146.
- [9]. Sugar A.M. Mucormycosis. Clin Infect Dis. 1992;14:S126–S129.
- [10]. Rhinocerebral Mucormycosis Jenish Bhandari; Pawan K. Thada; Shivaraj Nagalli. StatPearls [Internet].
- [11]. Mnif N, Hmaied E, Oueslati S, Rajhi H, Hamza R, Marrakchi M, Kaffel N, Kooli H, Ben Salah M, Ferjaoui M. [Imaging of rhinocerebral mucormycosis]. J Radiol. 2005;86(9):1017-20.

- [12]. Reed C, Bryant R, Ibrahim AS, et al.: Combination polyene-caspofungin treatment of rhino-orbital-cerebral mucormycosis. *Clin Infect Dis* 2008;47:364–371
- [13]. Thomas J, Walsh, John W, Hiemenz, Nita L, Seibel et al Amphotericin B Lipid Complex for Invasive Fungal Infections: Analysis of Safety and Efficacy in 556 Cases. *Clinical Infectious Diseases* 1998;26:1383–96
- [14]. Gleissner B, Schilling A, Anagnostopoulos I, et al. Improved outcome of zygomycosis in patients with hematological diseases? *Leuk Lymphoma*. 2004;45:1351–1360
- [15]. Ruping MJ, Heinz WJ, Kindo AJ, et al. Forty-one recent cases of invasive zygomycosis from a global clinical registry. *J Antimicrob Chemother*. 2010;65:296–302
- [16]. Cornely OA, Maertens J, Bresnik M, et al. Liposomal amphotericin B as initial therapy for invasive mold infection: a randomized trial comparing a high-loading dose regimen with standard dosing (AmBiLoad trial) *Clin Infect Dis*. 2007;44:1289–1297
- [17]. Sun QN, Fothergill AW, McCarthy DI, et al. In vitro activities of posaconazole, itraconazole, voriconazole, amphotericin B, and fluconazole against 37 clinical isolates of zygomycetes. *Antimicrob Agents Chemother*. 2002;46:1581–1582.
- [18]. Trifilio SM, Bennett CL, Yarnold PR, et al. Breakthrough zygomycosis after voriconazole administration among patients with hematologic malignancies who receive hematopoietic stem-cell transplants or intensive chemotherapy. *Bone Marrow Transplant*. 2007;39:425–429.
- [19]. Ullmann AJ, Cornely OA, Burchardt A, et al. Pharmacokinetics, safety, and efficacy of posaconazole in patients with persistent febrile neutropenia or refractory invasive fungal infection. *Antimicrob Agents Chemother*. 2006;50:658–666
- [20]. Greenberg RN, Mullane K, van Burik JA, et al. Posaconazole as salvage therapy for zygomycosis. *Antimicrob Agents Chemother*. 2006;50:126–133
- [21]. Reed C, Bryant R, Ibrahim AS, et al.: Combination polyene-caspofungin treatment of rhino-orbital-cerebral mucormycosis. *Clin Infect Dis* 2008;47:364–371.
- [22]. Ibrahim AS, Bowman JC, Avanesian V, et al. Caspofungin inhibits Rhizopusoryzae 1, 3-beta-D-glucan synthase, lowers burden in brain measured by quantitative PCR, and improves survival at a low but not a high dose during murine disseminated zygomycosis. *Antimicrob Agents Chemother*. 2005;49:721–727.
- [23]. Ibrahim AS, Gebremariam T, Fu Y, et al. Combination echinocandin-polyene treatment of murine mucormycosis. *Antimicrob Agents Chemother*. 2008;52:1556–1558. doi: 10.1128/AAC.01458-07.
- [24]. Reed C, Ibrahim A, Edwards JE, Jr, et al. Deferasirox, an iron-chelating agent, as salvage therapy for rhinocerebralmucormycosis. *Antimicrob Agents Chemother*. 2006;50:3968–3969.
- [25]. US Food and Drug Administration: Important information about Exjade (deferasirox) tablets for oral suspension (Novartis, 2007). Available at <http://www.fda.gov/downloads/Safety/MedWatch/SafetyInformation/SafetyAlertsforHumanMedicalProducts/UCM154395.pdf>. Accessed June 2010.
- [26]. Ibrahim AS, Gebremariam T, Schwartz JA, et al. Posaconazole mono- or combination therapy for murine mucormycosis. *Antimicrob Agents Chemother*. 2009;53:772–775.
- [27]. Ben-Ami R, Lewis RE, Tarrand J, et al. Antifungal activity of colistin against mucorales species in vitro and in a murine model of Rhizopusoryzae pulmonary infection. *Antimicrob Agents Chemother*. 2010;54:484–490.
- [28]. Abzug MJ, Walsh TJ. Interferon-gamma and colony-stimulating factors as adjuvant therapy for refractory fungal infections in children. *Pediatr Infect Dis J*. 2004;23:769–773.
- [29]. Grigull L, Beilken A, Schmid H, et al. Secondary prophylaxis of invasive fungal infections with combination antifungal therapy and G-CSF-mobilized granulocyte transfusions in three children with hematological malignancies. *Support Care Cancer*. 2006;14:783–786.
- [30]. John BV, Chamilos G, Kontoyiannis DP. Hyperbaric oxygen as an adjunctive treatment for zygomycosis. *ClinMicrobiol Infect*. 2005;11:515–517.