

Tensor Fascia Lata Flap – A Prophylactic Option Following Groin Dissection In Carcinoma Penis

Suresh Kumar D¹, Balamurugan T D^{*}, Prasanna Srinivasa Rao H²,
Ajay Kumar A³

¹Professor, Department of Surgical Oncology, Govt Arignar Anna Memorial Cancer Hospital and Research Institute -Regional Cancer Centre, Karapettai, Kanchipuram, Tamilnadu, India

^{*}Corresponding author – Assistant Professor, Department of Surgical Oncology, Govt Arignar Anna Memorial Cancer Hospital and Research Institute -Regional Cancer Centre, Karapettai, Kanchipuram, Tamilnadu, India

² Assistant Professor, Department of Surgical Oncology, Govt Arignar Anna Memorial Cancer Hospital and Research Institute -Regional Cancer Centre, Karapettai, Kanchipuram, Tamilnadu, India

³ Post-Graduate, Department of Surgical Oncology, Govt Arignar Anna Memorial Cancer Hospital and Research Institute -Regional Cancer Centre, Karapettai, Kanchipuram, Tamilnadu, India

ABSTRACT

BACKGROUND – Groin dissection is an essential part in management of carcinoma penis. Either immediate or delayed dissection, the wound morbidity is so high and many measures taken historically to decrease the morbidity is not much of use.

OBJECTIVE – our objective is to compare the operative characteristics and post op morbidity between primary closure and Tensor Fascia Lata flap cover following groin dissection in carcinoma penis cases

METHODS – we did a retrospective study from January 2020 to December 2022 (data taken from our cancer registry) which included carcinoma penis cases.

RESULTS – Around 34 patients were included for analysis, of which 23 patients underwent primary closure and 11 patients underwent TFL flap cover. Ilio-inguinal dissection is the common procedure done in both the groups. Inguinal dissection is only done in 2 patients of primary closure group. The mean surgery duration is high among TFL flap group (184 minutes) compared to primary closure group (156 minutes) with a p-value = 0.003. Post-operative complications like minor flap/skin necrosis (34.7% vs 9%), wound dehiscence (43.4% vs 18.1%) and seroma (21.7% vs 9%) are higher in primary closure group than TFL flap group which is statistically significant. The rates of wound infection are equal in both the groups.

CONCLUSION – To decrease morbidity following groin dissection in carcinoma penis, TFL flap can be used prophylactically instead of primary closure.

KEYWORDS – Tensor Fascia Lata, groin, penis, primary closure and morbidity

Date of Submission: 17-10-2023

Date of Acceptance: 27-10-2023

I. INTRODUCTION

Groin dissection in carcinoma penis is for both diagnostic staging and therapeutic cure. It is approached by various incisions based on patient and surgeon factors. Whatever the type of incision, the wound morbidity rates are in the range of 50-60% (1) (2), and often affects the quality of life in post operative period and also delays adjuvant treatment if needed. Complicated wounds are slowly healing and are frequently exposed to femoral vessels exposing them for further dreadful complications. Neglected and unchecked metastatic inguinal nodes lead to fixed and fungating lesions. These lesions are treated by en-bloc resection along with skin and the resultant defect is closed by myo-cutaneous flaps. The various flaps used are Tensor Fascia Lata flap, Antero-Lateral Thigh flap, Vertical Rectus Abdominis Myo-cutaneous flap, etc (3).

Flaps are used for fungating nodes or for post-op wound gaping. There is no prospective trial which gives evidence to use prophylactic use of flaps after groin dissection. The prophylactic use of flaps is rarely performed (4). Back in 1934, Tensor Fascia Lata Flap (TFL) was first described and later studied in detail by Nahai and his co-workers in 1978-1979 (5).

The TFL flap can be used as both free and pedicled flap (6). The advantages of TFL flap are the anatomy is more constant, dissection can be made through the same incision without causing much donor site morbidity. It can be made thin removing variable portions of muscle and also gives us good volume of skin. Perforators are almost always present, and their pedicles are of sufficient length (6). As a perforator flap, a thinner and more

pliable flap can be obtained, removing a variable portion of muscular tissue and leaving only a cuff around the pedicle (6).

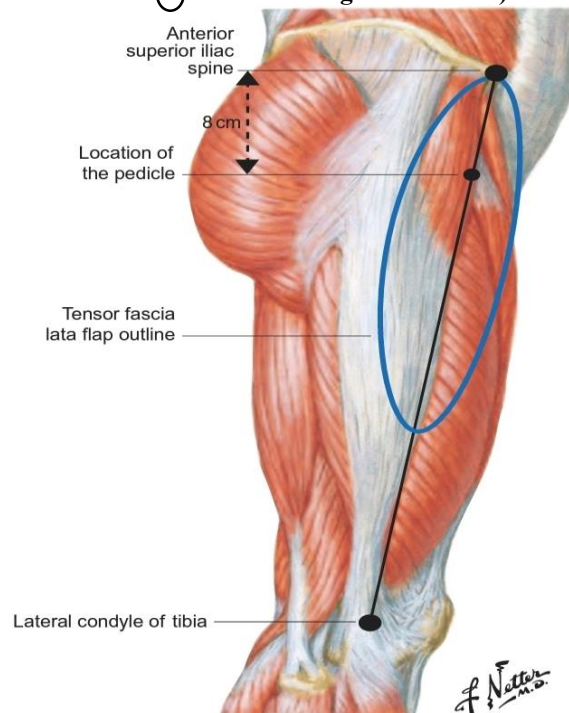
So, we did a retrospective study comparing the morbidities following primary closure and TFL flap for groin dissection in Node positive carcinoma penis patients.

ANATOMY AND TECHNIQUE OF TFL FLAP

The TFL muscle has a single dominant pedicle (Mathes & Nahai type I muscle) which sends musculocutaneous perforators to supply the overlying skin (6). The pedicle is the transverse branch of lateral circumflex femoral artery (6). The lateral circumflex femoral artery invariably originates from the lateral side of the deep branch of the femoral artery 8–10 cm inferior to the anterior superior iliac spine (6). The transverse branch supplies the TFL muscle, entering the anteromedial belly of the muscle 8–10 cm inferior to the anterior superior iliac spine (ASIS) (6). The external diameter of the vessel is approximately 2–3 mm at its origin. Measured from its origin to the vascular hilus of the TFL muscle, the average length of the vascular pedicle is 4–6 cm in adults (6).

The flap design is illustrated in figure-1. The anterior border of the muscle is marked from ASIS to lateral condyle of the tibia. The vascular pedicle enters 8-10 cm below the ASIS and enters from medial aspect (6). The posterior border is marked from greater trochanter and the length of posterior border is extended as required (7). The standard flap length is 20 x 10 cm (7). skin and sub cutaneous tissue incised at its anterior border. Fascia lata identified and incised and the incision is extended in an inferior direction toward the knee. The fascia lata is released from its aponeurotic insertion and the dissection is carried over the posterior border (figure-2). The flap is elevated from its distal aspect and the vascular pedicle is identified at its proximal part at its landmark as already described. Flap is then rotated medially and inset done to cover the groin defect (figure-3). Primary closure is usually done for donor site. Rarely, if the defect is large it may need split skin graft.

Fig.1 TFL FLAP ANATOMY AND OUTLINE (Reprinted from Netter Anatomy Illustration Collection C Elsevier Inc. All Rights Reserved)



II. MATERIALS AND METHODS

Study population

A hospital-based gathering of retrospective data of the patients diagnosed with non-metastatic Carcinoma Penis from a Regional Cancer Centre of Tamil Nadu from January 2020 to December 2022 (data taken from our cancer registry). Patient variables and information related to age, occupation, clinical and pathological details, treatment details including the type of surgery are taken for study. We identified 34 patients eligible for our analysis. All patients underwent either inguinal or ilio-inguinal lymph node dissection. Classical inguinal lymphadenectomy is done for all patients. Iliac lymph node dissection done is done by extra-peritoneal approach. Open dissection done for all patients and standard dissection procedures were followed. After nodal dissection,

whether to do primary closure or TFL flap reconstruction is based upon the surgeon's choice and defect size. Figure 2 and 3 shows TFL flap harvest and TFL rotation into the defect. No specific criteria were followed for this decision. Drains were placed for all patients and they are removed when the output is less than 30 ml for 2-3 consecutive days. In our study, 23 patients underwent primary closure and 11 patients underwent TFL flap cover. For patients with TFL flap cover, primary closure of the donor site is done for 10 patients and only one patient required split skin graft. All patients were under antibiotic coverage both pre-operatively and post-operatively.

Fig.2 TFL FLAP HARVEST

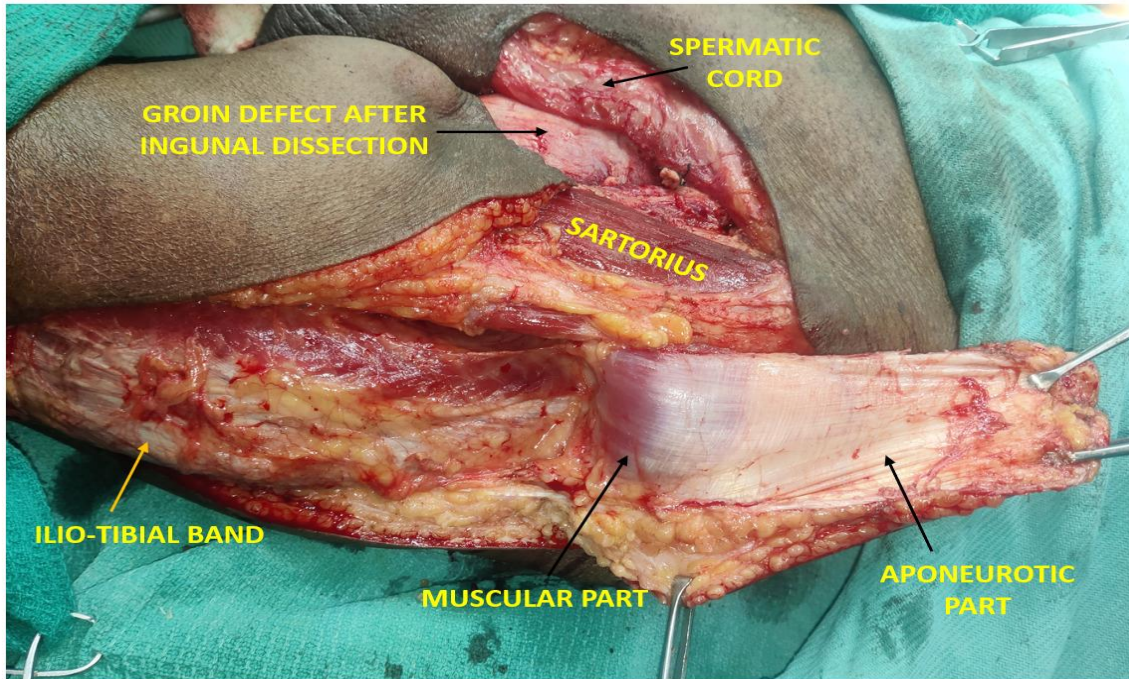
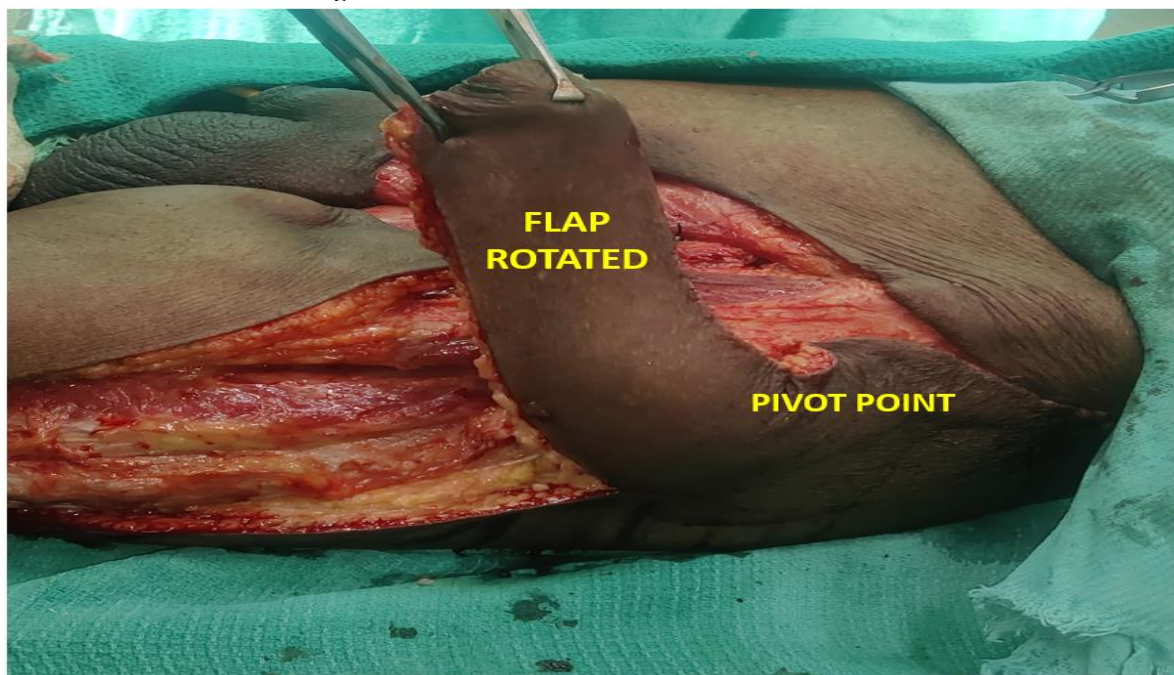


Fig. 3 TFL FLAP ROTATION AND FLAP INSET



Operative factors such as surgery duration, blood loss and post op stay duration is compared between both the groups. Post operative morbidities like wound infection, flap/skin necrosis (major and minor), wound dehiscence and seroma were compared between both the groups. Major necrosis is defined as >10% of the total

surface area and minor necrosis is <10%. Seroma collection is assessed either clinically or by ultrasound local part.

Statistical analysis

Operative factors and post operative morbidities were compared between both the groups and P-values are calculated using fisher’s test and chi-square test.

III. RESULTS

Out of 34 patients, 23 patients had primary closure and 11 patients had TFL flap cover. Various patient characteristics are illustrated in Table-1. Only one patient had bilateral TFL flap and all others had unilateral flap. Age distribution is equal among both the groups. Most common age group affected is 41-60 years. Around, 56% (n=13) of patients in primary closure group belong to 41-60 years and 54% (n=6) of patients in TFL flap group belongs to 41-60 years. With regards to occupation, unskilled labourers predominate in both primary closure group (74%) and TFL flap group (63.7%).

Ilio- inguinal dissection is the most common procedure done in both the groups. Inguinal dissection done in only 2 patients of primary closure group. In primary closure group, stage III B (34.8%) predominates than stage III A (30.5%) and stage IV (26%). Only 2 cases with delayed nodal recurrence (recurrence after primary penile surgery >6 months done elsewhere) underwent primary closure. In TFL flap group, stage IV patients (45.6%) are more common than stage IIIB (36.5%) and stage IIIA (9%). Only one patient with delayed nodal recurrence underwent TFL flap cover. Around 13% patients had neo-adjuvant chemotherapy followed by surgery in primary closure group and 36.4% in TFL flap group.

TABLE. 1: Patient Characteristics

VARIABLES		PRIMARY CLOSURE (n= 23) (percentage)	TFL FLAP (n=11) (percentage)
AGE	21-40	3 (13%)	1 (9%)
	41-60	13 (56.5%)	6 (54.5%)
	>60	7 (30.5%)	4 (36.5%)
OCCUPATION	UNSKILLED LABOURER	17 (74%)	7 (63.7%)
	SKILLED LABOURER	5 (22%)	3 (27.3%)
	PROFESSIONAL AND OTHERS	1 (4%)	1 (9%)
CLINICAL STAGE	STAGE III A (N1 disease)	7 (30.5%)	1 (9%)
	STAGE III B (N2 disease)	8 (34.8%)	4 (36.5%)
	STAGE IV (N3 disease)	6 (26%)	5 (45.6%)
	DELAYED NODAL RECURRENCE (after primary penile surgery)	2 (8.7%)	1 (9%)
TYPE OF DISSECTION	Inguinal Dissection	2 (8.7%)	0
	Ilio- Inguinal Dissection	21 (91.3%)	11 (100%)
NEO-ADJUVANT CHEMOTHERAPY	Yes	3 (13%)	4 (36.4%)
	No	19 (83%)	7 (63.6%)

We also compared operative factors among both the groups (TABLE-2). The mean surgical duration is 154 minutes for primary closure group and 186 minutes for TFL flap group which is statistically significant between both the groups. The mean blood loss is 180 ml for primary closure group and 200 ml for TFL flap group. The mean duration of hospital stay is 5 days (+/- 2 days) for primary closure group and 6 days (+/- 3 days) for TFL flap group. Other two factors like mean blood loss and mean duration of hospital stay are statistically not significant between both the groups. Figure-4 and 5 shows pre-operative and post-operative pictures of TFL flap cases respectively.

Fig.4 PRE-OPERATIVE PICTURES OF TFL FLAP CASES
(Image- A showing right inguinal nodal involvement and Image-B showing left inguinal nodal involvement)

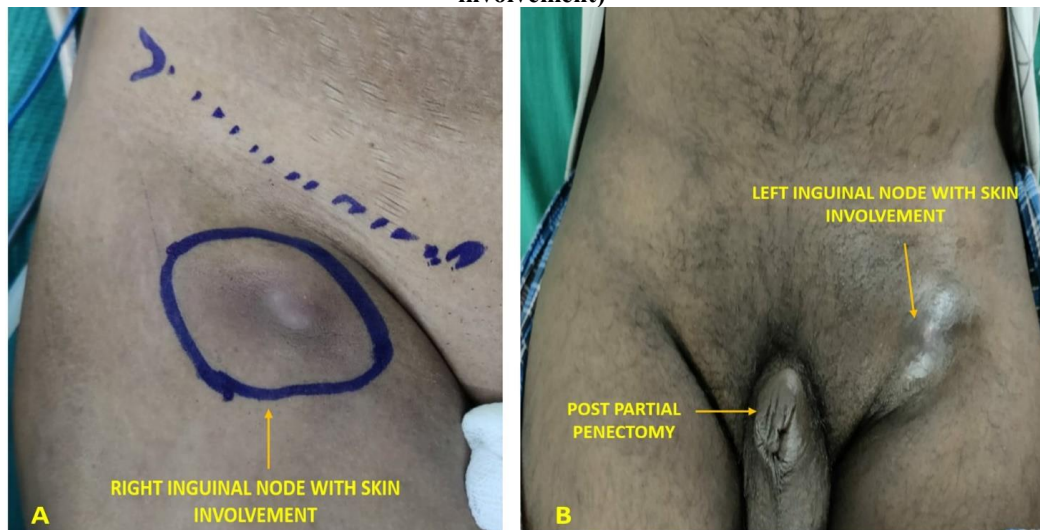


Fig.5 POST-OPERATIVE PICTURES OF TFL FLAP CASES
(Image-A showing Right TFL flap, Image-B showing Left TFL flap)

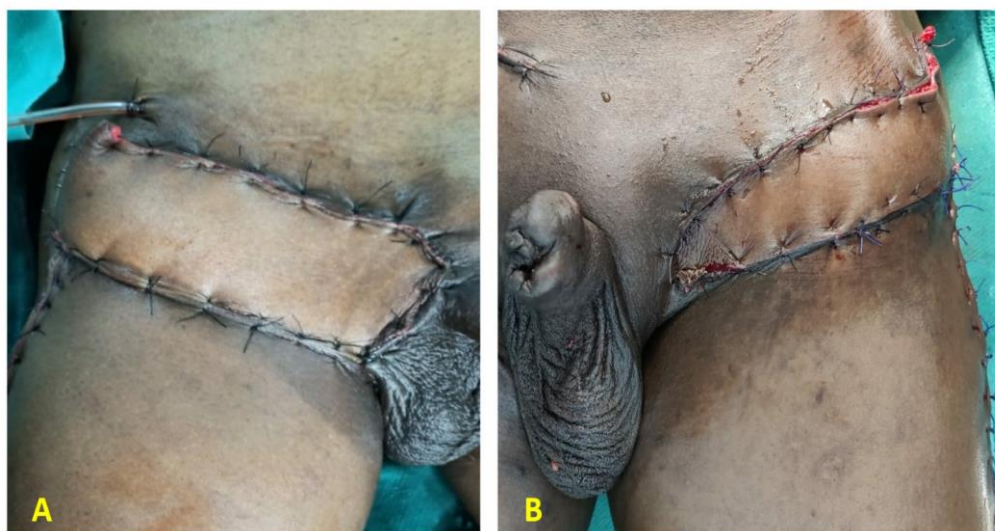

TABLE.2: OPERATIVE CHARACTERISTICS

OPERATIVE PARAMETERS	PRIMARY CLOSURE (n=23)	TFL FLAP (n=11)	P- value
MEAN SURGERY DURATION (MINS)	154 minutes	186 minutes	0.003
MEAN BLOOD LOSS (ML)	180 ml	200ml	0.7
MEAN DURATION OF HOSPITAL STAY (DAYS)	5 days (+/- 2 days)	6 days (+/- 3 days)	1.1

MORBIDITY

The post op complications and their frequency are enlisted in TABLE 3. Wound infection occurred in 17.3% patients in groins of primary closure group and 18.1% patients in TFL flap group which is not statistically significant (p- value = 1.2). With regards to minor flap/skin necrosis it is higher among primary closure group (34.7%) compared to 9% in TFL flap group which is statistically significant (p=0.018). only one patient had major skin necrosis in primary closure group. Two patients in primary closure group required split skin graft as second surgery for wound healing and others healed with conservative treatment. Wound dehiscence is more common in primary closure group (43.4%) than TFL flap group (18.1%) with a significant p-value. Similarly, seroma is common in primary closure group than TFL flap group (21.7% vs 9%). Seromas are managed by reinsertion of drains and by percutaneous aspiration under ultrasound guidance. Lymphedema is equal in both the groups. Three

patients (13%) in primary closure group and 2 patients (18.2%) in TFL flap group developed lymphedema which is not statistically significant. All these patients are managed conservatively by compression stockings.

TABLE 3: POST-OP COMPLICATIONS

COMPLICATIONS	PRIMARY CLOSURE		TFL FLAP		P- value
	n=23	Percentage	n=11	Percentage	
Minor flap/skin necrosis	8	34.7%	1	9%	0.018
Major flap/skin necrosis	1	4.3%	0	---	---
Wound infection	4	17.3%	2	18.1%	1.2
Wound dehiscence	10	43.4%	2	18.1%	0.03
Seroma	5	21.7%	1	9%	0.046

IV. DISCUSSION

Morbidity has always been a greater factor in deciding groin management in carcinoma penis. There has been controversies and many old studies comparing immediate versus delayed lymphadenectomy in carcinoma penis (8). The pendulum has moved towards earlier lymphadenectomy given that nodal dissection can cure metastatic penile cancer, why is there debate about whether the procedure should be performed or not. Although treatment of primary tumour and a period of antibiotics are useful to sterilize the inguinal region, this practice is no longer advocated as a tool to select patients who either should not undergo lymphadenectomy. Most of the centers started doing immediate inguinal lymphadenectomy and what is now more problematic is the morbidities associated with inguinal dissections. The morbidity rates especially the skin necrosis varies with many studies. It can be as low as 8% in a study by Bevan Thomas et al (9) to as high as 61% by Ravi (1). It depends upon various factors like the type of incision, length of incision, plane in which flaps are raised and the approach in which it is done (open or minimally invasive). Various studies concentrated on decreasing post operative complications by improving preoperative and post operative care (2) (9) (10) (11). Modified template Inguinal Dissection which uses a shorter incision, preservation of saphenous vein, limiting the field of dissection and preserving scarpa's fascia has been practiced to decrease morbidity (10) (11). Also, myo-cutaneous flaps have been used after groin dissections to cover the defect and to decrease the morbidity (3) (12). The tensor fascia lata flap (TFL) is one of the most commonly used flap for groin reconstruction after nodal dissection which has shown excellent results with minimal morbidity (7) (13).

TFL flap and its versatility for groin reconstruction has been a well-known fact, but to use prophylactically to decrease morbidity has not been prospectively studied till date. Our retrospective study aimed to compare the morbidities following primary closure group and TFL flap group after groin dissection. In our study, the minor skin necrosis is seen in 35% of cases in primary closure group which is little less than other studies but comparable (1) (2) (7). But minor flap necrosis is seen in only 9% of cases in TFL flap group which is significant difference. This is probably due to well vascularized flap which is properly harvested and sutured without tension which in turn decreases wound morbidity (3) (13) (14). None of the patients in our study had major flap necrosis in TFL flap group. Wound infection rates are similar in both the groups. We also found that wound dehiscence is more common in primary closure group than TFL flap group (43.4% vs 18.1%). This is due to increased incidence of skin necrosis in primary closure group which in turn lead to more wound dehiscence rates. Wound dehiscence is managed by conservative treatment and if needed secondary skin suturing done. Two patients in primary closure group and one patient in TFL flap group needed secondary suturing of skin. Our study also showed seroma rates are higher in primary closure group. The seroma rates are comparable with studies done by Ravi (1), Nelson et al (2) and Nirmal et al (7). This finding is probably due to the fact that using flaps after groin dissection may obliterate the dead space and decreases the chance of seroma formation (1). In our study, lymphedema rates are equal in both the groups which conveys us, the type of closure doesn't affect lymphatic drainage and it is the extent of lymph node dissection which affects it.

All these findings from our study suggests us TFL flap is associated with lower wound morbidity rates with negligible donor site morbidity. This is studied in detail by Ravi and published in 1993 itself which explains us flap reconstruction after ilio-inguinal dissection is associated with 100% primary wound healing rates (1). Also, study by Nirmal et al yielded similar results like our study and quoted the importance and use of TFL flap prophylactically after groin dissection (7). In spite of all these findings, there is general inhibition to use TFL flap prophylactically by Onco-surgeons and Genito-Urinary surgeons. Even though, we had limitations like small number and retrospective study design and also increased operative time for TFL flap group, we suggest using TFL flap prophylactically following groin dissection to lower wound morbidity.

V. CONCLUSION

Tensor fascia lata flap is associated with lower wound morbidity after groin dissection in Carcinoma Penis than primary closure group. We advise to harvest and use TFL flap Prophylactically after groin dissection especially after Ilio-Inguinal dissection to improve wound healing rates. Our study also opens the gateway to start randomized controlled trials and confirm these findings so that it will be practiced in all cancer centres to get better results and quality of life in near future.

VI. CONFLICTS OF INTEREST

The authors declare that they have no conflicts of interest to disclose

The authors declare that the research was conducted in the absence of any commercial or financial relationships that could be construed as a potential conflict of interest. The authors have no relevant financial or non-financial interests to disclose.

VII. FUNDING

The authors declare that no funds, grants, or other support were received during the preparation of this manuscript.

VIII. ETHICS COMMITTEE

CONSENT - For this type of study formal consent is not required.

This is a retrospective study. The Research Ethics Committee has confirmed that no ethical approval is required.

REFERENCES:

- [1]. Ravi R (1993). Morbidity Following Groin Dissection For Penile Carcinoma. *British Journal Of Urology*; 72:941
- [2]. Nelson BA, Cookson MS, Smith Jr JA, Chang SS (2004). Complications Of Inguinal And Pelvic Lymphadenectomy For Squamous Cell Carcinoma Of The Penis: A Contemporary Series. *The Journal Of Urology*; Aug;172(2):494-7
- [3]. Murthy V, Gopinath KS (2012). Reconstruction Of Groin Defects Following Radical Inguinal Lymphadenectomy: An Evidence-Based Review. *Indian Journal Of Surgical Oncology Jun*;3(2):130-8.
- [4]. Abraham V, Ravi R, Shrivastava BR (1992). Primary Reconstruction To Avoid Wound Breakdown Following Groin Block Dissection. *British Journal Of Plastic Surgery*; Apr;45(3):211-3.
- [5]. Nahai F, Hill HL, Hester TR (1979). Experiences With The Tensor Fascia Lata Flap. *Plastic And Reconstructive Surgery*; Jun;63(6):788-99
- [6]. Özkan, Ömer & Coskunfirat, O Koray (2009). Tensor Fascia Lata Flap. *Flaps And Reconstructive Surgery*. 561-576.
- [7]. Nirmal TJ, Gupta AK, Kumar S, Devasia A, Chacko N, Kekre NS (2011). Tensor Fascia Lata Flap Reconstruction Following Groin Dissection: Is It Worthwhile? *World Journal Of Urology*; Aug;29(4):555-9.
- [8]. Mukamel E, Dekernion JB (1987). Early Versus Delayed Lymph-Node Dissection Versus No Lymph-Node Dissection In Carcinoma Of The Penis. *Urology Clinics Of North America*; Nov;14(4):707-11.
- [9]. Bevan-Thomas R, Slaton JW, Pettaway CA (2002). Contemporary Morbidity From Lymphadenectomy For Penile Squamous Cell Carcinoma: The M. D. Anderson Cancer Center Experience. *The Journal Of Urology*; Apr;167(4):1638-42.
- [10]. Catalona WJ (1988). Modified Inguinal Lymphadenectomy For Carcinoma Of The Penis With Preservation Of Saphenous Veins: Technique And Preliminary Results. *The Journal Of Urology*; Aug;140(2):306-10.
- [11]. Coblenz TR, Theodorescu D (2002). Morbidity Of Modified Prophylactic Inguinal Lymphadenectomy For Squamous Cell Carcinoma Of The Penis. *The Journal Of Urology*; Oct;168(4 Pt 1):1386-9.
- [12]. Prakash S (1982). The Use Of Myocutaneous Flaps In Block Dissections Of The Groin In Cases With Gross Skin Involvement. *British Journal Of Plastic Surgery*; Oct;35(4):413-9
- [13]. Gopinath KS, Chandrashekhar M, Kumar MV, Srikant KC (1988). Tensor Fasciae Latae Musculocutaneous Flaps To Reconstruct Skin Defects After Radical Inguinal Lymphadenectomy. *British Journal Of Plastic Surgery*; Jul;41(4):366-8
- [14]. Hubmer MG, Justich I, Haas FM, Koch H, Parvizi D, Feigl G, Prandl E (2011). Clinical Experience With A Tensor Fasciae Latae Perforator Flap Based On Septocutaneous Perforators. *Journal Of Plastic, Reconstructive And Aesthetic Surgery*; Jun;64(6):782-9