

Inadvertent Bleb With Corneal Infiltrate Following Sutureless Cataract Surgery

Dr Nadhna Basheer , Dr. Prabhu Vijayaraghavan
Sankara Eye Hospital, Coimbatore, TN,India

Summary

A case of a 48 yr old gentleman, who presented with corneal infiltrate in front of a bleb 2 month following manual small incision cataract surgery. The patient did not give any history or trauma or any dust entry. It was diagnosed to be post cataract filtering bleb with associated corneal infiltrate. This case highlights the need for delayed resuturing of inadvertent bleb following cataract surgery to reduce the risk for intraocular complication.

Key words: bleb following cataract surgery , corneal infiltrate associated with bleb, sutureless cataract surgery, manual small incision cataract surgery.

Date of Submission: 06-11-2023

Date of Acceptance: 16-11-2023

I. Case Report

A 48-year-old male patient, manual labourer who came to us with complaints of swelling in his left eye for 2 months after cataract surgery with posterior chamber lens implantation. He noticed the swelling 1 week following surgery and it gradually increased in size. There was mild irritation associated with the swelling. There was no history of trauma or any prior history of glaucoma surgery. He was using oflacin with dexamethasone combination eye drops as routine post operative regimen. 3 days prior to his visit he noticed whitish discoloration in front of the swelling.

On examination the BCVA was 6/24 , there was vertically oval cystic to firm , non tender swelling with of size 3x6 mm (figure 1) in the temporal limbus near the corneoscleral section. An anterior stromal corneal infiltrate of size 2x 2 mm was present in front of the swelling. The ocular movements and dilated fundus examination were unremarkable. The intraocular pressure was 14 mmHg and 16 mmHg in the right and left eyes, respectively, by rebound tonometry recorded during the morning hours. Siedel's test was negative and Anterior chamber was well formed.

Under strict aseptic conditions peribulbar anaesthesia despite a careful dissection of cyst , the cyst wall ruptured and excised .The tunnel was sutured with 10-0 nylon and the overlying conjunctiva was closed with 8-0 vicryl. Postoperatively a topical oflacin and 0.1% dexamethasone sodium phosphate combination eye drop were prescribed in tapering doses. On postoperative day 1, filtering bleb in the left eye was absent [Figure - 2]a, the wound was well apposed; Seidel's test was negative, and the IOP was 10 mmHg. The infiltrate in front of the bleb resolved after using topical antibiotics and lubricants for 2 weeks. At follow up of 2 months postop he had a BCVA of 6/9 , there was no recurrence of bleb , section was well apposed and the corneal anterior stromal scar was present at the temporal limbus .

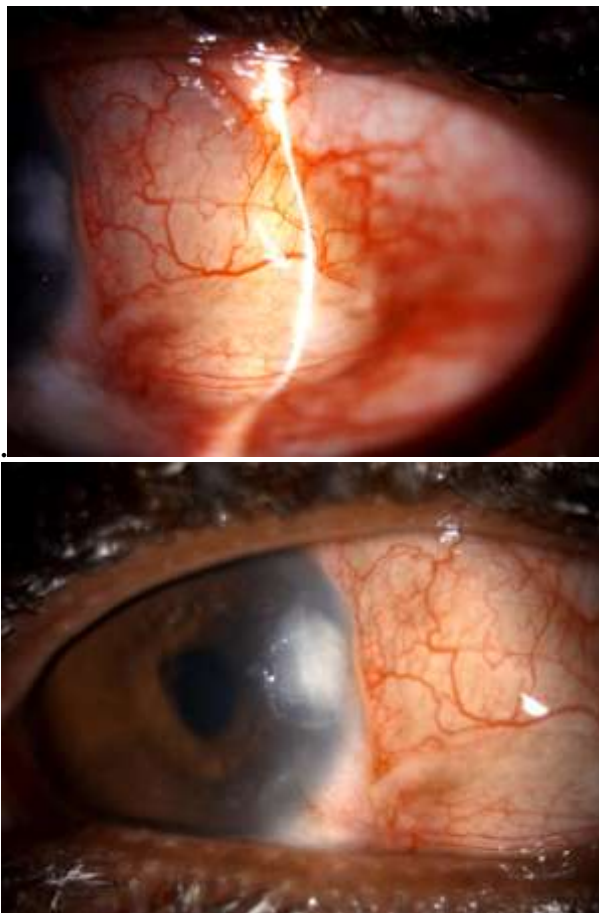


Fig 1a Bleb seen over the temporal limbus of the left eye, **Fig 1b** corneal infiltrate seen in front of the bleb

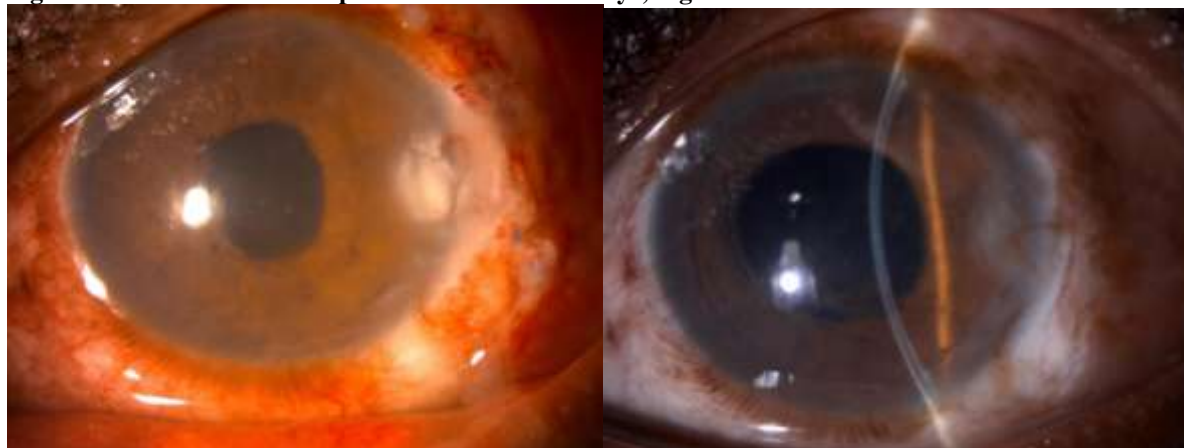


Fig 2a Immediate post op after cyst excision and section suturing **fig 2b** 2 months post op with ant stromal scarring and no recurrence of the bleb

II. Discussion

Unintended bleb formation after following manual small incision cataract surgery is not uncommon. The reported incidence of bleb formation after manual small incision cataract surgery was 1% to 7.7%(1). A decrease in the incidence of inadvertent blebs to 0% with advent of phacoemulsification has been reported (2). Tenons or conjunctival inclusion cysts are smaller in size, nonprogressive in nature, and transillumination is not fully appreciated when compared to filtration bleb (3). Thermal cautery or yag laser are tried in acquired conjunctival cyts (4,5). Because of the elasticity of the conjunctiva filtration blebs are not only large but also progressive in nature and demonstrate considerable internal illumination. The problems arising from the bleb are hypotonic maculopathy causing diminution of vision, post-operative endophthalmitis, and spontaneous rupture (9).

Bleb formation can occur due to the improper wound construction such as premature entry, irregularity of internal lip, extension towards limbus forming a tongue or flap of tissue resulting in internal wound gape "fish mouthing" (6) and also due to excessive cauterization leading to scleral thinning. The scleral tunnel should be sutured if found unstable. Adequate hydration of the sideport will close the roof and floor of the tunnel. It has been found that temporal limbal tunnel is more. Minimal cauterization in order to achieve hemostasis should be done. It is also important to avoid inclusion of conjunctiva into the wound and pushing conjunctiva into anterior chamber while lens placement which may deposit the conjunctiva epithelial cells into the anterior chamber (5). Incision site significantly influenced mechanical wound strength and induced astigmatism; incision depth influenced neither. The wound strength was highest with temporal scleral incisions and lowest for superior limbal incision (10).

Uncomplicated bleb can be managed conservatively when the visual acuity and intraocular pressure is normal. Internal incision gape may cause permanent wound slippage and late induced against-the-rule astigmatism. It has been postulated that postoperative endophthalmitis may occur when bacteria enter the eye via the unsealed incision. (8,9) Because of the potential for devastating complications, any patient with a shallow anterior chamber, hypotony, or macular oedema with a clinically significant bleb persisting for more than 2-3 months or with ocular irritation needs a bleb repair. The present case the bleb caused dellen formation and secondary bacterial corneal infiltration. The section was closed after aspiration of the bleb which helped in the resolution of corneal infiltration. This case points us the need for proper wound apposition in order to prevent intraocular complications.

III. Conclusion

Proper wound construction is very essential for the good wound apposition of both internal and external lip of corneo-scleral tunnel. Inadvertent filtration bleb can have intraocular complication and needs to be sutured in order to prevent this.

References

- [1]. Swan KC, Cambell L. Unintentional Filtration Following Cataract Surgery. *Arch Ophthalmol* 1964;71:43.
- [2]. Kraff MC, Sanders DR, Lieberman HL. Total Cataract Extraction Through A 3-Mm Incision: A Report Of 650 cases. *Ophthalmic Surg* . 1979;10:46-54.
- [3]. Krishnacharya PS. Tenon's Cyst Presenting As A Long-Term Complication Following Incision Cataract Surgery. *Case Reports In Medicine*. 2013 Jan 1;2013.
- [4]. Hawkins AS, Hamming NA. Thermal Cautery As A Treatment For Conjunctival Inclusion Cyst After Strabismus Surgery. *Journal Of American Association For Pediatric Ophthalmology And Strabismus*. 2001 Feb 1;5(1):48-9.
- [5]. BUSTROS D. Treatment Of Acquired Epithelial Inclusion Cyst Of The Conjunctiva Using The YAG Laser. *Am J Ophthalmol*. 1984;98:807-8.
- [6]. Gimbel HV, Sun R, Debroff BM. Recognition And Management Of Internal Wound Gape. *Journal Of Cataract & Refractive Surgery*. 1995 Mar 1;21(2):121-4.
- [7]. Jain SS. Inadvertent Filtering Bleb Following Sutureless Cataract Surgery. *Indian Journal Of Ophthalmology*. 2005 Jul 1;53(3):196-8.
- [8]. Cooper BA, Holekamp NM, Bohigian G, Thompson PA. Case-Control Study Of Endophthalmitis After Cataract Surgery Comparing Scleral Tunnel And Clear Corneal Wounds. *American Journal Of Ophthalmology*. 2003 Aug 1;136(2):300-5.
- [9]. Stonecipher KG, Parmley VC, Jensen H, Rowsey JJ. Infectious Endophthalmitis Following Sutureless Cataract Surgery *Arch Ophthalmol*. 1991;109:1562-3
- [10]. Anders N, Pham DT, Antoni HJ, Wollensak J. Postoperative Astigmatism And Relative Strength Of Tunnel Incisions: A Prospective Clinical Trial *J Cataract Refract Surg*. 1997;23:332-6