

Outcome Of Sub Inguinal Microsurgical Varicocelectomy In Cases Of Severe Oligozoospermia With Necrozoospermia In Varicocele Patients

Dr. Rohan Jain

Dr. Sandeep Bathe

Dr. Abhay Mahajan

Dr. Navnath Fulari

Dr. Prashant Darakh

Dr. Anubhav Das

Urology resident, MGM Medical college and hospital, Aurangabad

Assistant professor, Dept of urology, MGM Medical college and hospital, Aurangabad

Professor and Head, Dept of urology, MGM Medical college and hospital, Aurangabad

Consultant Urologist Raghaji kidney and multispeciality hospital, Solapur

Assistant professor, Dept of urology, MGM Medical college and hospital, Aurangabad

Urology resident, MGM Medical college and hospital, Aurangabad

Date of Submission: 11-11-2023

Date of Acceptance: 20-11-2023

I. INTRODUCTION: -

Varicocele is a condition of abnormal tortuous and dilated veins in pampiniform venous plexus of scrotal sac. Severe oligozoospermia is the percentage of spermatozoa below 5×10^6 per ml. Necrozoospermia is low percent of live and high percent of immotile sperm in ejaculate. Treatment options available for these patients in assisted reproductive technique are: In vitro fertilisation (IVF) or intracytoplasmic sperm injection (ICSI)¹. The prevalence of varicocele is between 15 to 20 % out of which about 35% are male patients with infertility². Management approach includes mainly surgical repair³ amongst which various techniques include open surgical ligation of spermatic vein, microsurgical varicocelectomy and laparoscopic varicocelectomy. Each method has their advantages and disadvantages^{4,5,6}. However, subinguinal microsurgical varicocelectomy has been considered as the gold standard for its high rate of success and very low rate of complications^{4,5,6,7}. We have conducted the study in patients of severe oligozoospermia with necrozoospermia undergoing sub inguinal microsurgical varicocelectomy to analyse its effectiveness.

II. MATERIALS AND METHODS: -

STUDY DESIGN: -

- **TYPE OF STUDY:** It was a retrospective, observational study.
- **TIME SCALE OF THE STUDY:** The study was commenced following the approval of the Institutional Ethics Committee and retrospective analysis of patients of severe oligozoospermia with necrozoospermia in which subinguinal microsurgical varicocelectomy is performed (January 2020 to December 2022).
- **STUDY SITE:** The study was conducted at tertiary care centre, Aurangabad.
- **STATISTICAL ANALYSIS:** Data was entered in Microsoft Excel and was analyzed with descriptive statistics including mean and percentage. Chi-square χ^2 test will be used wherever necessary to test statistical significance.

INCLUSION CRITERIA:

The patients of severe oligozoospermia with necrozoospermia who underwent microsurgical subinguinal varicocelectomy between January 2020 to December 2022 were included in the study.

EXCLUSION CRITERIA:

Following patients were excluded from the study:

- a. Azoospermia
- b. Untreatable female causes of infertility.
- c. Subclinical varicocele

d. Abnormal karyotype

III. METHODOLOGY: -

Materials and Methods

Present study was conducted in the department of urology, tertiary care centre, Aurangabad in a retrospective manner after approval of institutional ethics committee. The data was recovered from IPD sheets. Detailed history and physical examination were recorded which included: unilateral/ bilateral varicocele; preoperative semen parameters such as- semen volume, sperm motility, sperm concentration; scrotal doppler including testis size and grade of varicocele; surgery details including intraoperative findings; as well as follow up in OPD with outcome of the patients in terms of improvement in semen parameters and or pregnancy.

Procedure

All patients had undergone a preoperative scrotal colour doppler ultrasound for assessing pampiniform plexus dilatation along with measurement of the testicular volume using $0.71 \times \text{lengths} \times \text{width} \times \text{height}$ formula. Varicocele grading was done following WHO diagnostic classification. Microsurgical varicocelectomy was performed using the sub inguinal approach. All couples were provided comprehensive information on the advantages and complications of the surgical technique. With spinal or general anaesthesia 2 cm subinguinal incision was made. Posterior veins identified, dissected, ligated with 4-0 ethilon and cut in between. Spermatic cord was identified and cremasteric fibres was opened. Under $10\times$ high power operating microscopic magnification spermatic veins were identified, dissected, and ligated using 4-0 ethilon and cut in between, while preserving the spermatic arteries, deferential artery, vas deferens and lymphatic vessels. Cord structures were scanned two to three times under high power microscope, so as not to miss any spermatic vein.

Semen analysis

Semen analysis was performed after 6 months of varicocelectomy. Semen samples were examined within 30 mins after ejaculation to maintain the quality of the specimen and samples were evaluated for:

1. Semen volume
2. Sperm concentration
3. Sperm motility rate

Responders were defined as increase in sperm motility rate and improvement in sperm concentration as compared to preoperative parameters or pregnancy. Data obtained were compiled and analyzed by statistical analytical tools using Medcalc Software Chi-square and Students t-test was used to compare the preoperative and postoperative sperm count, motility, and volume. P-value of ≤ 0.05 was considered statistically significant.

IV. Results

Table 1: Demographic and clinical history distribution

Sr No.	Variables	Result (N=17)
1	Age (Years) (Mean \pm SD)	32.41 \pm 2.52
2	BMI (Mean \pm SD)	28.82 \pm 1.62
3	Varicocele Laterality	
	Bilateral N (%)	5 (29 %)
	Unilateral N (%)	12 (71 %)
4	Varicocele Grade	
	Grade I N (%)	2 (12 %)
	Grade II N (%)	8 (47 %)
	Grade III N (%)	7 (41 %)

Table 1 shows mean \pm SD of age as 32.41 \pm 2.52 and mean \pm SD of BMI as 28.82 \pm 1.62. Varicocele on bilateral side was found in 5 (29 %) cases and on unilateral in 12 (71 %). Varicocele grade I was present in 2 (12 %), grade II in 8 (47 %) and grade III in 7 (41 %)

Table 2: Semen Analysis

Sr No.	Semen Parameters	Preoperative Mean \pm SD	Postoperative Mean \pm SD	P Value
1	Semen Volume (ml) (N=17)	2.72 \pm 0.28	2.91 \pm 0.30	0.065
2	Sperm concentration (million/mL) (N=17)	3.45 \pm 2.10	8.772 \pm 3.23	<0.0001
3	Sperm motility (%) (N=17)			
	a. Progressive (Rapid & sluggish)	10.00 \pm 6.61	23.52 \pm 12.34	0.0004
	b. Non-Progressive			
	c. Immotile	25.00 \pm 15.00	35.29 \pm 11.65	0.03
		66.76 \pm 19.68	41.17 \pm 21.68	0.001

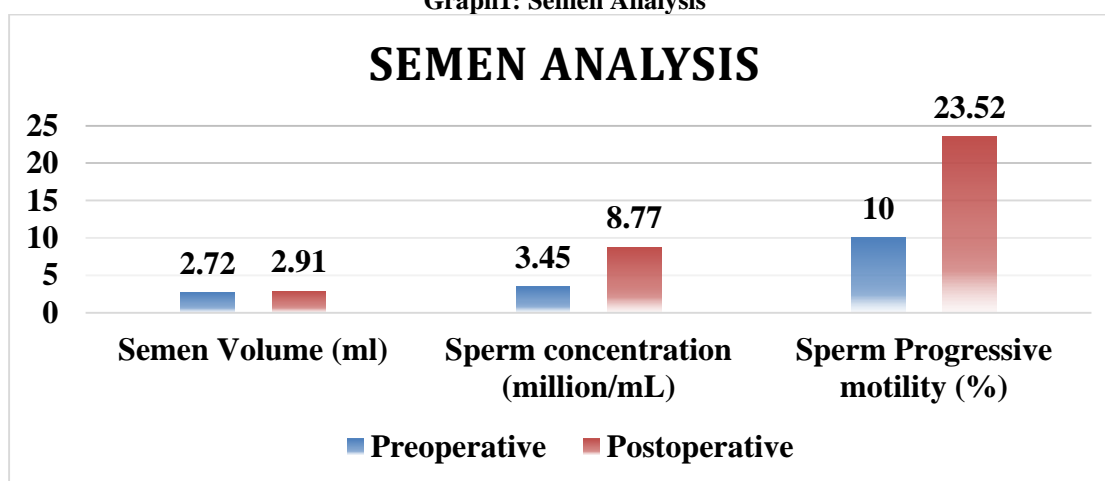
Table 2 shows semen parameters. Preoperative semen volume (ml) mean \pm SD was 2.72 ± 0.28 and postoperative was 2.91 ± 0.30 . Result was statistically non-significant ($P=0.065$). Sperm concentration (million/mL) mean \pm SD was 3.45 ± 2.10 and postoperative was 8.772 ± 3.23 . Result was statistically significant ($P<0.0001$). Preoperative sperm progressive motility (%) mean \pm SD was 10.00 ± 6.61 , non-progressive motility (%) mean \pm SD was 25.00 ± 15.00 , immotile (%) mean \pm SD was 66.76 ± 19.68 and postoperative was 23.52 ± 12.34 , 35.29 ± 11.65 , 41.17 ± 21.68 respectively. Result was statistically significant ($P<0.05$)

Table 3: Outcome

Sr No.	Outcome Variable	Present N (%)	Absent N (%)
1	Improvement of sperm concentration	16(94 %)	1(6 %)
2	Progressive motility	14(82 %)	3(18 %)
3	Spontaneous Pregnancy	6 (35 %)	11 (65 %)

Table 3 shows outcome variables. Improvement of sperm concentration was found in 16 (94 %) cases, progressive motility in 14 (82 %) cases whereas spontaneous pregnancy was occurred in 6 (35 %) cases only.

Graph1: Semen Analysis



V. Discussion

Varicocele is a common and correctable abnormality related to male infertility. Varicocelectomy is a cost-effective and efficient option with microsurgical subinguinal approach. It has beneficial effect on improvement of semen parameters has been extensively studied in previous papers also. However, results were not sufficient to come to conclusion due to the heterogeneity of inclusion criteria and variability of treatment methods performed. With this objective we have performed semen analysis in present study in 17 patients of severe oligozoospermia with necrozoospermia who underwent microsurgical varicocelectomy. Results obtained consist of mean \pm SD of age as 32.41 ± 2.52 and mean \pm SD of BMI as 28.82 ± 1.62 . Varicocele on bilateral side was found in 5 (29 %) cases and on unilateral in 12 (71 %). Varicocele grade I was present in 2 (12 %), grade II in 8 (47 %) and grade III in 7 (41 %). In similar study by **Waleed Shabana et al (2015)**⁸ mean \pm standard deviation of age and body mass index (BMI) was 28.3 ± 7.4 years and 29.1 ± 2.7 kg/m². 66 patients (53.6 %) had bilateral varicocele and 57 (46.3%) had unilateral. Varicocele grade I was diagnosed in 42 (34.1%) patients and 81 (65.9 %) had grade II or III. **Hai Thanh Phan et al (2021)**⁹ in their study found mean of age as 32.9 ± 5.1 years (range 20–43). In present study preoperative semen volume (ml) mean \pm SD was 2.72 ± 0.28 and postoperative was 2.91 ± 0.30 . Result was statistically non-significant ($P=0.065$). Sperm concentration (million/mL) mean \pm SD was 3.45 ± 2.10 and postoperative was 8.772 ± 3.23 . Result was statistically significant ($P<0.0001$). Preoperative sperm progressive motility (%) mean \pm SD was 10.00 ± 6.61 , non-progressive motility (%) mean \pm SD was 25.00 ± 15.00 , immotile (%) mean \pm SD was 66.76 ± 19.68 and postoperative was 23.52 ± 12.34 , 35.29 ± 11.65 , 41.17 ± 21.68 respectively. Result was statistically significant ($P<0.05$). Improvement of sperm concentration was found in 16 (94 %) cases, progressive motility in 14 (82 %) cases whereas spontaneous pregnancy was occurred in 6 (35 %) cases only. In similar study by **Waleed Shabana et al (2015)**⁸ improvement of sperm density and progressive motility was noted in 87 patients (70.7%). **Hai Thanh Phan et al (2021)**⁹ in their study found preoperative semen count mean \pm SD as 10.01 ± 4.8 and postoperative after 3 months as 21.19 ± 6.8 (0–160) and after 6 months as 16.96 ± 5.3 (0–110). **Ishikawa T et al (2005)**¹⁰ in a study on 133 patients found sperm concentration, morphology and motility was improved in 42%, 57% and 29% of patients,

respectively. **Baazeem A et al (2011)**¹¹ in their study found that the mean increase of sperm concentration was $12.3 \times 10^6/\text{mL}$ ($p < 0.0001$), while the mean improvement of motility was 9.7 % ($p = 0.003$).

One of the explanations for varicocele influencing spermatogenesis is resultant venous blood stagnation in the testis which is increasing oxidative stress, toxins, increase in hypoxia, decrease in oxygenation, increase in renal and adrenal metabolites, increase DNA fragmentation affecting spermatogenesis and causing infertility through thermal effect. Varicocelectomy is an effective procedure to treat male infertility in patients with clinical varicocele which brings intra-testicular temperature to normal range, decreases sperm DNA fragmentation¹². Semen parameters like sperm motility, sperm concentration shows improvement in result following varicocele ligation. Hence, post-surgery, few patients had natural pregnancy, there is downstaging of treatment where in patients underwent IUI instead of ICSI since the former is more cost effective than the later.

VI. Conclusion

Microsurgical varicocelectomy improves sperm concentration with sperm motility in patients with severe oligozoospermia with necrozoospermia. Grade of the varicocele, sperm count and progressive motility are major predictors in assessing outcome of varicocelectomy. Our study, hence, states that microsurgical varicocelectomy is an effective option for the treatment of male infertility; because, it has resultant improvement in reproductive outcomes.

References

- [1]. Majzoub A, Elbardisi H, Covarrubias S, Mak N, Agarwal A, Henkel R, Elsaid S, Al-Malki AH, Arafa M. Effect Of Microsurgical Varicocelectomy On Fertility Outcome And Treatment Plans Of Patients With Severe Oligozoospermia: An Original Report And Meta-Analysis. *Andrologia*. 2021 Jul;53(6):E14059.
- [2]. Gorelick JJ, Goldstein M (1993) Loss Of Fertility In Men With Varicocele. *Fertil Steril* 59(3):613–616
- [3]. Schlesinger MH, Wilets IF, Nagler HM (1994) Treatment Outcome After varicocelectomy. A Critical Analysis. *Urol Clin North Am* 21(3):517–529
- [4]. Al-Kandari AM, Shabaan H, Ibrahim HM, Elshebiny YH, Shokeir AA (2007) Comparison Of Outcomes Of Different Varicocelectomy Techniques: Open Inguinal, Laparoscopic, And Subinguinal Microscopic Varicocelectomy: A Randomized Clinical Trial. *Urology* 69(3):417–420
- [5]. Cayan S, Kadioglu TC, Tefekli A, Kadioglu A, Tellaloglu S (2000) Comparison of Results And Complications Of High Ligation Surgery And Microsurgical high Inguinal Varicocelectomy In The Treatment Of Varicocele. *Urology* 55(5):750–754
- [6]. Unal D, Yeni E, Verit A, Karatas OF (2001) Clomiphene Citrate Versus varicocelectomy In Treatment Of Subclinical Varicocele: A Prospective randomized Study. *Int J Urol* 8(5):227–230
- [7]. Wang J, Xia SJ, Liu ZH, Tao L, Ge JF, Xu CM, Qiu JX (2015) Inguinal And subinguinal Micro-Varicocelectomy, The Optimal Surgical Management Of varicocele: A Meta-Analysis. *Asian J Androl* 17(1):74–80
- [8]. Waleed Shabana, Mohamed Teleb, Tamer Dawod, Ehab Elsayed, Esamdesoky, Ashraf Shahin, Mahmoud Eladl, Waleed Sorour, MD Predictors Of Improvement In Semen Parameters After varicocelectomy For Male Subfertility: A Prospective Study. *Can Urol Assoc J* 2015;(9-10):E579-82
- [9]. Hai Thanh Phan, Thanh Xuan Nguyen, Du Vinh Nguyen, Hoai Anh Vu, Duc Anh Le And Nhu Hien Pham. Efficacy Of Scroto-Inguinal Microsurgical varicocelectomy In Treating Male Infertility. *Phan Et Al. Afr J Urol* (2021) 27:38
- [10]. Ishikawa T, Fujisawa M. Effect Of Age And Grade On Surgery For Patients With Varicocele. *Urology* 2005;65:768
- [11]. Baazeem A, Belzile E, Ciampi A, Et Al. Varicocele And Male Factor Infertility Treatment: A New Meta-Analysis and Review Of The Role Of Varicocele Repair. *Eur urol* 2011;60:796-808
- [12]. Cho CL, Esteves SC, Agarwal A. Novel Insights Into The Pathophysiology Of Varicocele And Its Association With Reactive Oxygen Species And Sperm DNA Fragmentation. *Asian J Androl*. 2016 Mar-Apr;18(2):186-93.