

# Left Diaphragmatic Injury And Lacerated Stomach, Pericardium And Lung During A Penetrating Stab Wound: A Case Report

Ahmad Reza Shahraki<sup>1</sup> \* Reza Abaee<sup>2</sup>, Elham Shahraki<sup>3</sup>.

1-General Surgeon, Assistant Professor, Department Of Surgery, Zahedan Medical Faculty, Zahedan University Of Medical Sciences And Health Services, Zahedan, Iran.

2- MD, General Physician, Medical Faculty, Tehran, Iran.

3- Associated Professor Of Nephrology, Department Of Internal Medicine, Nephrologist, Ali Ibne Abitaleb Hospital, Zahedan University Of Medical Sciences, Zahedan, I.R. Iran.

---

## Abstract:

Diaphragmatic injuries are rare consequences of thoracoabdominal trauma and they often occur in association with multiorgan injuries. The diaphragm is a difficult anatomical structure to study with common imaging instruments due to its physiological movement. Thus, diaphragmatic injuries can often be misunderstood and diagnosed only during surgical procedures. Diagnostic delay results in a high rate of mortality. Combined penetrating injuries of the thorax and abdomen carry high morbidity and mortality compared to injuries inside a single cavity. Object(s) which are penetrating inside body cavities should not be removed before the patient is in theater. Our case was a 27 years old male that stabbed on left Thoracoabdomen, that perforated diaphragm, Pericardium and stomach. Penetrating thoracoabdominal injuries are associated with high morbidity and mortality. Concurrent clinical evaluation and resuscitation followed by early surgery are associated with good outcome. Impalement objects must only be removed in theater when patient is under anesthesia.

**Key words:** Stab Wounds, Diaphragmatic injury, Diaphragmatic repair, Stomach perforation.

---

Date of Submission: 08-12-2023

Date of Acceptance: 18-12-2023

---

## I. Background:

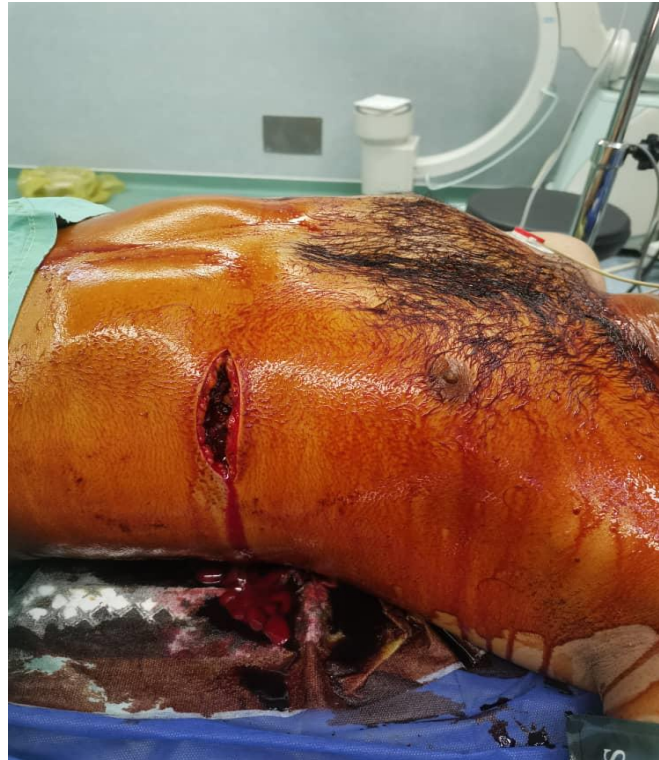Diaphragmatic injuries are rare consequences of Thoracoabdominal trauma and they often occur in association with multi organ injuries. The diaphragm is a difficult anatomical structure to study with common imaging instruments due to its physiological movement. Thus, diaphragmatic injuries can often be misunderstood and diagnosed only during surgical procedures. Diagnostic delay results in a high rate of mortality.(1). Diaphragmatic injuries are rare consequences of thoracoabdominal trauma and they often occur in association with multi organ injuries. The diaphragm is a difficult anatomical structure to study with common imaging instruments due to its physiological movement. Thus, diaphragmatic injuries can often be misunderstood

and diagnosed only during surgical procedures. Diagnostic delay results in a high rate of mortality(2). Diaphragmatic injuries are a diagnostic and therapeutic challenge for the surgeon. They are often unrecognized, and diagnostic delay causes high mortality from these injuries(3). In countries with a low incidence of interpersonal violence, it is quite a rare trauma, with only 4-5% of patients undergoing laparotomy for trauma presenting a diaphragmatic injury(4). Clinical presentation varies from a state of hemodynamic instability secondary to bleeding of the diaphragm and organs involved in the trauma(5). Combined penetrating injuries of the thorax and abdomen carry high morbidity and mortality compared to injuries inside a single cavity. Object(s) which are penetrating inside body cavities should not be removed before the patient is in theater.(6).

In this case Exploration and notice to the signs and symptoms help to discovered power of stab wound.

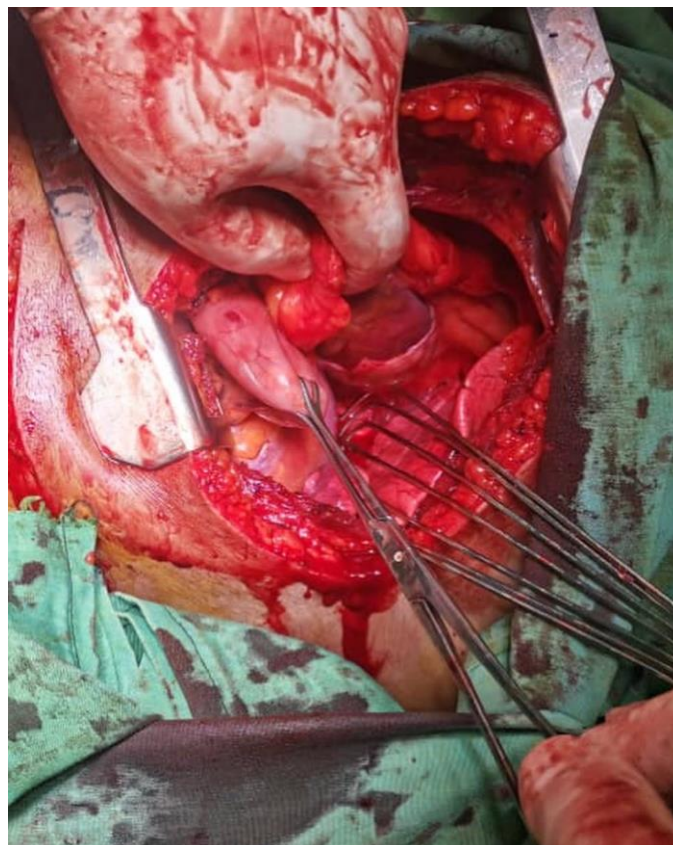
## II. Case presentation:

Our case was a 27 years old male that stabbed on left thoracoabdomen.



**Figure1:Penetrating wound in left thoracoabdomen**

Her blood pressure was 90/60 and heart rate was 110. We bring him to operation room and located a chest tube because of respiration distress. Then we explore the wound and find diaphragm and pericardium perforated.



**Figure2: Perforation of pericardium, diaphragm and stomach**

Heart was clear in shape, and we focus on diaphragm and stomach. At first we repair stomach, then diaphragm and at the end left thorax, we locate a chest tube in this space. After 6 days we can discharge patient healthy and carefully.

### **III. Conclusion:**

Penetrating Thoracoabdominal injuries are associated with high morbidity and mortality. Concurrent clinical evaluation and resuscitation followed by early surgery are associated with good outcome. Impalement objects must only be removed in theater when patient is under anesthesia.(6). Relying on the physical examinations and paraclinical studies may be an appropriate substitution for exploration surgery when possible iatrogenic injuries may affect the patient's quality of life.(7) The management of penetrating trauma is usually undertaken by an interprofessional team that consists of a trauma surgeon, thoracic surgeon, pulmonologist, pain specialist, cardiac surgeon, respiratory therapist, and intensive care unit (ICU) nurses. The key to reducing morbidity and mortality is prompt resuscitation, diagnosis, and management.(8) The severity of stabbing depends on the point of entry to the chest (wound below the nipples in front and the inferior scapular angle at back should be considered as thoraco-abdominal wounds) which organ has been injured (chest wall vessels, lung, heart, great thoracic vessels, visceral pleura, oesophagus, diaphragm), shape and sharpness of penetrating object and finally is penetrating object still in the chest wound or has been taken out. In most cases, stabbing object penetrate through the chest wall hurting intercostal blood vessels and with its tip visceral pleura, contributing developing of pneumothorax or hematomopneumothorax(9). Stab wounds of the chest can be made by the different sharp objects such as knives, daggers, pieces of glass or other metals. The shape of this wounds is not typical, due to the skin elasticity which usually shrink the entrance to the wound.(10)

### **References:**

- [1]. Antonino Agrusa, Giorgio Romano, Daniela Chianetta, Giovanni De Vita, Giuseppe Frazzetta, Giuseppe Di Buono, Vincenzo Sorce & Gaspare Gulotta . Right Diaphragmatic Injury And Lacerated Liver During A Penetrating Abdominal Trauma: Case Report And Brief Literature Review. *World Journal Of Emergency Surgery* Volume 9, Article Number: 33 (2014).
- [2]. Antonino Agrusa\*, Giorgio Romano, Daniela Chianetta, Giovanni De Vita, Giuseppe Frazzetta, Giuseppe Di Buono, Vincenzo Sorce And Gaspare Gulotta. Right Diaphragmatic Injury And Lacerated Liver During A Penetrating Abdominal Trauma: Case Report And Brief Literature Review. *Agrusa Et Al. World Journal Of Emergency Surgery* 2014, 9:33 Page 2 Of 5  
[Http://Www.Wjes.Org/Content/9/1/33](http://www.wjes.org/content/9/1/33).
- [3]. Duzgun AP, Ozmen MM, Saylam B, Coskun F: Factors Influencing Mortality In Traumatic Ruptures Of Diaphragm. *Ulus Travma Acil Cerrahi Derg* 2008, 14(2):132–138.
- [4]. Lewis JD, Starnes SL, Pandalai PK, Huffman LC, Bulcao CF, Pritts TA, Reed MF: Traumatic Diaphragmatic Injury: Experience From A Level I Trauma Center. *Surgery* 2009, 146(4):578–584.
- [5]. Bosanquet D, Farboud A, Lunckraz H: A Review Of Diaphragmatic Hernia. *Resp Med CME* 2009, 2:1–6.
- [6]. David Muchuweti | Edwin Muguti. Penetrating Thoracoabdominal Injuries From Multiple-Spiked Spear Stabbing: Case Report And Literature Review. DOI: 10.1002/Ccr3.2809.
- [7]. Baghbani S, Rezaei Nosrati M, Fallah Y, Siavashi B, Golbakhsh MR. Intraosseous Stab Wound Of Scapula: A Case Report. *J Orthop Spine Trauma*. 2020;5(4):110-2.
- [8]. Jain A, Sekusky AL, Burns B. Penetrating Chest Trauma. [Updated 2023 Apr 17]. In: Statpearls [Internet]. Treasure Island (FL): Statpearls Publishing; 2023 Jan-. Available From: [Https://Www.Ncbi.Nlm.Nih.Gov/Books/NBK535444/](https://www.ncbi.nlm.nih.gov/books/NBK535444/)