

## An Acute Surgical Abdomen In 75 Years Old Female With Struma Ovaries: A Case Report

Ahmad Reza Shahraki<sup>1</sup> \*, Reza Abaee<sup>2</sup>, Elham Shahraki, Mahdi Zadmehr<sup>4</sup>.

1-General Surgeon, Assistant Professor, Department Of Surgery, Zahedan Medical Faculty, Zahedan University Of Medical Sciences And Health Services, Zahedan, Iran.

2- MD, General Physician, Medical Faculty, Tehran, Iran.

3- Associated Professor Of Nephrology, Department Of Internal Medicine, Nephrologist, Ali Ibne Abitaleb Hospital, Zahedan University Of Medical Sciences, Zahedan, I.R. Iran.

4- Pathologist, Department Of Pathology, Zahedan Medical Faculty, Zahedan University Of Medical Sciences And Health Services, Zahedan, Iran.

---

### Abstract

*Struma ovarii is a rare Dermoid tumor that consists of more than 50% thyroid tissue. The incidence of Struma ovarii is reported to be 1% of all ovarian tumors and 2-5% of all ovarian Teratomas. Struma ovarii is a rare ovarian lesion which characterized by the presence of thyroid tissue in at least half of the overall ovarian mass. Ovarian tumors presented with ovarian mass in childhood and adolescence are uncommon but an important part of gynecological cases. In this case we report a rare ovarian tumor in rare decades of life for this kind of tumor and handle the patient. The treatment of Struma ovaries is excision and following with pathologic results.*

**Key words:** Struma ovaries - Ovarian tumor- Case report ,Surgery.

---

Date of Submission: 08-12-2023

Date of Acceptance: 18-12-2023

---

### I. Background:

Teratoma comprises 15%-20% of ovarian tumors. Ovarian teratoma is a germinal cell tumor arising from foetal yolk sac germinal cells. Based on the WHO classification, ovarian teratomas can be divided into 3 groups: mature, immature, and monodermal. Because these teratomas are germinal cell tumors, they are typically differentiated from the embryonic germ layer into 3 components: ectoderm, endoderm, and mesoderm. As a result, these tumors demonstrate a wide variety of morphologies. A Monodermal Teratoma is defined as an ovarian teratoma that contains predominantly or solely one type of tissue(1)

Struma ovarii is a germ cell tumor of the ovary. It is comprised of more than 50% thyroid tissue and can be differentiated from a mature Teratoma, which contains only a small component (less than 50%) of benign thyroid tissue. Despite the high thyroid tissue content of such tumors, Thyrotoxicosis occurs in only 5% of all struma ovarii cases(2)

Struma ovarii is a rare ovarian lesion which characterized by the presence of thyroid tissue in at least half of the overall ovarian mass (3).

Struma ovarii is a rare ovarian tumor that can present with non-specific symptoms suggestive of a hyperthyroid state or perimenopausal symptoms in patients approaching menopause. A high level of clinical suspicion along with thorough clinical examination is crucial to diagnose such a tumor. Although benign forms are more common, malignant struma ovarii have also been documented, mainly as papillary thyroid carcinoma(4). This mass comprises less than 1 % of ovarian tumors and also 2 to 5 % of all ovarian teratomas (5). Struma ovarii usually presents in the fifth and sixth decades of life and seldom before puberty(6).

Ovarian tumors presented with ovarian mass in childhood and adolescence are uncommon but an important part of gynecological cases(7). this work has been reported in line with the SCARE 2020 criteria(8). This case was so rare and full of challenges that patient just has pain and other objects was normal.

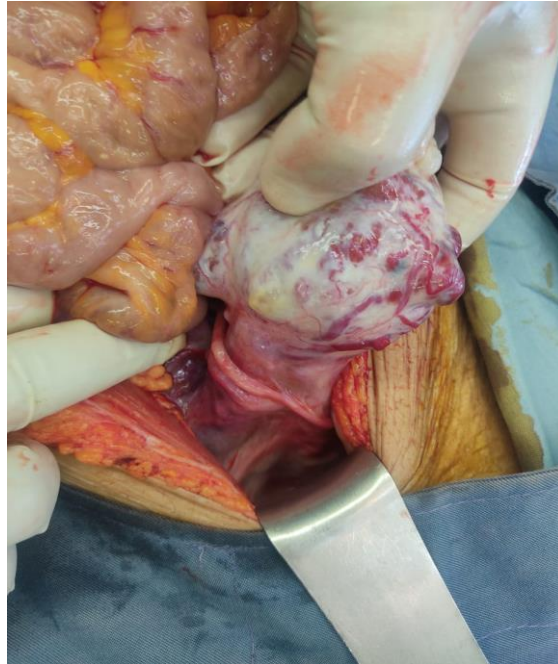
### II. Case presentation:

the author reports a 75 years old female with generalized abdominal pain with guarding ,tenderness and rebound tenderness generally. nausea and vomiting was negative and bowel habit was normal x-rays

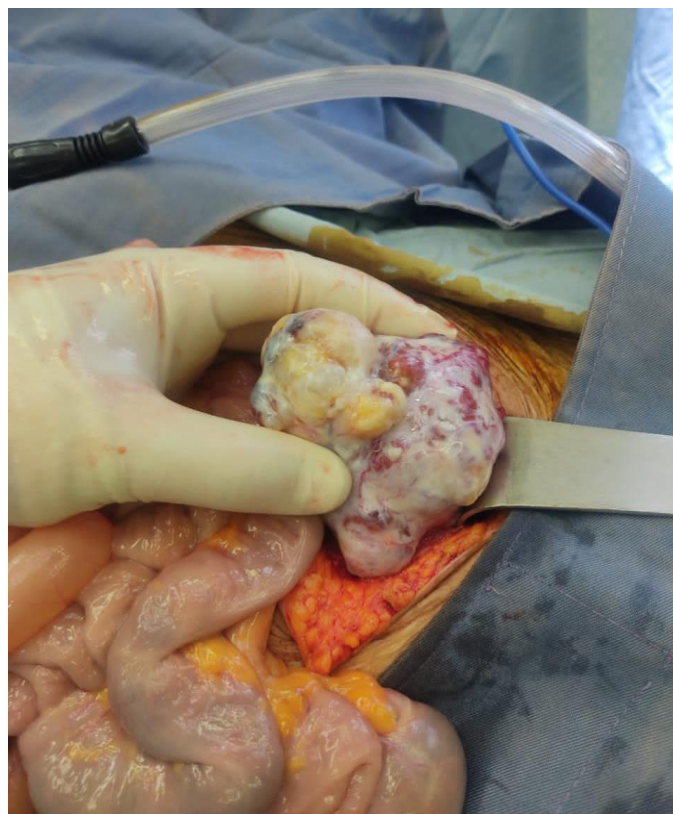
---

<sup>1</sup> Corresponding author E-Mail: a.r\_sh@yahoo.com

includes chest uprights and Abdominopelvic uprights and lie down was normal. Vital signs were: HR:75,RR:8,blood pressure 135/75 and Temperature was 37.1. Normal lab data's with no leukocytosis or decrease of Hb discovered for her. She was undergone a ultrasonography that reports normal organs in abdomen and pelvic but the pain was increasing in patient, that decided to do explorative laparotomy and we faced with a mass in right ovary that was full of vessels with no adhesion to other tissue or organs. Right ovary not be separated from tumor and uterus was shrinkage and left ovary was small but in major figure was normal. in abdomen we did not have fluids or small tissues in omentum or peritoneum.

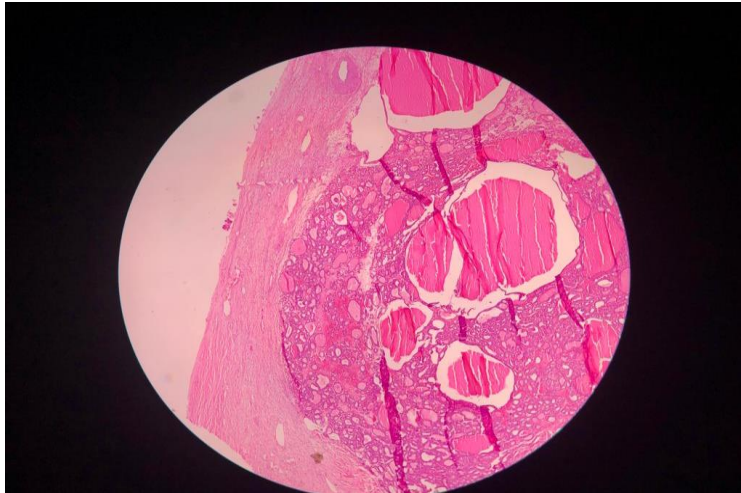


**Figure1: A mass in right ovary**

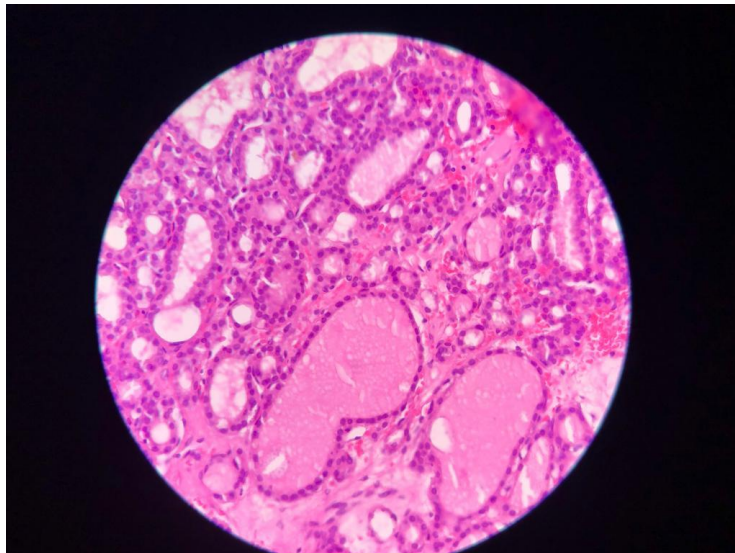


**Figure 2: A mass in right ovary**

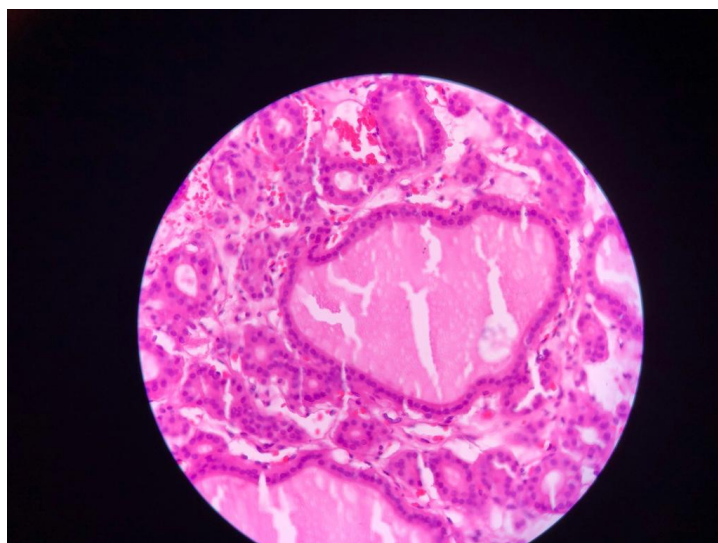
After surgery that concluded excision of mass completely we sent that mass for Pathological lab and we received reports of Strauma ovarii.



**Figure3: Pathological view of mass**



**Figure4: Pathological view of mass**



**Figure 5: Pathological view of mass**



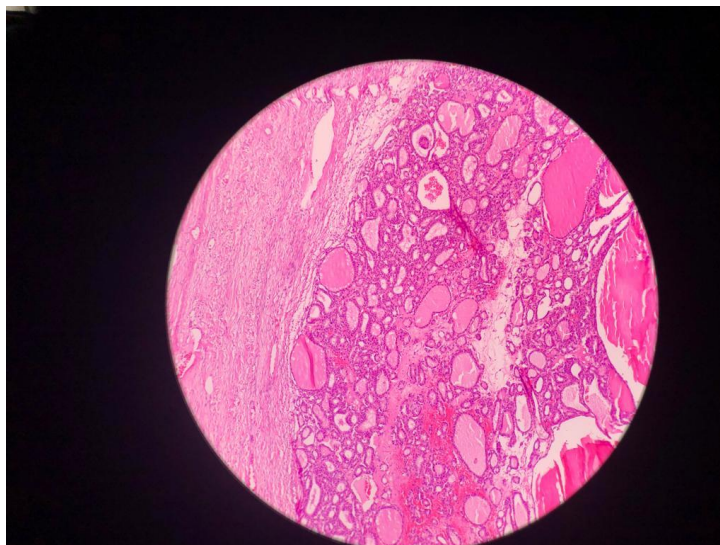


Figure6: Pathological view of mass

### III. Conclusion:

Struma ovarii is a rare ovarian tumour, characterized by the presence of thyroid follicles inside the ovary, and more commonly discovered in teratomas, as was the case of our patient .(9) Struma ovarii has no particular symptom and can be an incidental finding. Overall, 20% of patients present with pain and 80% are asymptomatic. Other symptoms include abdominal swelling, abnormal uterine haemorrhage, breathlessness and hyperthyroidism.(10)

As the common clinical symptoms, abdominal pain, palpable abdominal mass, abnormal vaginal bleeding, ascites, or pseudo-Meigs syndrome (ascites in the setting of hydrothorax) can be expressed by the patients.( 11)

Because of nonspecific clinical manifestations, the tumor can be revealed incidentally on pelvic imaging or surgery. Thyroid dysfunction can be also found in 5–8 % of patients . In epidemiological view, no racial predilection for struma ovarii was found, but this tumor appears commonly in the age range of 40 to 60 years and may be rarely seen before puberty.(12)

The patient was successfully managed surgically without any evidence of recurrence in further assessment.

### References:

- [1]. Kurman Robert J, C Maria Luisa, Simon Herrington C., Young Robert H. WHO Classification Of Tumors Of Female Reproductive Organs. 4th Ed. International Agency For Research On Cancer; Lyon: 2014. Tumors Of The Ovary: Germ Cell Tumors; P. 57
- [2]. Zhang X, Axiotis C: Thyroid-Type Carcinoma Of Struma Ovarii. Arch Pathol Lab Med. 2010, 134:786-91. 10.5858/134.5.786
- [3]. K. Botros, N. Noor Chelsea, J. Bermingham Struma Ovarii: A Thyroxine-Producing Ovarian Tumor In Pregnancy Cureus, 13 (9) (2021 Sep 26), Article E18292, 10.7759/Cureus.18292 Ecollection 2021 Sep.
- [4]. Yasutake N.A, Noguchi H.B, Ibayashi Y.C, Nakamura H.D, Tateishi K.D, Yuki K.A, Et Al. The Smallest Reported Malignant Struma Ovarii: A Case Report. Case Rep Oncol. 2018;11:693–698
- [5]. A. Podfigurna, A. Szeliga, P. Horwat, M. Maciejewska-Jeske, B. Meczekalski Gynecol. Endocrinol., 37 (12) (2021 Dec), Pp. 1143-1150.
- [6]. Elif Iltar<sup>1</sup>, Isin Ureyen<sup>2</sup>, Tayfun Toptas<sup>2</sup>, Melike Savas<sup>1</sup>, Sema Çekiç<sup>3</sup>, Aysel Uysal<sup>1</sup>. A Rare Case: Struma Ovarii In A 14-Year-Old Girl. J Adolesc Young Adult Oncol. 2018 Feb;7(1):134-136. Doi: 10.1089/Jayao.2017.0033. Epub 2017 Jul 31.
- [7]. Utsunomiya D, Shiraishi S, Kawanaka K, Lwakatara F, Tomiguchi S, Kido R, Et Al. Struma Ovarii Coexisting With Mucinous Cystadenoma Detected By Radioactive Iodine. Clin Nucl Med 2003;28:725–7.
- [8]. R.A. Agha, T. Franchi, C. Sohrabi, G. Mathew, For The SCARE Group The SCARE 2020 Guideline: Updating Consensus Surgical Case Report (SCARE) Guidelines
- [9]. Utsunomiya D, Shiraishi S, Kawanaka K, Lwakatara F, Tomiguchi S, Kido R, Et Al. Struma Ovarii Coexisting With Mucinous Cystadenoma Detected By Radioactive Iodine. Clinnucl Med 2003;28:725–7.
- [10]. Sakabe, T. Fukagawa, D. Fukagawa, R. Sugimoto, N. Uesugi, K. Ishida, H. Itamochi, T. Sugiyama, T. Sugai
- [11]. Struma Ovarii With Unique Histological Features: A Case Report Int.J. Clin. Exp. Pathol., 10 (11) (2017 Nov 1), Pp. 11230-11233 Ecollection 2017.
- [12]. V. Weinberger, J. Kadlecova, L. Min`A`r, M. Felsing, M. Anton, P. Ovesna, M. Bedna`rikov`A, M. `Cihalov`A, E. Jand`Akov`A, J. Hausnerov`A, M. Zik`An, Struma Ovarii - Ultrasound Features Of A Rare Tumor Mimicking Ovarian Cancer, Med. Ultrason. 20 (3) (2018 Aug 30) 355–361, <https://doi.org/10.11152/Mu-1526>.