

Study of Macular Thickness by Using Optical Coherence Tomography in Diabetic Patients

Dr. L.ASHA, Dr. J.RAJENDRA PRASAD

(Department of Ophthalmology, DR.PSIMS&RF, INDIA)

Abstract :

BACKGROUND: Currently 77 million people are suffering from diabetes in India. Prevalence of diabetic retinopathy has been estimated to be 17.6% among adults with diabetes. Approximately 4 million people around the world losing their sight from diabetic retinopathy, the leading cause of blindness in patients aged 20 to 74 years. The main objective of the study was to study the effect of diabetes and diabetic retinopathy on macular thickness by using Optical Coherence Tomography(OCT). **METHODS:** It is a cross-sectional study conducted from May to October 2022 among patients who came to the ophthalmology OPD with a history of diabetes mellitus. Cirrus HD-SPECTRAL DOMAIN OCT(High definition- OCT) was done by using a macular cube 512×128µm to assess the macular thickness. **RESULTS:** The mean age of participants was 52 with 51% males & 49% females. Out of 100 patients, 42 patients had mild non-proliferative diabetic retinopathy(NPDR) changes, 12 with moderate NPDR, 10 with severe NPDR, 4 with early proliferative diabetic retinopathy(PDR), 32 without any diabetic retinopathy changes. Patients with no DR and mild NPDR had no significant increase in macular thickness. Patients with moderate NPDR, severe NPDR & early PDR has increased foveal and outer macula thickness.

Keywords: diabetes, diabetic retinopathy, OCT, diabetic macular edema, NPDR, PDR

Date of Submission: 02-02-2023

Date of Acceptance: 13-02-2023

I. Introduction:

Currently 77 million people are suffering from diabetes in India. The prevalence of diabetic retinopathy has been estimated to be 17.6% among adults with diabetes.^[1] Approximately 4 million people around the world losing their sight from diabetic retinopathy, the leading cause of blindness in patients aged 20 to 74 years. The risk of development and progression of diabetic retinopathy is closely associated with the type and duration of diabetes, blood glucose, blood pressure, and possibly lipids. A strong relationship between chronic hyperglycemia and the development and progression of diabetic retinopathy. Increased polyol pathway, activation of protein kinase C (PKC), increased expression of growth factors such as vascular endothelial growth factor (VEGF) and insulin-like growth factor-1 (IGF-1), hemodynamic changes, accelerated formation of advanced glycation end products (AGEs), oxidative stress, activation of the renin-angiotensin-aldosterone system (RAAS), and subclinical inflammation and capillary occlusion lead to retinal thickening at the posterior pole due to retinal vascular hyperpermeability & other alterations in the retinal microenvironment.^[2] Visual acuity often depends on the central foveal involvement, Perifoveal capillary blood flow velocity, Severity of perifoveal capillary occlusion, Retinal thickness at the central fovea, and Integrity of ELM & IS/OS junction.^[5]

II. Methodology:

It was a cross-sectional study that was conducted on patients attending the ophthalmology OPD with a history of diabetes mellitus from May to October 2022 at Dr.PSIMS& RF. It was conducted among 100 patients.

Inclusion criteria: Patients with history of diabetes mellitus.

Exclusion criteria: Patients with a history of hypertension, ocular trauma or surgeries, history of uveitis, or any other ocular diseases were excluded from the study.

The initial examination included visual acuity measurement by SNELLENS CHART, anterior segment examination by slit lamp biomicroscopy, and Intraocular pressure measured by using Goldmann's applanation tonometry, fundus examination by 90D lens, and/or IDO. Patients with diabetic retinopathy changes on slit-lamp examination were graded based on Early Treatment Diabetic Retinopathy Study(ETDRS) classification. Cirrus HD-OCT(spectral domain) was done by using a macular cube 512×128µm to assess the macular thickness.

III. Results :

Table 1. Agedistribution

Mean age of the patients was 52

Age	No of patients	Percentage
<30	2	2%
31-40	8	8%
41-50	18	18%
50-60	34	34%
>60	38	38%
Total	100	100

Figure 1 :

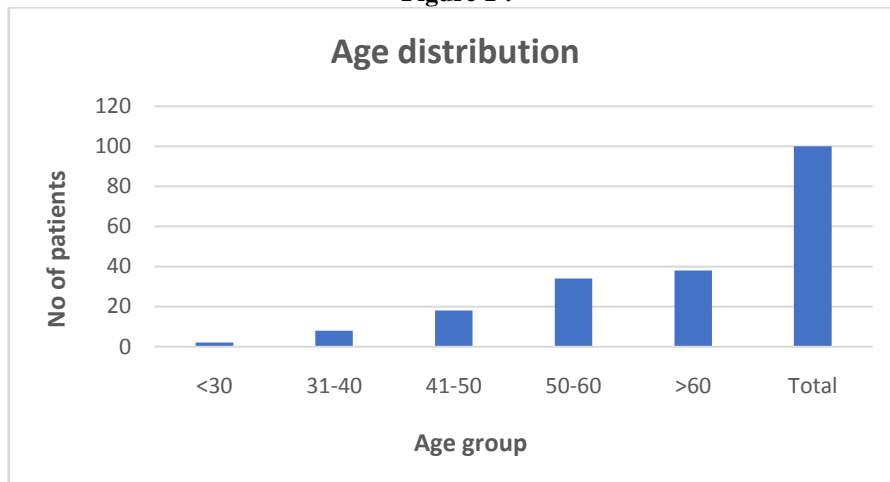


Table 2. Sex distribution

Sex	Percentage
Males	51%
Females	49%

Figure 2

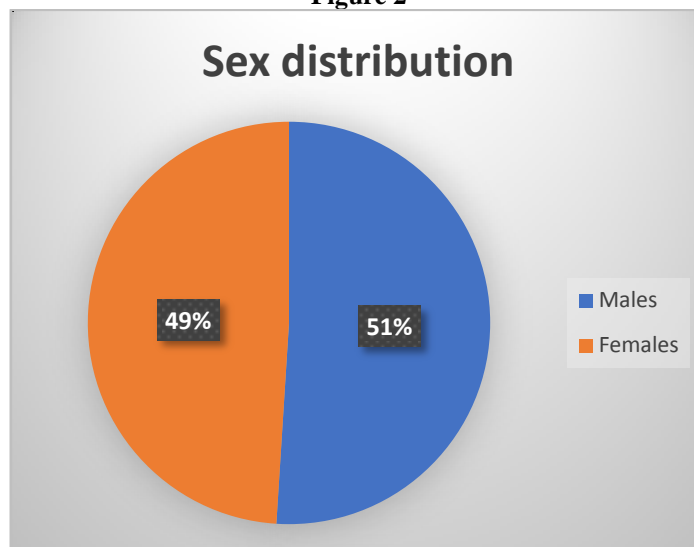


Table 3. Grading of Diabetic retinopathy(Based on ETDRS classification)

Grade of diabetic retinopathy	No of patients(%)
Mild NPDR	42
No DR	32
Moderate NPDR	12
Severe NPDR	10
Early PDR	4

Figure 3 :

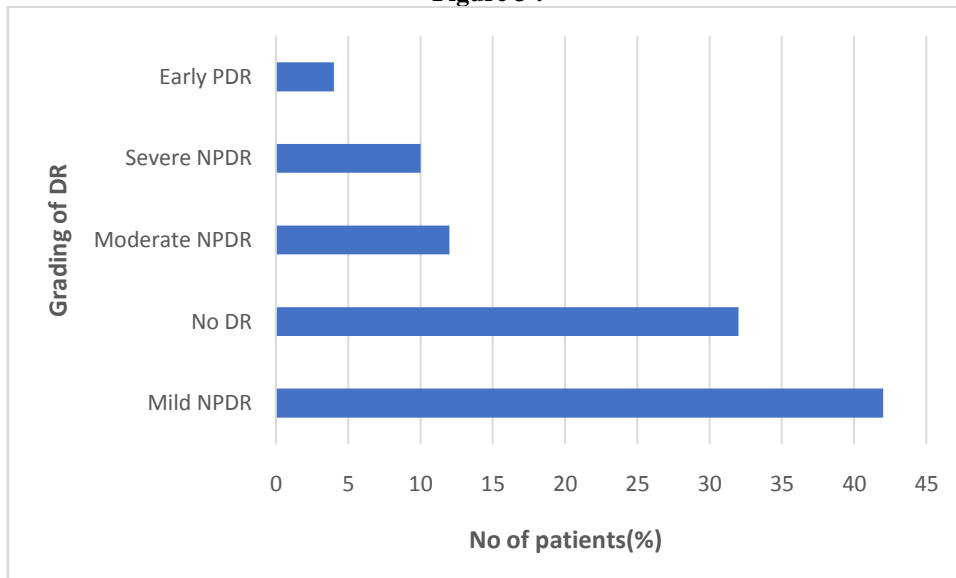
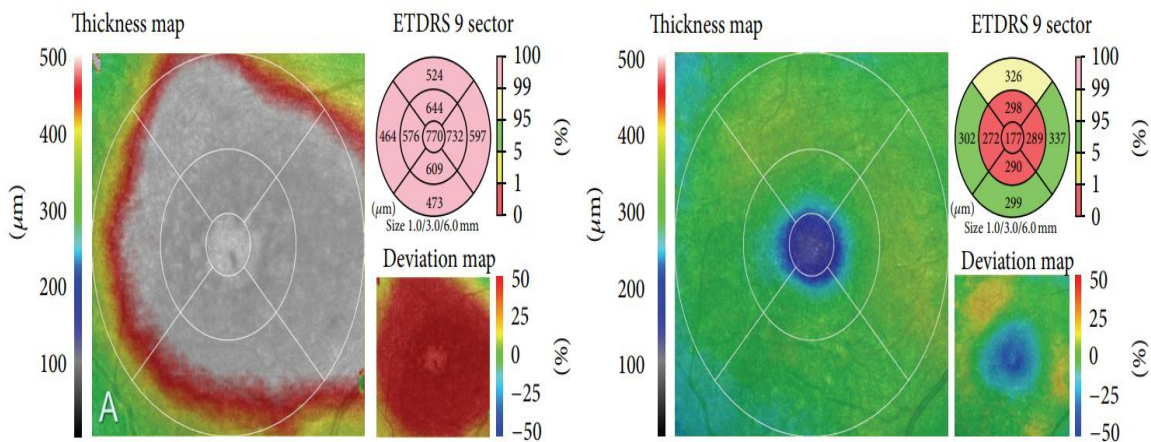
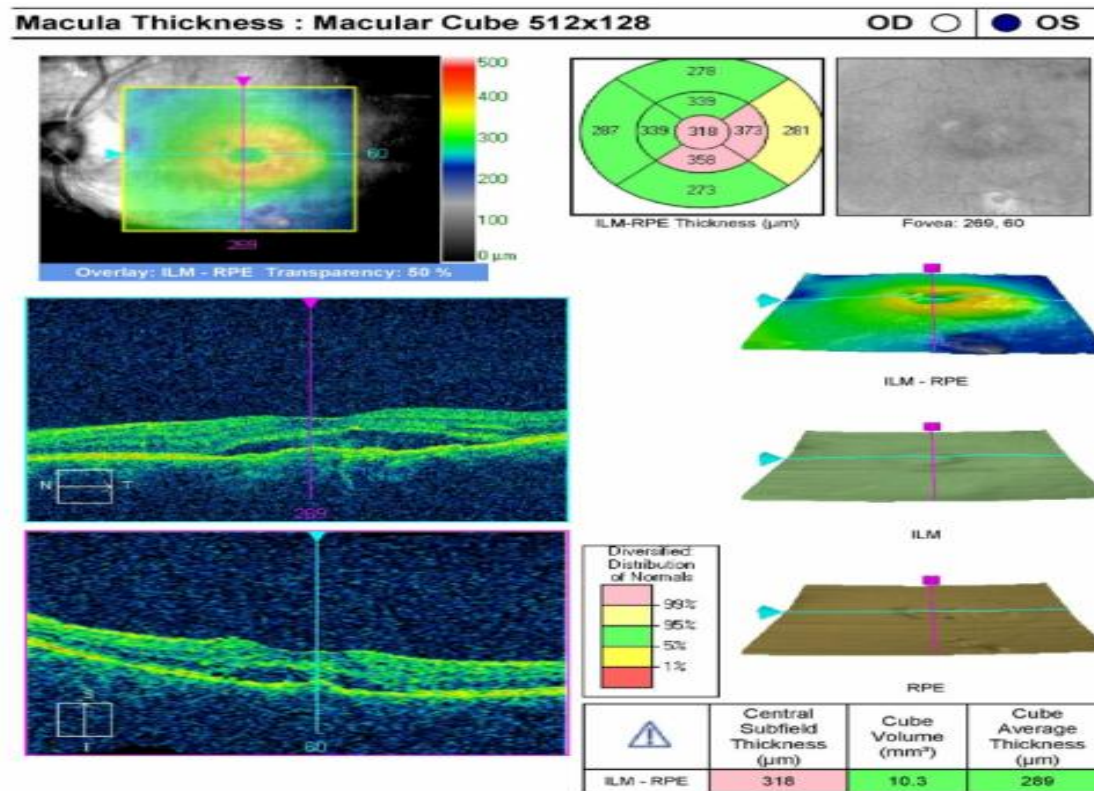


Table 4. Macular thickness

Stage of Diabetic retinopathy	Macular thickness (μm)
No DR & Mild NPDR	180.2+/- 13.4
Moderate NPDR	310.4+/- 37.6
Severe NPDR	370.6+/- 159.6
Early PDR	404.4+/- 122.3



(a)



IV. Discussion

- Diabetic retinopathy is classified into nonproliferative diabetic retinopathy (NPDR) and proliferative diabetic retinopathy (PDR), NPDR is further classified into mild, moderate, and severe stages that may or may not involve the macula. PDR is classified into early and high-risk. The major causes of severe visual impairment are Proliferative diabetic retinopathy (PDR) and Diabetic macular edema (DME). Nearly all patients with Type 1 diabetes and >60% of patients with Type 2 diabetes are expected to have some form of retinopathy by the first decade of incidence of diabetes. DME can be cured if they were detected an early stage. However, due to ignorance and unawareness especially in rural areas, many people are suffering from DME, which eventually leads to irreversible blindness.
- Optical Coherence Tomography (OCT) is a rapid, non-invasive imaging modality that provides cross-sectional retina imaging and morphological tissue information. Retinal OCT image provides information about retinal internal structures and early symptoms of retinal disease. OCT can be used for detecting the diabetic macular edema (DME) region, the patients with diabetes require regular and repetitive retinal screening for early detection and to enhance the efficiency of diagnosis and decision-making, and early treatment. It seems to be the technique of choice for the early detection of macular edema and for the follow-up of Diabetic retinopathy.^[3,4,7]

V. Conclusion

Increased foveal and outer macular thickness in patients with moderate NPDR, severe NPDR, and early PDR was seen in this study. It helps in patient selection with Diabetes mellitus who can benefit from treatment, identify the mode of treatment, and guide its implementation. Helps in the follow-up of the patients during treatment to establish quantitative and qualitative responses to therapy.

References

- [1]. Lee R, Wong TY, Sabanayagam C. Epidemiology of diabetic retinopathy, diabetic macular edema and related vision loss. Eye and vision. 2015 Dec;2(1):1-25.
- [2]. Romero-Aroca P, Baget-Bernaldiz M, Pareja-Rios A, Lopez-Galvez M, Navarro-Gil R, Verges R. Diabetic macular edema pathophysiology: vasogenic versus inflammatory. Journal of diabetes research. 2016 Oct;2016.
- [3]. Virgili G, Menchini F, Casazza G, Hogg R, Das RR, Wang X, Michelessi M. Optical coherence tomography (OCT) for detection of macular edema in patients with diabetic retinopathy. Cochrane Database of Systematic Reviews. 2015(1).
- [4]. Pierro L, Rabiolo A. Emerging issues for optical coherence tomography. Management of Diabetic Retinopathy. 2017;60:28-37.
- [5]. Sun JK, Lin MM, Lammer J, Prager S, Sarangi R, Silva PS, Aiello LP. Disorganization of the retinal inner layers as a predictor of visual acuity in eyes with center-involved diabetic macular edema. JAMA ophthalmology. 2014 Nov 1;132(11):1309-16.

- [6]. Tau JW, Rogers SL, Kawasaki R, et al. Global prevalence and major risk factors of diabetic retinopathy. *Diabetes care*. 2012;35(3):556-564.
- [7]. Ahmadpour-Baghdadabad M, Manaviat M, Shojaoddiny-Ardekani A. Optical coherence tomography in diabetic macular edema: patterns and related risk factors. *Nepalese Journal of Ophthalmology*. 2013 Sep 25;5(2):190-4.
- [8]. Arevalo JF, Lasave AF, Arias JD, Serrano MA, Arevalo FA. Clinical applications of optical coherence tomography in the posterior pole: the 2011 José Manuel Espino Lecture-Part I. *Clinical Ophthalmology (Auckland, NZ)*. 2013;7:2165.
- [9]. Grover S, Murthy RK, Brar VS, Chalam KV. Normative data for macular thickness by high-definition spectral-domain optical coherence tomography (spectralis). *American journal of ophthalmology*. 2009 Aug 1;148(2):266-71.
- [10]. Diabetic Retinopathy Clinical Research Network. Relationship between optical coherence tomography-measured central retinal thickness and visual acuity in diabetic macular edema. *Ophthalmology*. 2007 Mar 1;114(3):525-36.
- [11]. Panozzo G, Gusson E, Parolini B, Mercanti A. Role of OCT in the diagnosis and follow up of diabetic macular edema. In *Seminars in ophthalmology* 2003 Jan 1 (Vol. 18, No. 2, pp. 74-81). Taylor & Francis.
- [12]. Hee MR, Puliafito CA, Wong C, Duker JS, Reichel E, Rutledge B, Schuman JS, Swanson EA, Fujimoto JG. Quantitative assessment of macular edema with optical coherence tomography. *Archives of ophthalmology*. 1995 Aug 1;113(8):1019-29.
- [13]. Santos AR, Costa MÂ, Schwartz C, Alves D, Figueira J, Silva R, Cunha-Vaz JG. Optical coherence tomography baseline predictors for initial best-corrected visual acuity response to intravitreal anti-vascular endothelial growth factor treatment in eyes with diabetic macular edema: the CHARTRES Study. *Retina*. 2018 Jun 1;38(6):1110-9.

Dr. L.ASHA, et. al. "Study of Macular Thickness by Using Optical Coherence Tomography in Diabetic Patients." *IOSR Journal of Dental and Medical Sciences (IOSR-JDMS)*, 22(2), 2023, pp. 28-32.