

A Morphometric Study of Foramen Ovale in Rajasthan

Dr Pratima Jaiswal¹, Ankush Asopa²
Dr Aarushi Jain³, Dr Kalpana Makhija⁴, Pratik Pratihari⁵,
Mayanka Saxena⁶,

¹Sr Professor, Department of Anatomy, Government Medical College, Kota

²PG resident 3rd year, Department of anatomy, Government Medical College, Kota

³Professor and Head, Department of Anatomy, Government Medical College, Kota

⁴Associate Professor, Department of Anatomy, Government Medical College, Kota

⁵PG resident 3rd year, Department of anatomy, Government Medical College, Kota

⁶PG resident 2nd year, Department of anatomy, Government Medical College, Kota

Abstract

Background: Foramen ovale and foramen spinosum are associated with the greater wing of sphenoid bone. The former is passage to mandibular nerve, the accessory meningeal artery, the lesser petrosal nerve and the emissary vein while the latter gives passage to middle meningeal artery, middle meningeal vein. It has been noted that both foramina exhibit noticeable variations in size, shape, and dimensions. The awareness of these differences is crucial for the concerned experts doing therapeutic interventions in these regions. The current study represents a modest effort to offer morphometric information and to evaluate variances in both the foramina.

Material and Methods: Study was done on a total of 35 dry skulls, irrespective of age and sex. Transverse and anteroposterior diameters were measured with a digital Vernier caliper and a screw-adjusted compass.

Results: Shape of the foramen ovale was oval in 66.67% while 30.43% almond, 1.45% slit like 1.45% irregular shaped. Foramen spinosum were round, oval, almond, irregular and pinhole shaped in 37.68%, 8.69%, 4.34% and 1.45% respectively. 6 (8.96%) Foramen ovale had accessory growth as bony plate, spine and tubercle, while foramen spinosum showed spine (10.14%), bony plate (5.79%), projecting tubercle (2.89%) and bony spur (1.45%) as an outgrowth. The mean thickness of the bony bar between the two foramina was observed to be 2.4 ± 0.94 mm on right side and 2.27 ± 0.85 mm on left side.

Conclusion: Most observed shape of foramen ovale was oval and that of foramen spinosum was round in present study. Most common accessory growth in foramen ovale was bony plate followed by spine and tubercle. While spine was most observed accessory outgrowth in foramen spinosum followed by bony plate, tubercle and bony spur.

Keywords: ovale, mandibular nerve, foramen of Vesalius, canalis innominatus, trigeminal rhizotomy.

Date of Submission: 11-03-2023

Date of Acceptance: 25-03-2023

I. INTRODUCTION

The medial aspect of the greater wing of the sphenoid presents a crescent of foramina of which only the most posterior two, foramen ovale (FO) and foramen spinosum (FS), can be viewed on the basal aspect. The foramen ovale lies medial to the foramen spinosum and lateral to the foramen lacerum on the infratemporal surface of the greater wing of the sphenoid bone. It transmits the mandibular division of the trigeminal nerve, the lesser petrosal nerve, the accessory meningeal branch of the maxillary artery and an emissary vein that connects the cavernous venous sinus to the pterygoid venous plexus in the infratemporal fossa. Occasionally, the foramen ovale and foramen spinosum are confluent or the posterior edge of the foramen spinosum may be defective¹.

Sometimes an accessory foramen called foramen of Vesalius is variably present anteromedial to foramen ovale and lateral to foramen rotundum and vidian canal. In such case, it transmits emissary vein that connects intracranial cavernous sinus to the extracranial pterygoid venous plexus. On rare occasions, an accessory foramen, canalis innominatus of Arnold exists between foramen ovale and foramen spinosum and it transmits lesser petrosal nerve.

Some authors have linked abnormal morphology of the FO with ossified ligaments of pterygospinous (ligament of Civinini) and pterygoalar (ligament of Hyrt)^{2,3}.

Foramen ovale serves as an entry point in surgical trigeminal rhizotomy procedures either by percutaneous⁴, balloon compression or radiofrequency ablation, to approach mesial temporal lobe for placing electrodes in a suspected focal epilepsy patient⁵.

II. MATERIAL AND METHODS

Study was done on 35 dry skulls (69 sides, 35 left and 34 right) irrespective of sex and age, in the departments of anatomy of Government Medical College, Kota and Jhalawar Medical College, Jhalawar. Measurements were done extracranially using digital Vernier caliper of 0.01 mm precision and screw adjusted compass. Anteroposterior diameter was considered as length (L) while mediolateral diameter as breadth (B). Area of the foramina were calculated using formula -

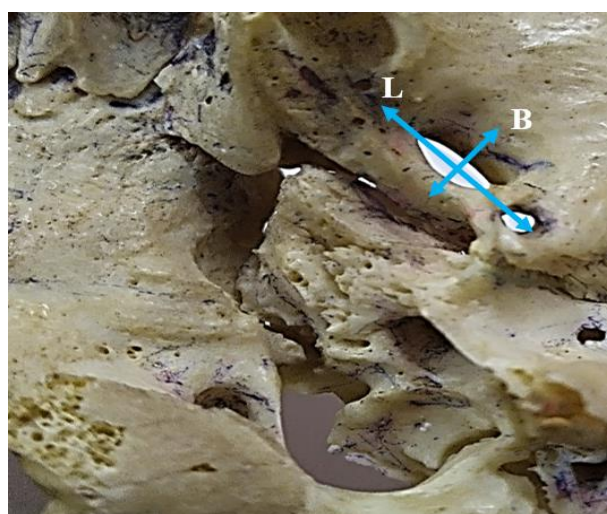


Figure 1 and 2: extracranial measurement of foramen ovale

$$A = \frac{\pi}{4} L \times B. ^6$$

Where L= length/AP diameter; B= breadth/ mediolateral diameter.

Observations were photographed using 48-megapixel digital camera. Bony outgrowths were noted in the form of spine, tubercle, plate or spur.

RESULTS

Variables		Sidewise			Overall		
		Right	Left	p value	Maximum	Minimum	Mean±SD
Length(mm.)	Mean±SD	7.03±1.17	6.88±1.11	0.295	10.37	4.48	6.96±1.14
Breadth(mm.)	Mean±SD	3.62±0.74	3.65±0.63	0.429	5.78	2.54	3.64±0.68
Area(mm ²)	Mean±SD	20.06±5.35	19.97±5.92	0.476	38.78	10.52	18.77±5.61

The present study included a total of 69 sides (35 left and 34 right) in 35 adult dry skulls. The mean length observed on right side (7.03±1.17 mm) was higher than that on left side (6.88±1.11 mm). The maximum and minimum length in present study were observed on right side as 10.37 mm and 4.48 mm respectively, whereas maximum breadth of 5.78 mm on right side and minimum breadth 2.54 mm was noted on left. Maximum and minimum area of the foramen were 38.78 mm² on left side and 10.52 mm² on right side as depicted in table 1. *p*-values were obtained for all three parameters which was higher (>0.05). Hence, in present study we could not hypothesize significant correlation between left and right sides. Most common shape of the foramen ovale was observed to be oval in 66.67% followed by almond (30.43%), slit like (1.45%) and irregular shaped (1.45%) as evident from table-2. Foramen ovale had accessory growth as bony plate (Figure 5), spine and tubercle (figure 6 and figure 7). Foramen Vesalius was observed in 4.35 % cases in present study, unilaterally on left side in 1.45 % and bilaterally in 2.90 % (figure 4).

Shape	Right(n=34)	Left(n=35)	Total(n=69)
Oval	19	27	46 (66.67%)
Almond	13	8	21 (30.43%)
Slit shaped	1	0	1 (1.45%)
Irregular	1	0	1(1.45%)
Round	0	0	0

Bony outgrowths	Right(n=34)	Left(n=35)	Total(n=69)
Bony Plate	2	4	6 (8.69%)
Spine	3	1	4 (5.79%)
Tubercle	2	2	4 (5.79%)

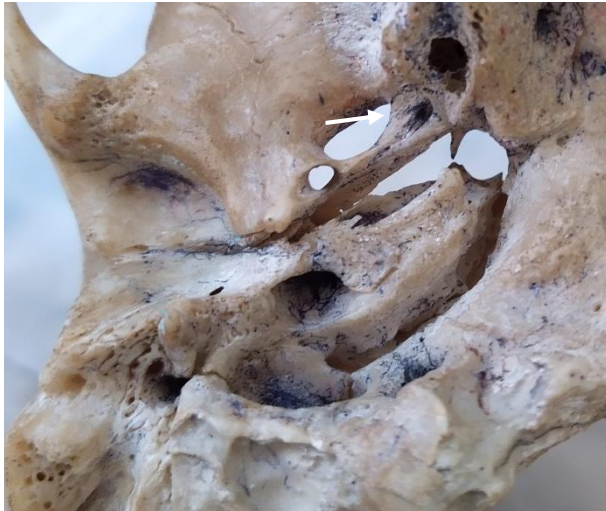


Figure 3: almond shaped foramen ovale

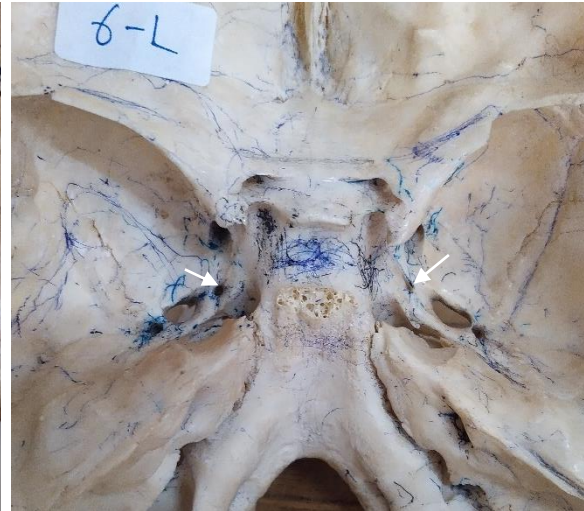

Figure 4: bilaterally present foramen of Vesalius

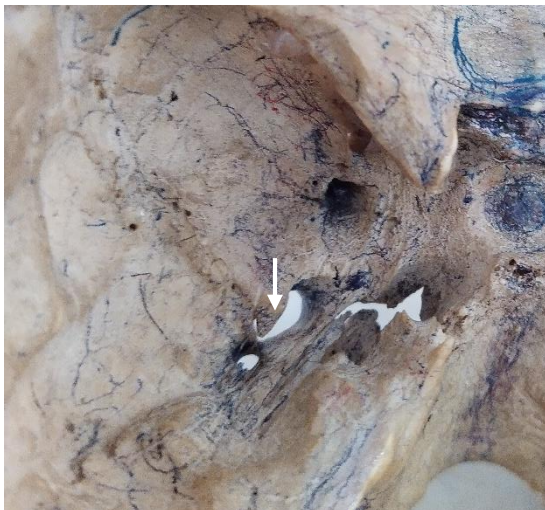

Figure 5: bony plate obscuring passage of foramen ovale marked with arrow



Figure 6: a spine projecting into foramen ovale

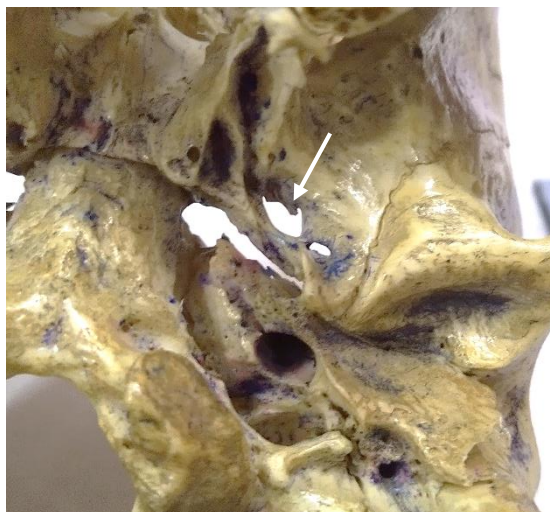

Figure 7: tubercle projecting into foramen ovale marked with arrow

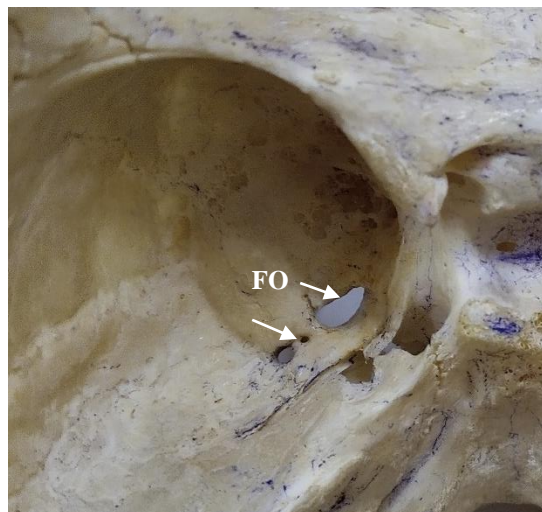


Figure 8: canalis innominatus (white arrow) posterolateral to foramen ovale (FO)

III. DISCUSSION

Table 8: comparison of dimensions of foramen ovale with previous studies

Authors	No. of skulls	Mean length (mm)				Mean width (mm)	
		Right	Left	Right	Left		
Ray et al. ⁹ (2005)	35	7.46	7.01	1.02	3.29		
Daimi et al. ¹¹ (2011)	90	6.6	6.26	3.7	3.34		
Chandra P et al. ⁸ (2013)	50	7.27	7.46	3.18	3.21		
Patel et al. ¹⁰ (2014)	100	6.6	6.5	3.6	3.5		
Prakash KG et al. ⁷ (2019)	124	7.64	7.56	5.12	5.24		
Vidya CS ¹² (2019)	40	7.45	6.8	6.0	5.6		
Present study	35	7.03	6.88	3.62	3.65		

Prakash KG et al⁷ obtained bilateral higher mean values for both length (7.64 mm on right and 7.56 mm on left) as depicted in table 8. In the present study, the mean length of the foramen ovale was 7.03 ± 1.17 mm on the right side, and 6.88 ± 1.11 mm on the left side. The mean width was 3.62 ± 0.74 mm on the right side, and 3.65 ± 0.63 mm on the left side. Therefore, length was higher on right side and width was higher on left side. Prakash K G et al., Chandra P et al⁸ and Ray et al⁹ had similar observation in their study. Ray et al. noted marked difference in mean breadth, which was 3.29 mm on left as compared to 1.02 mm on right. A study by Patel et al¹⁰ conducted on 100 dry skulls in Gujarat yielded lower mean values for length and breadth. He observed mean length of the foramen ovale was 6.6 mm on the right side, and 6.5mm on the left side. The mean width was 3.6 mm on the right side, and 3.5 mm on the left side.

Daimi et al.¹¹ in their study on 90 adult skulls documented the mean length of foramen ovale as 6.6 mm on right side and 6.26 mm on left side while mean width as 3.7 mm and 3.34 mm on right side and left side respectively.

Higher dimensions for mean breadth were documented by Vidya CS as 6 mm on right side and 5.6 mm on left side¹².

Shapes of foramen ovale

Table 9: Foramen ovale: Comparison of shapes with previous studies

Authors	No. of skulls	Oval	Almond	Slit shaped	Irregular	D-shaped	Round
Ray et al. ⁹ (2005)	35	61.4%	34.3%	1.4%	-	-	2.9%
Wadhwa et al. ¹³ (2012)	30	70%	15%	-	-	-	10%
Chandra P et al. ⁸ (2013)	50	68%	30%	-	-	1%	1%
Saurjyanjan D et al. ¹⁴ (2018)	50	70%	18%	-	-	-	8%
Present study	35	66.67%	30.43%	1.45%	1.45%	-	-

In present study, most common shape of the foramen ovale observed was oval in 66.67%, which is similar to the observations made by other authors such as Wadhwa et al¹³ Chandra et al⁸, Saurjyanjan D et al¹⁴ and Ray et al⁹ as 70%, 68%, 70% and 61.4% respectively. Second common observation was almond shaped foramen ovale (30.43%) which is in line with observations by Chandra P et al and Ray et al as 30% and 34.3% respectively. Slit shaped foramina were also noted in present study and study by Ray et al as well.

Table 10: Comparison of bony outgrowth with previous studies

Authors	No. of skulls	Bony plate	Spine	Tubercle	Septa
Mishra S R et al ¹⁶ (2018)	50	-	4%	-	3%
Sink Z et al ¹⁷ (2023)	126+15 halves	13%	9%	8%	-
Present study	35	8.69%	5.79%	5.79%	-

According to James et al., spine, spur, tubercle, bony plate is various types of bony outgrowths that occur during the development between its first appearance and perfect ring formation¹⁵. In present study accessory growth related to foramen ovale were observed to be bony plate (8.69%), spine (5.79%) and tubercle (5.79%). While Mishra S R et al observed spine (4%) and septa (3%)¹⁶. A Slovenian study by Sink Z et al.¹⁷ on 267 foramen ovale documented incidence of bony plate, spine and tubercle to be 13%, 9 % and 8 % respectively. Presence of bony spicule or stenosis may impart compression over mandibular nerve and produce clinical symptoms¹⁸. In a study on Indian patients of trigeminal neuralgia, who were treated with percutaneous trigeminal ganglion balloon compression, the needle could be introduced easily in all patients except one, because the patient had stenosis of the foramen ovale and the needle just fitted in the foramen¹⁹. Confluence of the foramen ovale with other neighboring foramina was not observed in present study.

Incidence of foramen Vesalius has been varied to a wider extent. Sharma NA²⁰ and Berge JK²¹ found this in 62 % and 59 % cases respectively in their study. Foramen Vesalius was observed in 4.35 % cases in present study.

The incidence of the canalis innominatus of Arnold was found to be 32 %, 20% and 16.3% by Sharma NA²⁰, Sondheimer²² and Ginsberg et al.²³ respectively. While in present study it was present only in 1.45 % cases.

Precise knowledge of the dimensions is crucial for neurologists and anesthetists performing surgical and diagnostic procedures such as EEG analysis of seizures by placing electrodes. Diagnostic accuracy of aspiration biopsy of cavernous sinus tumors through the foramen ovale has been found to be 84% in a study done by M Sindou²⁴ et al. Chong VF et al reported foramen ovale to be the most common route of spread of nasopharyngeal carcinoma with the frequency of 34 %²⁵. Gasserian ganglion block is an established treatment for trigeminal neuralgia. Though commonly considered as oval-shaped, procedures involving cannulation of foramen ovale, may occasionally get complicated by anatomical variation of the FO such as almond, banana, D shape, pear and triangular²⁶.

IV. CONCLUSION

The present study was conducted to provide morphometric data regarding the foramen ovale. Trigeminal rhizotomy requires precise knowledge of foramen ovale as the foramen, in some individuals presents with tubercles or bony plates Therefore, the patency of the foramen ovale is very important for the procedure. In case of stenosis of foramen ovale as is seen in foramen with tubercles, the surgeries procedures are difficult. For surgical procedures in the middle cranial fossa, the knowledge about the variations of these foramina should be taken into account and the present data will suffice for that purpose. For medical practitioners this data will be of significance in dealing the cases of trigeminal neuralgia and will aid in diagnosing various vascular lesions in cranial cavity. This data will add to the knowledge of clinicians as well as anatomists.

REFERENCES

- [1]. Standing S. In Gray's Anatomy The Anatomical Basis of Clinical Practice. 41st ed.; 2016. p. 1093-4.
- [2]. Emril DR, Ho KY. Treatment of trigeminal neuralgia: Role of radiofrequency ablation.. J Pain Res. 2010; 3: 249-54.
- [3]. Tubbs RS, May WR Jr., Apaydin N, Shoja MM, Shokouhi G, Loukas M, et al. Ossification of ligaments near the foramen ovale: An anatomic study with potential clinical significance regarding transcortical approaches to the skull base. Neurosurgery. 2009; 65: 60-4.
- [4]. Gözil R, Keskin S, Calgüner E, Tunç E, Kadioğlu D, Sevim A, et al. Neurocranial morphology as determined by asymmetries of the skull base. J Anat. 1996; 189: 673-5.
- [5]. Velasco, T.R., Sakamoto, A.C., Alexandre, V., Jr, Walz, R., Dalmagro, C.L., Bianchin, M.M., Araújo, D., Santos, A.C., Leite, J.P., Assirati, J.A. and Carlotti, C., Jr. Foramen Ovale Electrodes Can Identify a Focal Seizure Onset When Surface EEG Fails in Mesial Temporal Lobe Epilepsy. Epilepsia. 2006; 47: 1300-7.
- [6]. Gerber AM. Improved visualization of the foramen ovale for percutaneous approaches to the gasserian ganglion: Technical note. J Neurosurg. 1994; 80: 156-9.
- [7]. Prakash KG, Saniya K, Honnegowda TM, Ramkishore HS, Nautiyal A. Morphometric and Anatomic Variations of Foramen Ovale in Human Skull and Its Clinical Importance. Asian Journal of Neurosurgery. 2019 Oct-Dec; 14(4): 1134-7.
- [8]. Chandra P X, Bilodi A S. A study on Foramen Ovale in Human skulls. Indian Journal of Medical case reports. 2013 Oct-Dec; 2(4): 65-76.
- [9]. Ray B, Gupta N, Ghose S. Anatomic variations of foramen ovale. Kathmandu Univ Med J (KUMJ). 2005; 3: 64-8.
- [10]. Patel R, Mehta C D. Morphometry of Foramen Ovale at base of skull in Gujarat. IOSR Journal of Dental and Medical Sciences. 2014 Jan; 13(6): 26-30.
- [11]. Daimi SR, Siddiqui AU, Gill SS. Analysis of foramen ovale with special emphasis on pterygoalar bar and pterygoalar foramen. Folia Morphol (Warsz). 2011; 70:149–153. [PubMed: 21866524].

- [12]. Vidya CS, Shetty H. Anthropometric Evaluation of Foramen Ovale in Adult Dry Skulls of the Mysuru-based Population. *J Morphol Sci.* 2019; 36: 14-6.
- [13]. Wadhwa A, Sharma M, Kaur P. ANATOMIC VARIATIONS OF FORAMEN OVALE – CLINICAL IMPLICATIONS. *Int j Basic and Applied Med Sci.* 2012; 2(3): 21-4.
- [14]. Saurjyaranjan D, Sreepreeti C, Gyanaranjan N. AN ANATOMICAL STUDY OF FORAMEN OVALE WITH CLINICAL IMPLICATIONS. *Int J Anat Res.* 2018; 6(4.2): 5921-5.
- [15]. James TM, Presley R and Steel FL. The foramen ovale and sphenoidal angle in man. *Anatomy and Embryology.* 1980; 160: 93-104.
- [16]. Mishra SR, Sushobana, Singh S, Singh R, Gaharwar A. Morphometric and topographic study of foramen ovale in Indian skulls. *Malays J Med Biol Res.* 2018; 5(2): 75-80.
- [17]. Šink, Ž, Umek N, Alibegović, A, Cvetko E. Sphenoidal Foramen Ovale in the Slovenian Population: An Anatomical Evaluation with Clinical Correlations. *Diagnostics.* 2023; 13: 962.
- [18]. Poornima B, Sampada PK, Mallikarjun M, Santhosh BS. Morphometric and morphological study of foramen ovale and foramen spinosum in dry human skull bones. *Indian J Clin physiol.* 2017;4(1):59-62. 2017; 4(1): 59-62.
- [19]. M N. Percutaneous trigeminal ganglion balloon compression : experience in 40 patients. *Neurology India.* 2000; 48: 330-2.
- [20]. Sharma NA, Garud RS. Morphometric evaluation and a report on the aberrations of the foramina in the intermediate region of the human cranial base: A study of an Indian population. *Eur J Anat.* 2011; 15(3): 140-9.
- [21]. BERGE JK, BERGMAN RA. Variations in size and in symmetry of foramina of the human skull. *Clin Anat.* ; 14: 406-13.
- [22]. Sondheimer FK. Basal foramina and canals. *Radiology of the skull and brain.* 1971.
- [23]. Ginsberg L E, Pruett S W, Chen M Y M, Elster AD. Skull-base foramina of the middle cranial fossa: Reassessment of normal variation with high-resolution CT. *AJNR. American journal of neuroradiology.* 1994; 15: 283-91.
- [24]. Sindou M, Chavez JM, Saint Pierre G, et al. Percutaneous biopsy of cavernous sinus tumours through the foramen ovale. *Neurosurgery.* 1997; 40: 106-11.
- [25]. Chong VF, Fan YF, Khoo JB. Nasopharyngeal carcinoma with intracranial spread: CT and MR characteristics. *J Comput. Assist Tomogr.* 1996; 20: 563-9.
- [26]. Zdilla MJ, Fijalkowski KM. The Shape of the Foramen Ovale: A Visualization Aid for Cannulation Procedures. *J Craniofac Surg.* 2016 Dec 23. doi: 10.1097/SCS.0000000000003325. [Epub ahead of print] PubMed PMID: 28027173.