

Mode of Presentation & Echocardiographic Analysis for PBPV

Bhuiyan MNI*¹, Yasmin M², Khan MAA³, Hossain M⁴, Das BK⁵, Tanjin I⁶, Hossain KM⁷

¹Dr. Mohammad Nazmul Islam Bhuiyan, Pediatric Cardiologist, Combined Military Hospital, Dhaka, Bangladesh

²Dr. Mahamuda Yasmin, Junior Consultant, Reproductive Endocrinology & Infertility, Bangabandhu Sheikh Mujib Medical University, Dhaka, Bangladesh

³Dr. Md. AshfaqueAhemmed Khan, Pediatric Cardiologist, Combined Military Hospital, Dhaka, Bangladesh

⁴Dr. Mofazzol Hossain, FCPS Part -II Trainee, Department of Pediatric Cardiology, Combined Military Hospital, Dhaka, Bangladesh

⁵Dr. Bijoy Kumar Das, FCPS Part -II Trainee, Department of Pediatric Cardiology, Combined Military Hospital, Dhaka, Bangladesh

⁶Dr. Ishrat Tanjin, FCPS Part -II Trainee, Department of Pediatric Cardiology, Combined Military Hospital, Dhaka, Bangladesh

⁷Dr. Khandoker Mohammad Hossain, Pediatrician, Combined Military Hospital, Dhaka, Bangladesh

Corresponding Author: Dr. Mohammad Nazmul Islam Bhuiyan, Pediatric Cardiologist, Combined Military Hospital, Dhaka, Bangladesh

E-mail: n.nazmul101130@gmail.com

ORCID ID: <https://orcid.org/0000-0001-9280-7714>

Abstract

Introduction: Congenital heart disease (CHD) is responsible for nearly one-third of all congenital anomalies. The prevalence of CHD is 9.410 per 1000 live births, which has been increasing since 1970. The prevalence of congenital pulmonary stenosis (PS) is 8-10% (about 1 per 2000 live births worldwide) of all CHD including valvular, subvalvular, and supra-valvular ones. However, this prevalence is slightly higher in Asian countries compared to Europe and the United States. PS can be present isolated or associated with other CHD, such as Ventricular Septal Defect (VSD), Patent Foramen Ovale, Atrial Septal Defect(ASD), and Persistent Ductus Arteriosus (PDA). This study aimed to analyze the mode of presentation & echocardiographic analysis for Percutaneous Balloon Pulmonary Valvuloplasty (PBPV).

Methods: This hospital-based prospective observational study was conducted in the Department of Paediatric Cardiology Combined Military Hospital (CMH), Dhaka from January to December 2021. 0-18 years aged 50 population with PS who were referred to the Paediatric Cardiology Department of CMH Dhaka during the study period were selected as study subjects as per inclusion criteria. The purposive Sampling technique was used in this study. Data were collected with a predesigned standard data collection sheet. Statistical significance was set as a 95% confidence level at a 5% acceptable error level. Categorical variables were expressed as frequency and percentages. Mean, standard deviation, and/or medians with interquartile ranges were used to express the continuous variables. Collected data were analyzed using SPSS Version 24. Written informed consent was taken from every parent. Ethical clearance was taken from the Ethics Review Committee of CMH Dhaka for conducting the study.

Result: Out of 50 cases 3(6%) are neonates, 7(14%) are infants, 27 (54%) are 1-5 years aged and 13(26%) are more than 5 years aged. This study has found male predominance (30,60%) with a male-female ratio of 3:2.26(52%) were incidentally diagnosed, 15(30%) presented with exertional dyspnea, 3(6%) presented with chest pain, and 6(12%) presented with cyanosis as critical PS (3 patients were neonate and another 3 patient diagnosed beyond neonatal age.) On diagnosis, severe PS was found in 27(54%) cases (PS gradient of more than 70 mm of Hg) and moderate PS was found in 23(46%) cases PS gradient of more than 50 mm of Hg but less than

70 mm of Hg). RV Function: All the patient's RV function was good as evidenced by TAPSE within normal range.

Conclusion: Among the study subjects, more than half of patients were diagnosed incidentally, followed by the most common clinical presentations were dyspnea, cyanosis, and chest pain. Most of the patients presented with severe PS, followed by moderate PS on echocardiographic analysis.

Keywords: Pulmonary Stenosis, Echocardiography, PBPV, Dyspnea

Date of Submission: 26-02-2023

Date of Acceptance: 10-03-2023

I. INTRODUCTION

PS could be three types (a) valvular stenosis (most common), (b) supra-valvular and (c) sub-valvular. Although surgical intervention has proven to be the ultimate curative method, recent studies indicate that transcatheter-based techniques may provide a suitable and effective alternative to open-heart surgeries. In 1948, Sellors first performed a successfully closed Trans ventricular instrumental pulmonary valvotomy. [1] Then Swan and colleagues did surgical correction of PVS with intact ventricular septum by an open technique with circulatory arrest and hypothermia in about 1953. [2] The transcatheter intervention has its origin back in 1956, introduced by Rubio and Limon. [3] In 1979, Semb et al employed a balloon-tipped angiographic (Berman) catheter to produce a rupture of pulmonary valve commissures by rapidly withdrawing the inflated balloon across the PV. [4] In 1982 Kan et al, percutaneous balloon pulmonary valvuloplasty (PBPV) was performed on an 8-year-old child under fluoroscopic guidance to abate PVS by the radial forces of balloon inflation while a balloon catheter was positioned across the pulmonary valve. [5] Since then, it has been practiced as the first-line treatment option for PVS worldwide because of its safety and effectiveness. In Bangladesh in 1999 first ever Balloon valvuloplasty (BVP) for PS was done in Combined Military Hospital Dhaka(Fig-1). [6] In 2016, Wang et al introduced the first- in- human PBPV under echocardiographic guidance only. [7] Pulmonary stenosis (PS) refers to a dynamic or fixed anatomic obstruction to flow from the right ventricle (RV) to the pulmonary arterial vasculature, which leads to RV pressure overload that in turn causes increased contractility and dilation and results in increased wall stress and compensatory RV hypertrophy. [8] The pulmonary commissures are fused, and the valve is domed and has a small central or eccentric opening; there is post-stenotic dilatation of the main pulmonary artery. The pulmonary valve is occasionally bicuspid. PS occurs in 8% to 10% of all congenital heart diseases (CHD)[9] including valvular, supra-valvular and subvalvular. PS is often associated with other CHDs, such as Tetralogy of Fallot (TOF), Single Ventricle, Ventricular Septal Defect, Patent Foramen Ovale, Atrial Septal Defect, Persistent Ductus Arteriosus, and others. PS may be valvular, subvalvular (infundibular) or supra-valvular. [10] In valvular PS, the pulmonary valve is thickened, with fused or absent commissures and a small orifice. Although the RV is usually normal in size, it is hypoplastic in infants with critical PS (with a nearly atretic valve). Dysplastic valves-consisting of thickened, irregular, immobile tissue and a variably small pulmonary valve annulus and are frequently seen with Noonan's syndrome. [11] Isolated infundibular PS is rare but may be seen as part of the Tetralogy of Fallot (TOF). Supra-valvular PS (stenosis of the pulmonary arteries) is usually associated with a syndrome such as Williams's syndrome, Noonan's syndrome, Alagille syndrome, Ehlers-Danlos syndrome, Silver-Russell syndrome, or congenital rubella syndrome. [10] Percutaneous Balloon Pulmonary Valvuloplasty(PBPV)was first done in 1982 by Kan et al in an eight years old child under fluoroscopic guidance. [5] Since then it is the gold standard treatment for moderate to severe PS. In Bangladesh, it was first performed in 1999 at CMH Dhaka. [12] Nowadays it is performed under echo guidance. [7] But in our lab, we are practicing under fluoroscopy. The main disadvantage of fluoroscopy is radiation injury. Surgery is indicated if balloon valvuloplasty is unsuccessful, or contraindicated and associated with infundibular stenosis and right ventricular outflow tract(RVOT) muscle bundle. The balloon procedure carries an extremely low risk, is painless, less costly than surgery, and shorter hospital stay. The outcome is good in 85% of cases.

OBJECTIVE

General Objective

- To see the mode of presentation & echocardiographic analysis for PBPV

Specific Objectives

- To know the age and gender distribution of the patients
- To analyze valve morphology
- To assess pressure gradient across PV

II. METHODS

This hospital-based prospective observational study was conducted in the Department of Paediatric Cardiology Combined Military Hospital (CMH), Dhaka from January to December 2021. 0-18 years aged 50 population with PS who were referred to the Paediatric Cardiology Department of CMH Dhaka during the study period were selected as study subjects as per inclusion criteria. The purposive Sampling technique was used in this study. The study followed the guidelines of the Helsinki declaration. Detailed history, thorough physical examination, and relevant investigations are done. Vulvar PS was confirmed by echocardiography. Study children were undergone Interventional procedures after full filling the inclusion and exclusion criteria. Data were collected with a predesigned standard data collection sheet. Categorical variables were expressed as frequency and percentages. Mean, standard deviation, and/or medians with interquartile ranges were used to express the continuous variables. Collected data were analyzed using SPSS Version 24. Written informed consent was taken from every parent. Ethical clearance was taken from the Ethics Review Committee of CMH Dhaka for conducting the study.

Inclusion Criteria

- 0-18 years old patient with Valvular Pulmonary Stenosis.
- Echocardiographic gradient of PS >50 mm of Hg.
- Patients who had given consent to participate in the study.

Exclusion Criteria

- Child, who had any medical or surgical intervention.
- Pulmonary stenosis associated with other complex CHD, Tetralogy of Fallot (TOF), Transposition of Great Arteries(TGA), Tricuspid Atresia(TA), Single Ventricle, etc., but not associated with simple CHD like-ASD, PDA which are amenable to catheter intervention.
- Patients who did not give consent to participate in the study.

III. RESULTS

Table 1: Age distribution of respondents (N=50)

Age	N	%
Neonate (0-1 month)	3	6.0
Infant (1 month- 1 year)	7	14.0
Child (1-5 years)	27	54.0
> 5 years	13	26.0
Total	50	100.0

Out of 50 cases, 3(6%) are neonates,7(14%) are infants, 27 (54%) are 1-5 years aged, and 13(26%) are more than 5 years aged. [Table 1]

Table 2: Gender distribution of study subjects (N=50)

Gender	N	%
Male	30	60.0
Female	20	40.0
Total(n)	50	100.0

In this study, we have found male predominance (30,60%) with a male-female ratio of 3:2. [Table 2]

Table 3: Mode of presentation of the study respondents (N=50)

Modes	N	%
Incidental/Screening	26	52.0

Dyspnoea	15	30.0
Chest pain	03	06.0
Critical PS	06	12.0

Out of 50 cases 26(52%) were incidentally diagnosed, 15(30%) presented with exertional dyspnea, 3(6%) presented with chest pain, and 6(12%) presented with cyanosis as critical PS (3 patients were neonate and another 3 patient diagnosed beyond neonatal age. [Table 3]

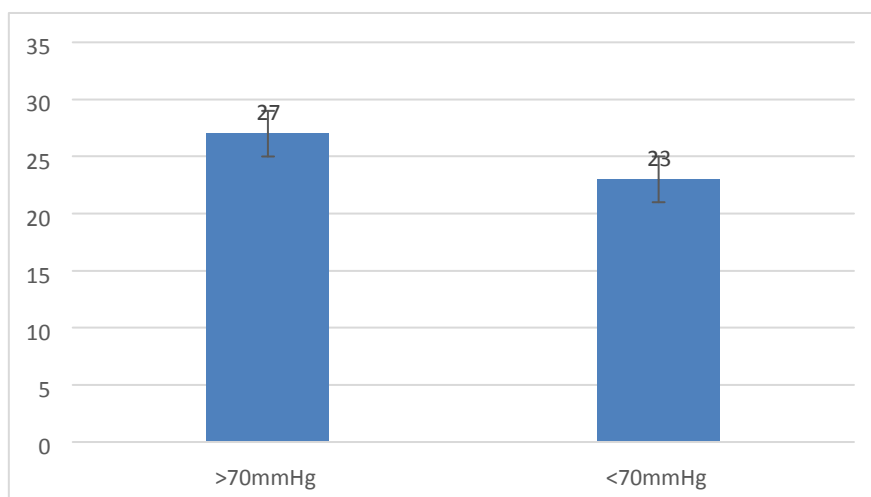
Echocardiographic Analysis:

Table 4: Distribution of patients according to valve morphology. (N=50)

Valve morphology	Number	Percentage
Dysplastic	08	16%
Doming	40	80%
Normal	02	04%
Total	50	100%

Out of 50 cases 40(80%) were presented with doming PV, 8(16%) with dysplastic PV and 2(4%) were with normal PV. All 03 stenosed cases were in dysplastic PV. [Table 4]

Figure 1: Distribution of patients according to the pressure gradient across PV. (N=50)



On diagnosis, severe PS was found in 27(54%) cases(PS gradient of more than 70 mm of Hg) and moderate PS was found in 23(46%) cases PS gradient of more than 50 mm of Hg but less than 70 mm of Hg). RV Function: All the patient’s RV function was good as evidenced by TAPSE within normal range. [Figure 1]

IV. DISCUSSION

Out of 50 cases, 3(6%) are neonates,7(14%) are infants, 27 (54%) are 1-5 years aged, and 13(26%) are more than 5 years aged.In this study, we have found male predominance (30,60%) with a male-female ratio of 3:2 and the results were similar to another study. [13]Sex distribution of patientswas about equal, but in our study males were predominant. Growth and development in a patient with pulmonary stenosis are usually normal.[14]Out of 50 cases, 26(52%) were incidentally diagnosed, 15(30%) presented with exertional dyspnea, 3(6%) presented with chest pain, and 6(12%) presented with cyanosis as critical PS (3 patients were neonate and another 3 patient diagnosed beyond neonatal age.Out of 50 cases 40(80%) were presented with doming PV, 8(16%) with dysplastic PV and 2(4%) were with normal PV. All 03 restenosis cases were in dysplastic PV in

this study. A study from Iran[15] showed 57 % of patients had mild pulmonary regurgitation. Similarly, mild PR was noted in 55% of patients in Idrizi S et al study[16] while 34% of patients developed mild PR in the Qian X et al study. [17] The incidence of trivial and mild pulmonary valve regurgitation in the immediate post-PBPV period was 13(26%) in our study while there was not a single case of moderate or free pulmonary regurgitation. This study showed that the incidence of PR after PBPV is variable and depends on different factors like age, balloon annulus ratio, and morphology of the pulmonary valve. Sex distribution of patients was about equal, but in our study males were predominant. Growth and development in a patient with pulmonary stenosis are usually normal. [18] Balloon pulmonary valvuloplasty is a commonly performed procedure in many centers around the world as well as in Bangladesh. For congenital pulmonary valvular stenosis, it is a safe and effective procedure and it is the initial treatment of choice. We are performing this procedure in all age groups of patients with moderate to severe pulmonary valve stenosis at our Combined Military Hospital Dhaka since 1999. [12] The data on balloon pulmonary valvuloplasty in children and adolescent population is scanty in our part of the world. The use of a smaller diameter balloon may result in significant residual PS while the oversized balloon may not warrant good long-term results without complications. [19] This ratio is also an important factor in the immediate post-procedure outcome. [20] The PBPV is a very safe procedure with a low incidence of complications. Stanger P et al[21] in the VACA registry of 26 institutions reported only a 0.35 % major complications rate while a 0.24 % death rate from a total of 822 cases of balloon pulmonary valvuloplasty. There has been a high incidence of complications of the procedure in neonates, infants, and children[1] while most of the studies describe no major complications of PBPV in children, adolescents, or adult populations. [2][3]

Limitations of The Study

The study was conducted in a single hospital with a small sample size. So, the results may not represent the whole community.

V. CONCLUSION

This study concluded that, among the study subjects, more than half of patients were diagnosed incidentally, followed by the most common clinical presentations were dyspnea, cyanosis, and chest pain. Most of the patients presented with severe PS, followed by moderate PS on echocardiographic analysis.

Funding: No funding sources

Conflict of interest: None declared

Ethical approval: The study was approved by the Institutional Ethics Committee

VI. RECOMMENDATION

Pulmonary valve stenosis (PVS) is a common congenital cardiac lesion, in 1/1000 livebirths, the majority of patients having mild transvalvular gradients. Suspected infants should be followed up closely within the first year of life. Moreover, further studies should be conducted involving a large sample size and multiple centers in this regard.

REFERENCES

- [1] Sellors TH. Surgery of pulmonary stenosis: a case in which the pulmonary valve was successfully divided. *The Lancet*. 1948 Jun 26;251(6513):988-9.
- [2] Swan H, Zeavin I, Blount SG, Virtue RW. Surgery by direct vision in the open heart during hypothermia. *Journal of the American Medical Association*. 1953 Nov 21;153(12):1081-5.
- [3] Rubio V, Limon-Lason R. Treatment of pulmonary valvular stenosis and tricuspid stenosis using a modified catheter. In *Second World Congress on Cardiol* 1954 Sep (Vol. 2, pp. 205-10).
- [4] Semb BK, Tjønne S, Stake G, Aabyholm G. "Balloon valvulotomy" of congenital pulmonary valve stenosis with tricuspid valve insufficiency. *Cardiovascular radiology*. 1979 Nov 1;2(4):239-41.
- [5] Kan JS, White Jr RI, Mitchell SE, Gardner TJ. Percutaneous balloon valvuloplasty: a new method for treating congenital pulmonary valve stenosis. *New England Journal of Medicine*. 1982 Aug 26;307(9):540-2.
- [6] Begum NN, Bhuiyan NI, Khan MA, Alam MJ. Pattern of Intervention in Congenital Heart Disease: Single Centre Analysis of Cases over Five Years in Bangladesh. *Journal of Armed Forces Medical College, Bangladesh*. 2019;15(1):3-9.
- [7] Wang SZ, Ou yang WB, Hu SS, Pang KJ, Liu Y, Zhang FW, Zhang DW, Pan XB. First in human percutaneous balloon pulmonary valvuloplasty under echocardiographic guidance only. *Congenital heart disease*. 2016 Dec;11(6):716-20.
- [8] Ruckdeschel E, Kim YY. Pulmonary valve stenosis in the adult patient: pathophysiology, diagnosis and management. *Heart*. 2019 Mar. 105 (5):414-22
- [9] Allen HD, Driscoll DJ, Shaddy RE, Feltes TF. *Moss & Adams' heart disease in infants, children, and adolescents: including the fetus and young adult*. Lippincott Williams & Wilkins; 2013 May 30.
- [10] Park MK, Salamat M. *Park's Pediatric Cardiology for Practitioners E-Book*. Elsevier Health Sciences; 2020 Jul 10.
- [11] Kliegman RM, Nelson RM. *Textbook of pediatrics*. St. Louis: Mosby. th. 2004.
- [12] Fatema NN. Congenital and structural heart diseases: We are in progress *Bangladesh Heart Journal*. 2018 Dec 28;33(2):78-9.

- [13] Lindinger A, Schwedler G, Hense HW. Prevalence of congenital heart defects in newborns in Germany: Results of the first registration year of the PAN Study (July 2006 to June 2007). *Klinische Pädiatrie*. 2010 Sep;222(05):321-6.
- [14] Albert P. Rocchini MD, George C. Emmanouilides MD. Pulmonary stenosis in GCEmmanouilides, Hugh D Allen, Thomas A. Riernen Schneider, Hower P. 66Gutgessel, (editors). *Moss and Adams Heart disease in infant children and adolescents*, Fifth edition. Baltimore: William and Wilkins, 1995. PP 930 – 960
- [15] Behjati-Ardakani M, Forouzannia SK, Abdollahi MH, Sarebanhassanabadi M. Immediate, short, intermediate and long-term results of balloon valvuloplasty in congenital pulmonary valve stenosis. *Acta Medica Iranica*. 2013;324-8.
- [16] Idrizi S, Milev I, Zafirovska P, Tosheski G, Zimbakov Z, Ampova-Sokolov V, Angjuseva T, Mitrev Z. Interventional treatment of pulmonary valve stenosis: a single center experience. *Open access Macedonian journal of medical sciences*. 2015 Sep 15;3(3):408.
- [17] Qian X, Qian Y, Zhou Y, Yang X. Percutaneous pulmonary balloon valvuloplasty provides good long-term outcomes in adults with pulmonary valve stenosis. *J Invasive Cardiol*. 2015 Dec 1;27(12):E291-6.
- [18] Albert P. Rocchini MD, George C. Emmanouilides MD. Pulmonary stenosis in GCEmmanouilides, Hugh D Allen, Thomas A. Riernen Schneider, Hower P. 66Gutgessel, (editors). *Moss and Adams Heart disease in infant children and adolescents*, Fifth edition. Baltimore: William and Wilkins, 1995. PP 930 – 960
- [19] Van Der Linde D, Konings EE, Slager M. a., Witsenburg, M., Helbing, W. a., Takkenberg, JJM & Roos-Hesselink, JW Birth prevalence of congenital heart disease worldwide: A systematic review and meta-analysis. *J. Am. Coll. Cardiol*. 2011;58(21):2241-7.
- [20] Liu Y, Chen S, Zühlke L, Black GC, Choy MK, Li N, Keavney BD. Global birth prevalence of congenital heart defects 1970–2017: updated systematic review and meta-analysis of 260 studies. *International journal of epidemiology*. 2019 April 1;48(2):455-63.
- [21] Capucci A, Aschieri D. Public access defibrillation: new developments for mass implementation. *Heart*. 2011 Sep 15;97(18):1528-32.

XXXXX, et. al. "Mode of Presentation & Echocardiographic Analysis for PBPV." *IOSR Journal of Dental and Medical Sciences (IOSR-JDMS)*, 22(3), 2023, pp.48-52.