

## Duplication of Appendix in four cases of Congenital pouch colon: Case series

1. Dr Vinay Mathur

2. Dr Dileep Garg

3. Dr Umesh bahadur Singh

4. Dr Jitendra Grover (CORRESPONDING AUTHOR) Assistant professor Paerdiatric surgery, GRMC, Gwalior, MP, India.

---

**Abstract:** Congenital pouch colon is a very rare abnormality in which varying degree of pouch-like dilatation of dysplastic colon is associated with an anorectal malformation. The pouch usually communicate with a fistulous track with the genitourinary tract. CPC is classified on anatomic morphology into five types as per the length of the colon involved. In "Saxena and mathur Classification based on anatomic morphology the type 5 CPC shows double pouch colon with short normal interpositioned colon segment. CPC malformation is exclusively seen in Northern India, only (7.8%) cases of (CPC) have been reported outside India. However, recently there is increasing awareness about this rare anomaly and some cases are now reported from other parts of the world. The aim of this case series was to evaluate incidence of duplication of appendix associated with CPC in cases of ARM.

We report three cases of duplication of appendix associate with type I CPC out of 25 cases of pouch colon encountered in last three year duration. The medical record has been extracted and reviewed from all case records of cases of ARM managed in last 3 years. In all cases appendectomy was done along with bladder fistula ligation and pouchorrhaphy. All cases awaiting definitive repair for anorectal malformation at present. Congenital abnormalities of the appendix are rare and duplication of the appendix is an extremely rare condition, with a reported incidence of 0.004% of appendectomy specimens and found as an incidental finding during surgery.

---

Date of Submission: 26-02-2023

Date of Acceptance: 10-03-2023

---

### I. Introduction:

Aims & objectives: Congenital pouch colon is very rare abnormality worldwide (reported mainly in northern India) in which varying degree of pouch-like dilatation of colon is associated with an anorectal malformation. During last 4 years, we encountered 4 cases of cloaca with pouch having appendicular duplication (out of 6 cases of cloaca with pouch among 66 cases of pouch colon). Duplication of the appendix is an extremely rare condition, with a reported incidence of 0.004%, incidentally detected appendectomy specimen. There are only a few reported cases of this anomaly in association with pouch colon & cloaca. To the best of our knowledge this is first and largest case series of appendicular duplication associated with pouch colon & cloaca in India.

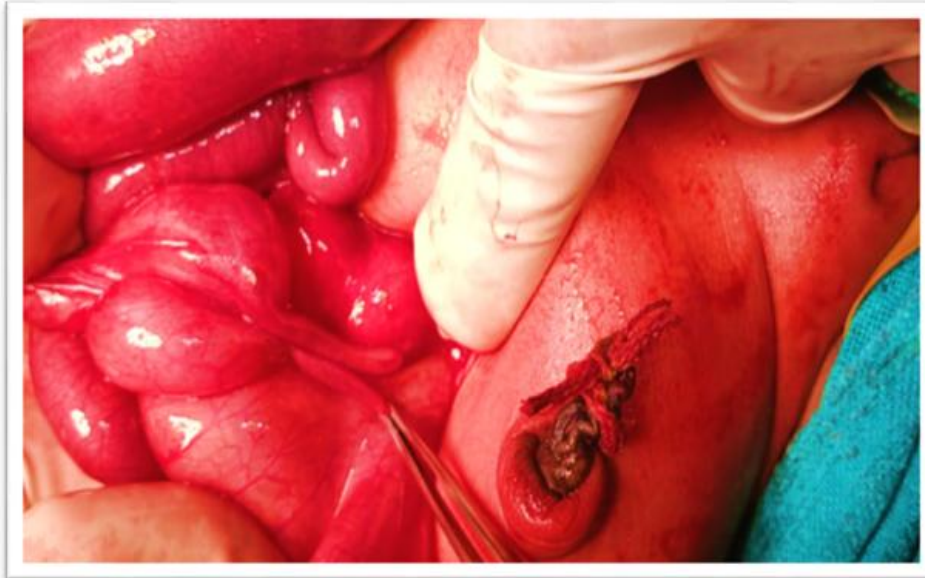
### II. Methods:

We report four cases of duplication of appendix associate with type I CPC out of 25 cases of pouch colon encountered in last 4 years duration. The medical record has been extracted and reviewed from all managed cases of ARM.

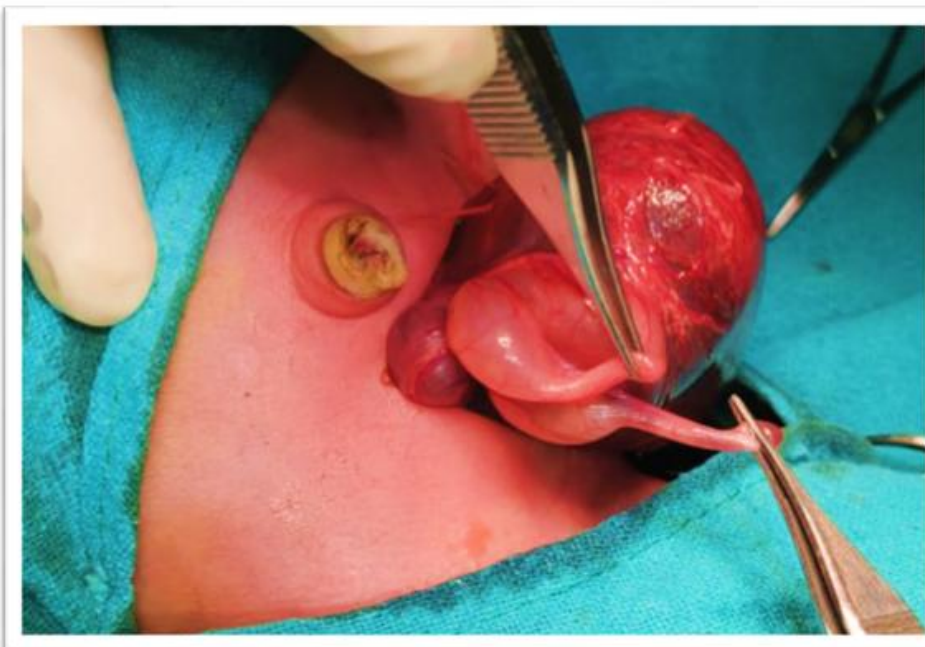
### III. Results:

Anorectal malformations accounted (for 178 cases) for 37.7% of total admissions. In 33 cases, female infants were diagnosed with either anovestibular or rectovaginal fistula or cloacal anomaly. The nature and level of obstruction in anorectal malformations (ARM) diagnosed after cross table prone lateral view radiograph and antero-posterior view. About 10% of cloacae (female) were found to have CPC. Out of 178 cases of ARM, record of 4 cases of CPC in cloaca having appendiceal duplication observed. In all cases appendectomy was done along with bladder fistula ligation and pouchorrhaphy. All cases awaiting definitive repair for anorectal malformation at present.

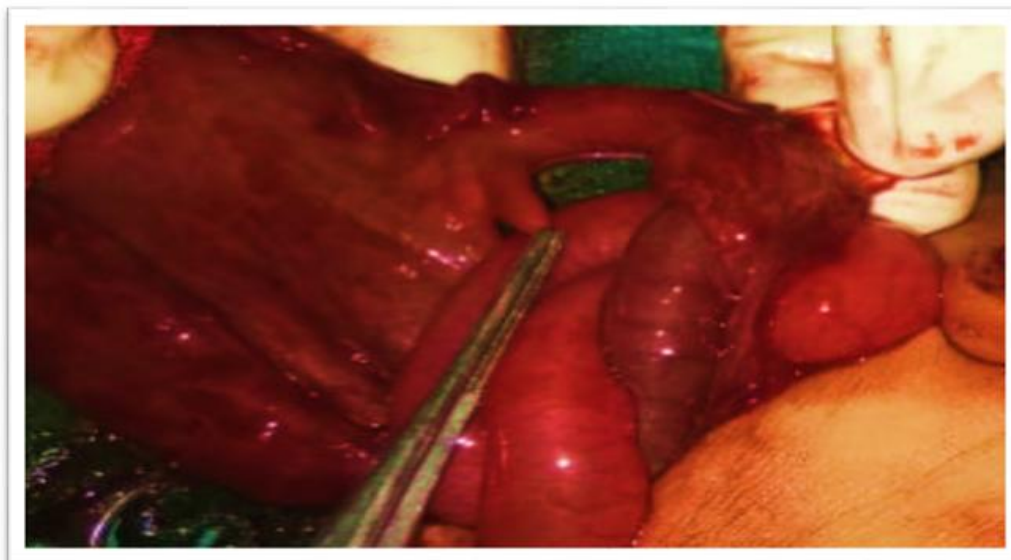
Case 1: Postnatal day 3 persistent cloaca (female ARM) having abdominal distention, X-ray suggestive of pouch like dilatation of colon. On exploration, type II pouch found opening into urinary bladder and double appendix (Type A) with bifurcated caecum seen. The residual 2 cm colon along-with cecum & double appendixes removed and end ileostomy made on one side & pouchorrahpy stoma on other side made after bladder fistula ligation (figure 1).



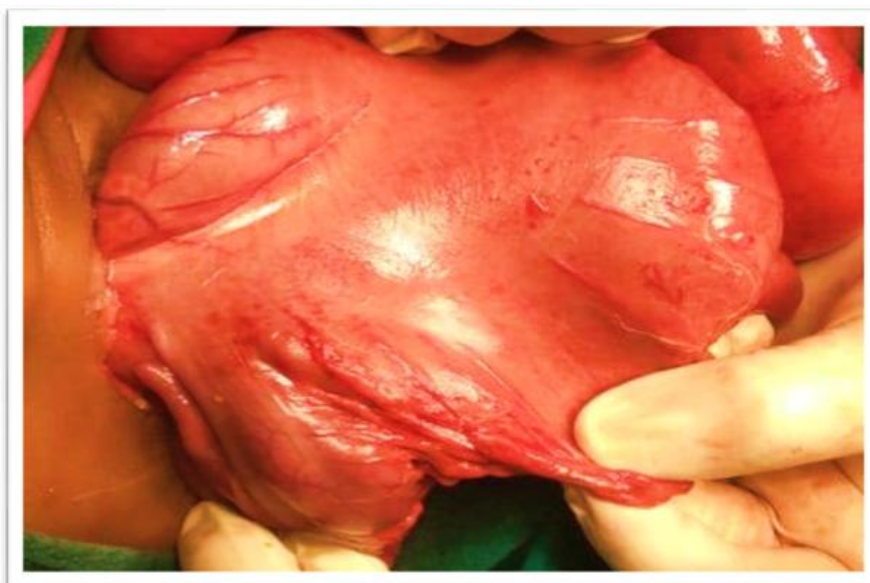Case 2: Postnatal day 2 persistent cloaca (female ARM) diagnosed on X-ray s/o pouch like dilatation of colon. On exploration, type II pouch colon with 3 cm length of colon found opening into pouch that having large fistulous communication with urinary bladder and double appendix with double caecum seen (Type C). The residual colon along-with double caecum & appendixes remove and end ileostomy on one side & pouchorrahpy stoma on other side made along-with bladder fistula ligation (figure 2).



Case 3: Postnatal day 3 persistent cloaca (female ARM) having abdominal distention, X-ray s/o pouch like dilatation of colon. On exploration, perforated & partial necrosed type I pouch found having large fistula opening into urinary bladder and double appendix (type B2), also bifid uterus & fallopian tube having hydrosalpinx seen. Necrosed pouch along with double appendix removed, bladder fistula ligated, hydrosalpinx drained and end ileostomy made (figure 3).



Case 4: Two months persistent short channel cloaca (female ARM) diagnosed on X-ray having pouch like dilatation of colon. On exploration, type II pouch colon with 3 cm length of colon found opening into pouch that had a large fistulous communication with urinary bladder and double appendix (Type 2A). The distal colon along-with cecum & double appendix removed, bladder fistula ligated and end ileostomy on one side & pouchorraphy stoma on other side made (figure 4).



#### **IV. Discussion:**

The leading indication of neonatal surgery admissions are congenital anomalies, surgical infections and acquired surgical conditions during the hospital stay. Congenital pouch colon is a very rare abnormality in which varying degrees of pouch-like dilatation of the dysplastic colon are associated with an anorectal malformation. The pouch usually communicates with a fistulous track with the genitourinary tract. CPC is classified on anatomic morphology into five types as per the length of the colon involved. In “Saxena and Mathur Classification based on anatomic morphology the type 5 CPC shows a double pouch colon with a short normal interposition colon segment [1]. The higher incidence of type I & II and the association with cloaca may reflect the poor nutritional status of the mother however, a well-designed study need to be carried out to investigate the association in this part of India. About 90% of the cases are reported from India (especially northern India) but recently there is increasing awareness about this rare anomaly and some cases are now reported from other parts of the world [1,2].

The most accepted theory of embryogenesis is defective positioning of the embryogenic cloaca by descending urorectal septum [3]. Congenital abnormalities of the appendix are rare, there are two more common

anomalies of the appendix; congenital absence and appendicular duplication reported in adults [4]. Duplication of the appendix is an extremely rare condition, with a reported incidence of 0.004% of appendectomy specimens and found as an incidental finding during surgery [5].

The aim of surgery in CPC is to preserve the colonic tissue [6], in order to restore or partially reconstitute the function of the large bowel such as absorption, transportation, and containment. Even though there is an algorithm for the management of CPC based on the type of pouch it is still controversial. In type 1 CPC and type 2 CPC, a one-stage procedure (pouch excision and pull-through) or three-stage procedure (ileostomy, pouchocoloplasty or pouchorhaphy with pull-through, and ileostomy closure), depending on the condition of the pouch (ischemic or healthy), can be performed. In this series, 3 out of 4 cases, in order to preserve colonic tissue for future definitive reconstruction of colovaginal structures, colonic tissue preserved by making pouchorhaphy tube as a mucus fistula and after excising double caeco-appendix, end-ileostomy made for functional decompression. In one case having pouch necrosis, we could not preserve pouch and excised the necrosed pouch along with caecoappendix.

#### V. Conclusion:

CPC is a very rare condition of anorectal malformations common in Northern India could be associated with appendiceal abnormalities, specially with type1 and type2 that need to be considered after diagnosis. Congenital abnormalities of the appendix are rare and duplication of the appendix is an extremely rare condition, with a reported incidence of 0.004% of appendectomy specimens and found as an incidental finding during surgery.

#### References:

- [1]. P. Mathur, A.K. Saxena, M. Bajaj, T. Chandra, N.C. Sharma, A. Simlot, et al., Role of plain abdominal radiographs in predicting type of congenital pouch colon, *Pediatr. Radiol.* 40 (2010) 1603–1608.
- [2]. D.K. Gupta, S. Sharma, Congenital pouch colon-Then and now, *J. Indian Assoc. Pediatr. Surg.* 12 (5) (2007).
- [3]. Angotti Rossella, , Qadir Qadir Mohamed Salih, Molinaro Francesco, Ferrara Francesco, Sica Marina. et al Congenital Pouch Colon Associated with Anorectal Malformation: a Rare Anomaly of Asian Region-Experience of Kurdish Centre. *Afr J Paediatr Surg* 2018 Jan-Mar;15(1):10–5.
- [4]. Collins DC. A study of 50,000 specimens of the human vermiform appendix. *Surg Gynecol Obstet.* 1955;101:437- 445.
- [5]. Griffiths Ewen A, Jagadeesan Jayaraman, Fasih Tarannum, Mercer-Jones Mark, j.cursur. Bifid vermiform appendix: a case report. 2006. 02.001.
- [6]. Qadir, Qadir Mohammed Salih, Ahmad Mohammed Ayad. Congenital pouch colon in Duhok, outcome and complications: case series. *Ann Med Surg* 2019;45: 86–90. .

Dr Vinay Mathur, et. al. “Duplication of Appendix in four cases of Congenital pouch colon: Case series.” *IOSR Journal of Dental and Medical Sciences (IOSR-JDMS)*, 22(3), 2023, pp.62-65.