

## Incidence of Radix Endomolaris in a Subpopulation of Central Kerala

SABATINA JAMES 1, DEEPAK BABY 2, SREEDEVI P V 3, RAJEEV KG 4, SANGEETHA K V 5, APARNA P 6

<sup>1</sup> Post Graduate student, Dept. of Conservative Dentistry & Endodontics, PSM Dental College, Akkikavu, Thrissur, Kerala.

<sup>2</sup> Professor and Head of the Department, Dept. of Conservative Dentistry & Endodontics, PSM Dental College, Akkikavu, Thrissur, Kerala.

<sup>3</sup> Professor, Dept. of Conservative Dentistry & Endodontics, PSM Dental College, Akkikavu, Thrissur, Kerala.

<sup>4</sup> Professor, Dept. of Conservative Dentistry & Endodontics, PSM Dental College, Akkikavu, Thrissur, Kerala.

<sup>5</sup> Post Graduate student, Dept. of Conservative Dentistry & Endodontics, PSM Dental College, Akkikavu, Thrissur, Kerala.

<sup>6</sup> Post Graduate student, Dept. of Conservative Dentistry & Endodontics, PSM Dental College, Akkikavu, Thrissur,

---

### Abstract:

**Background:** The aim of this study was to determine the prevalence of radix endomolaris and their correlations between female and male patients and the right-side and left-side in mandibular first molar by using periapical radiographs in a subpopulation of central Kerala.

**Materials and Methods:** 560 mandibular molars were evaluated for the presence of a radix endomolaris using intraoral periapical digital radiography. These patients had reported to the Department of Conservative Dentistry and Endodontics, PSM Dental College, to seek treatment from 2021 to 2022. Screening identified 464 subjects (205 male and 259 female) with bilateral permanent mandibular first molars. The total incidence of 3-rooted mandibular first molars and the ratio of the occurrence in gender of such teeth were assessed, and the comparison of right- to left-side occurrence of these 3-rooted mandibular first permanent molars were also estimated, and were analysed by using the Pearson chi-square test.

**Results:** Of the 464 treated mandibular first molars, 31 were found to have a third root with an overall incidence being 6.68%. The incidence was 56% for female patients and 44% for male patients. There was no significant difference in the incidence of three-rooted mandibular first molars between females and males and right and left side. Incidence was 54% for the right side and 45% for the left side, results are not statistically significant.

**Conclusion:** This study confirms a 6.68% prevalence of radix endomolaris in a South Indian population, thus necessitating the absolute need of a thorough radiological assessment before initiation of endodontic therapy.

**Key Word:** radix endomolaris,

---

Date of Submission: 01-03-2023

Date of Acceptance: 12-03-2023

---

### I. Introduction

The prime objective of endodontic treatment is thorough cleaning and shaping of the root canal system followed by 3-dimensional obturation. One of the frequent causes of failure of nonsurgical endodontic treatment is the inability to identify and negotiate additional roots/canals. The mandibular first molar, as the earliest permanent posterior tooth to erupt, is considered to be the most frequently involved tooth in endodontic procedures. It displays considerable anatomic variation and abnormalities regarding the number of roots and root canals.<sup>1</sup>

The morphological knowledge of root canals is indispensable and improves the operator's ability to locate and trace a root canal to its termination, thereby increasing the degree of successful treatment.<sup>2</sup> The permanent mandibular first molar is usually two-rooted, a mesial and a distal. One of the major anatomical variations is the presence of an additional third root, also called the radix endomolaris (RE) which is located distolingually in mandibular molars. This macrostructure, which was first mentioned in the literature by Carabelli. In very rare cases, when this additional root is located mesiobuccally, it is called radix paramolaris.<sup>3</sup>

Studies have shown that this supernumerary root can be separate from or partially fused to other roots. It is typically smaller than the mesial and distobuccal roots and is usually curved, requiring special attention when endodontic intervention is considered. The coronal part of RE is completely or partially fixed to the distal root and its dimension can vary from short conical to a root of normal length and root canal.

Carlsen and Alexandersendescribed 4 different types of RE, whereas DeMoor et al. <sup>4</sup>suggested a classification with 3 different types of RE: type I refers to a straight root, type II refers to an initially curved entrance that continues as a straight root, and type III refers to an initial curve in the coronal third of the root canal and a second curve beginning in the middle and continuing to the apical third. Anatomical studies have reported an association between the presence of a separate RE in the first mandibular molar and certain ethnic groups.<sup>1</sup> It is seldom found in European, Caucasian, and African populations but appears to be more common in races of Mongoloid origin. In these populations, RE is regarded as a normal racial and morphologic variation rather than as an abnormality and can be seen as an Asiatic trait.<sup>1</sup>

## **Objectives**

The aim of this study was to determine the prevalence of radix endomolaris and their correlations between female and male patients and the right-side and left-side in mandibular first molar by using periapical radiographs in a subpopulation of central kerala.

## **II. Material And Methods**

560 mandibular molars was evaluated for the presence of a third root (RE) using intraoral periapical digital radiography. These patients had reported to the Department of Conservative Dentistry and Endodontics, PSM Dental College, to seek treatment from 2021 to 2022. They were informed about the study design and provided written consent. Each patient was older than 18 years and of South Indian origin. Personal details, including age, sex, and ethnicity were recorded. The criteria for subject selection were the following: (1) subject had to be of South Indian origin; (2) each subject had fully erupted permanent mandibular first molars bilaterally; (3) the permanent mandibular first molars had fully formed apices, no root canal fillings, posts, or crown restorations.

Screening identified 464 subjects (205 male and 259 female) with bilateral permanent mandibular first molars for inclusion in this investigation.

Two periapical radiographs were taken from 2 different horizontal angles: one was taken in the orthoradial position and the other was taken 30° mesially. The stored digital radiographs were displayed on a 19-inch LCD monitor (LG Electronics, South Korea) and investigated for the presence of a third root by 2 authors. Disagreement in the interpretation of images was discussed between two authors until a consensus was reached.

The criteria used to indicate the presence of radix endomolaris were clear distinction of an extra root, indicated by the crossing of translucent lines defining the pulp space and periodontal ligaments, originating in the upper half of the distal root.

The total incidence of 3-rooted mandibular first molars and the ratio of the occurrence in gender of such teeth were assessed, and the comparison of right- to left-side occurrence of these 3-rooted mandibular first permanent molars were also estimated.

Comparison of the incidence and the correlations between males and females and left- and right-side occurrences were analysed by using the Pearson chi-square test .

## **III. Results**

Of the 464 treated mandibular first molars, 31 were found to have a third root with an overall incidence being 6.68%. The incidence was 56 % for female patients and 44% for male patients . There was no significant difference in the incidence of three-rooted mandibular first molars between females and males . Incidence was 54% for the right side and 45 % for the left side, results is not statistically significant.

Graph 1 - Distribution of study population based on presence of radixendomolaris

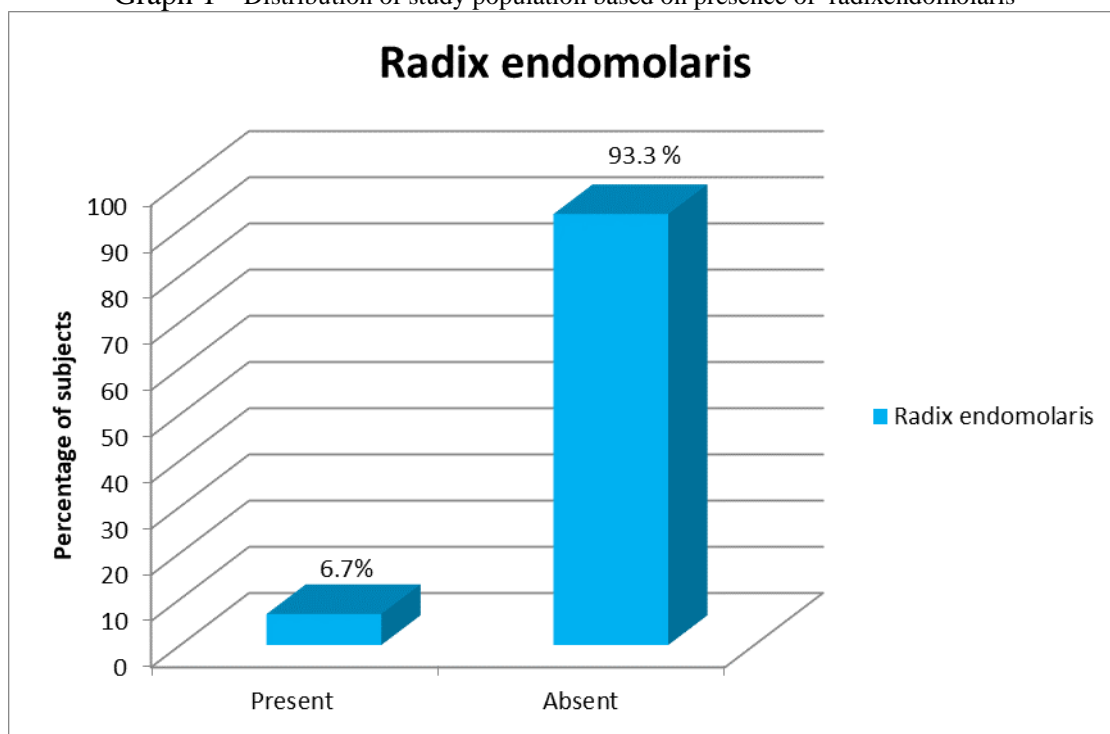
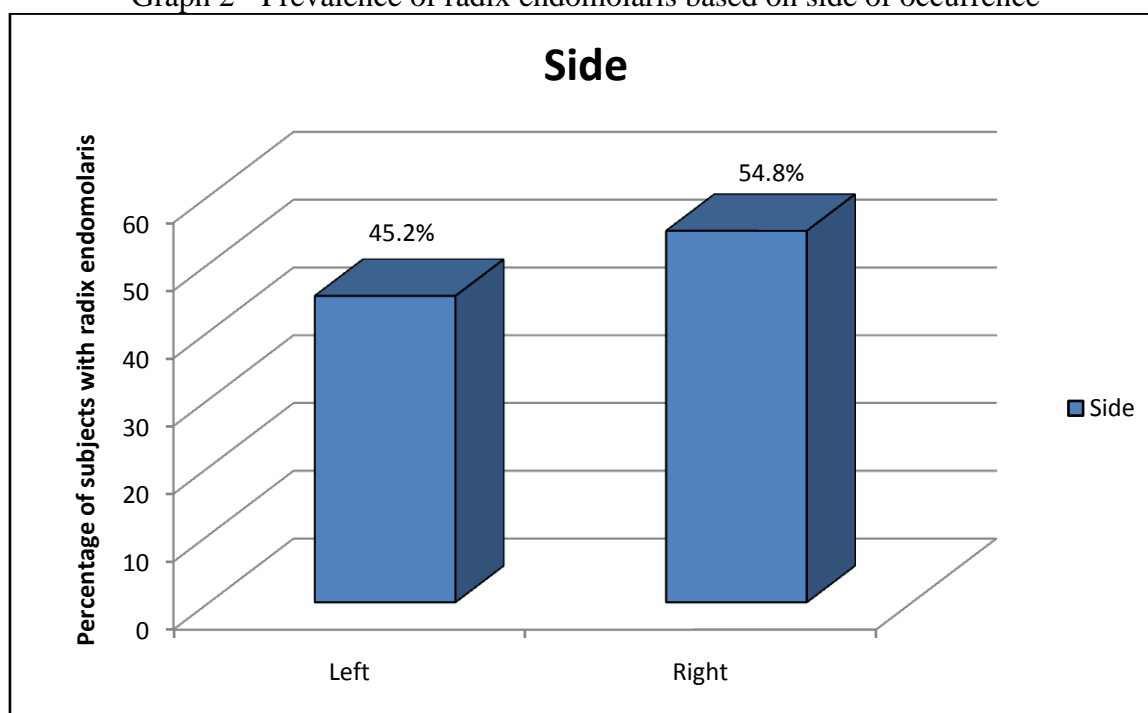


Table 1 - Distribution of population based on gender

Gender	Frequency	Percent
Male	205	44.2
Female	259	55.8
<b>Total</b>	<b>464</b>	<b>100.0</b>

Graph 2 - Prevalence of radix endomolaris based on side of occurrence



#### **IV. Discussion**

Finding anatomical and morphological differences through an examination of root canal systems significantly increases the success and prognosis of canal treatment. A failure to detect anatomical and morphological variations in roots and canals, that is, C-canals, additional canals, or additional roots can have negative consequences ranging from teeth with poor prognosis to persistent periapical lesions which do not respond to treatment, and may even cause tooth loss.

A clinician's knowledge of the normal anatomy and possible variations of teeth is extremely important for the prognosis of endodontic treatment. Radiographs taken at different angulations reveal the basic information regarding the anatomy of a tooth and can thus help to detect any aberrant anatomy such as extra canals/roots.<sup>6</sup>

The presence of a supernumerary root in mandibular teeth was first found by Carabelli in 1844. This root was named radix endomolaris (RE) by Bolk in 1915. REs are generally shorter and more curved than other roots and can be separate from or fused to roots. In 1990, Carlsen and Alexandersen classified the morphology of REs, and in 1997 Ribeiro and Consolaro assessed their buccolingual orientation and based on the external root morphology and scouting of root canals, Radix Endomolaris could be classified in three groups.

Type I refers to a straight root/root canal. Type II refers to an initially curved entrance and the continuation as a straight root/root canal. Type III refers to an initial curve in the coronal third of the root canal and a second buccally orientated curve starting from the middle to apical third.<sup>5</sup>

The presence of an radix endomolaris in the first mandibular molar is associated with certain ethnic groups. In African populations, a maximum of 3% is found, whereas in Eurasian and Indian populations the frequency is less than 5%.<sup>10</sup> In populations with Mongoloid traits (Malay, Chinese, Eskimo, and American Indian), the frequency of occurrence is 5% to 40%. This macrostructure has been particularly an Asiatic trait and its prevalence has been reported to be 1.2% to 21.5%.

In the present study, the incidence of three-rooted mandibular first molars among the subpopulation of central Kerala was 6.68%. This figure is higher than the result of the study by Tratman (0.20%) among Asiatic Indians and similar to the result of the study by Turner (5.8%) among American Indians and less than the study by Somogyi-Csizmazia and Simons among Canadian Indians (15.6%). In this study, there was no significant difference according to gender ( $P > .05$ ), which is similar to the recent studies. There was also no significant difference according to the side occurrence (right versus left side,  $P > .05$ ), which was also similar to the recent study.

However, some studies reported that three-rooted mandibular first molars occurred more frequently on the right side than on the left side, whereas there are also studies showing that these three-rooted mandibular first molars occurred more frequently on the left side.<sup>7</sup>

The incidence of RE according to either gender did not appear to show any statistical significance in the present study. There was no significant difference according to the side of occurrence. Some authors have reported that this anatomic variation occurred more frequently on the right side, whereas others reported that it is seen more on the left side. Some studies reported a bilateral occurrence of the 3-rooted mandibular molars of from 50% to 69%. Schäfer et al.<sup>29</sup> failed to find any bilateral occurrence in their study of 1024 mandibular first molars in a German population.<sup>7</sup>

There have been several studies of extracted permanent mandibular first molars, but it is impossible to compare the results of these studies related to gender and bilateral occurrences. The present non-invasive study used 2-dimensional images (periapical radiographs) of patients' mandibular first molar as a tool for studies related to gender and side-related differences.

The presence of radix endomolaris has clinical implications in endodontic treatment. An accurate diagnosis of these supernumerary roots can avoid complications or missing a canal can cause failure of the root canal treatment. Apart from complicating the root canal procedure, RE has been found to be a contributing factor to localized periodontal destruction. In addition, reports correlate significantly higher probing depths with attachment loss at the distolingual aspect of three-rooted molars.<sup>7</sup>

#### **V. Conclusion**

Wide variability in the prevalence of radix endomolaris in different population groups has been known to exist. This study confirms a 6.68% prevalence of radix endomolaris in a South Indian population, thus necessitating the absolute need of a thorough radiological assessment before initiation of endodontic therapy.

#### **References**

- [1]. Chandra SS, Chandra S, Shankar P, Indira R. Prevalence of radix endomolaris in mandibular permanent first molars: a study in a South Indian population. *Oral Surgery, Oral Medicine, Oral Pathology, Oral Radiology, and Endodontology*. 2011 Sep 1;112(3):e77-82.
- [2]. Rashid AM, Suliman HA. Incidence of third root in mandibular permanent first molar: An endodontic challenge. *Al-Rafidain Dental Journal*. 2006 Jun 1;6(2):194-8.

- [3]. Dube M, Trivedi P, Pandya M, Kumari M. Incidence of radix entomolaris in the Indian population—an in vitro and in vivo analysis. *J Int Oral Health*. 2011 Oct 1;3:35-45.
- [4]. De Moor RJ, Deroose CA, Calberson FL. The radix entomolaris in mandibular first molars: an endodontic challenge. *Int Endod J*2004;37:789-99
- [5]. Duman SB, Duman S, Bayrakdar IS, Yasa Y, Gumussoy I. Evaluation of radix entomolaris in mandibular first and second molars using cone-beam computed tomography and review of the literature. *Oral radiology*. 2020 Oct;36:320-6.
- [6]. Singh P, Mahanubhav NH, Biswas A, Pandita V, Karmani V, Kumari N. Occurrence of Radix Entomolaris in mandibular first molar.
- [7]. Garg AK, Tewari RK, Kumar A, Hashmi SH, Agrawal N, Mishra SK. Prevalence of three-rooted mandibular permanent first molars among the Indian population. *Journal of endodontics*. 2010 Aug 1;36(8):1302-6.

SABATINA JAMES, et. al. "Incidence of Radix Endomolaris in a Subpopulation of Central Kerala." *IOSR Journal of Dental and Medical Sciences (IOSR-JDMS)*, 22(3), 2023, pp. 28-32.