

# Patterns of Meniscal Tears in the Patients with Anterior Cruciate Ligament Injury

Dr.Ram subhash .A  
Final year Post Graduate  
Department of Radiodiagnosis  
GREAT EASTERN MEDICAL SCHOOL & HOSPITAL  
Andhra Pradesh, India

Dr.B.R.NAGARAJ MD (RD),DMRD  
PROFESSOR & HOD  
Department of Radiodiagnosis  
GEMS AND HOSPITAL,  
Andhra Pradesh, India

---

## ABSTRACT-

The knee is the largest joint in our body, making it most susceptible to injury—affecting millions of people each year. Two of the most common knee injuries are to the meniscus, or cartilage, or to the anterior cruciate ligament, or ACL. The meniscus functions as a shock absorber and helps distribute weight between the upper and lower legs. Meanwhile, the ACL is a band of tissue that runs through the middle of your knee and provides structural support for the knee during twisting and intense activities. The symptoms of an ACL tear will include a feeling that the knee has given away or shifted while the foot is planted and the knee is twisted.

In the present study, 118 patients with clinical suspicion of internal derangement of knee who underwent for MRI were retrospectively evaluated. Study images were analyzed to document various imaging features of injury patterns to knee. The results were analyzed and pictorial presentation compiled.

**Key words-**MRI, ACL, MENISCUS.

---

Date of Submission: 01-03-2023

Date of Acceptance: 12-03-2023

---

## I. INTRODUCTION

•ACL TEARS : Nearly three quarters of all ACL injuries are non-contact injuries, rest of them are contact injuries. The precise mechanism of ACL tears includes axial compressive forces on the lateral aspect of the joint, inadequate dampening of ground reaction forces, whole-body kinematics and valgus forces.

•ACL injuries can range from low-grade sprains with out tearing of the ligament (Grade I sprain), to partial-thickness tears in which some of the fibers of the ACL have torn (Grade II sprain), to full thickness tears of the ACL (Grade III sprain)

•Most ACL tears tend to occur in the mid to proximal aspect of the ligament and will appear with increased T2-weighted signal and an abnormal contour.

•In partial tears, the anteromedial bundle is most commonly involved.

## II. AIMS AND OBJECTIVES

To evaluate the association and patterns of meniscal tears with anterior cruciate ligament injury.

## III. MATERIALS AND METHODS

This is a single center retrospective observational study conducted in the department of radiodiagnosis in a tertiary care institute of an urban area.

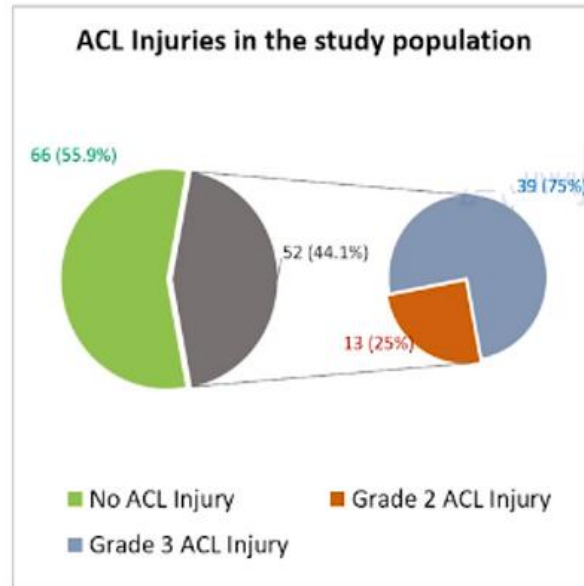
•A total of 118 patients with out age predilection with clinical suspicion of internal derangement of knee who underwent MRI between January to June were evaluated.

•Demographic details like age, gender, clinical symptoms and mechanism of injury were selected.

#### IV. RESULTS

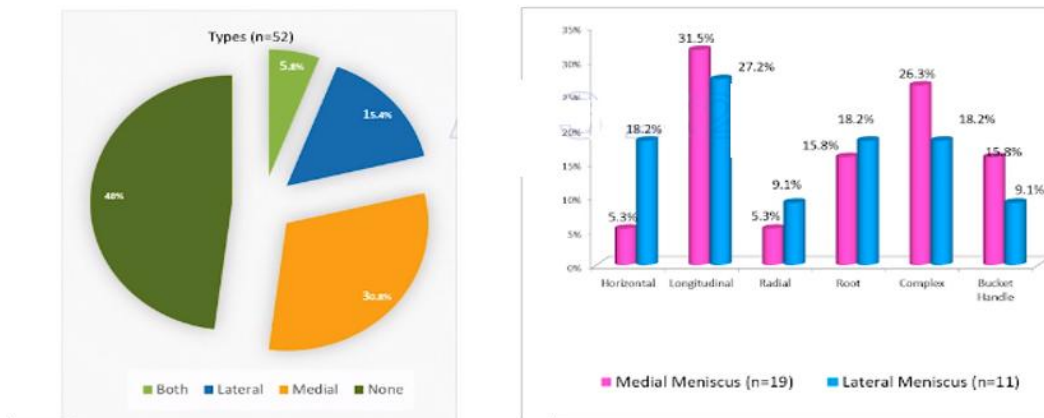
A total number of 118 cases were included in the study and the data was expressed in number and percentages.

**CHART1:**



**CHART2:**

#### Types and Patterns of Meniscal Tears in the study population

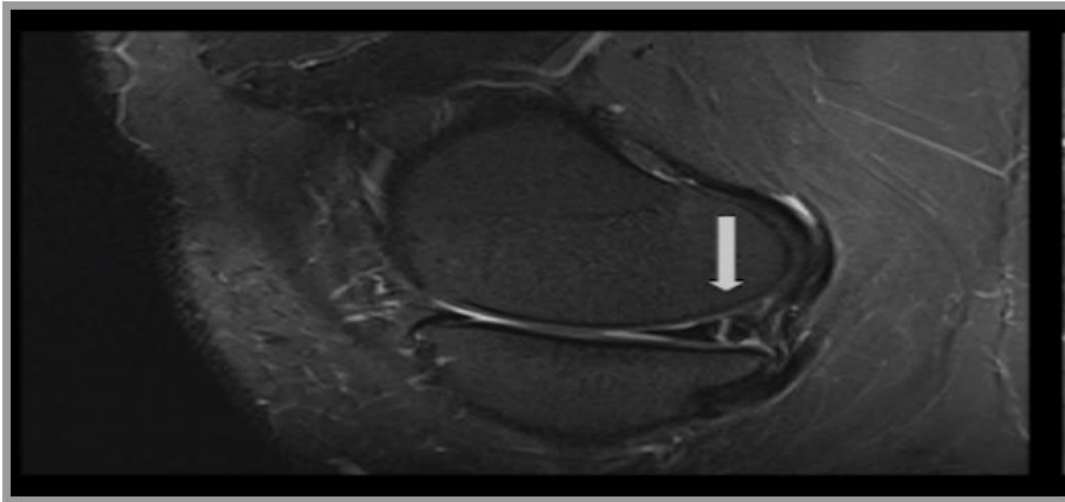


**CHART3:**

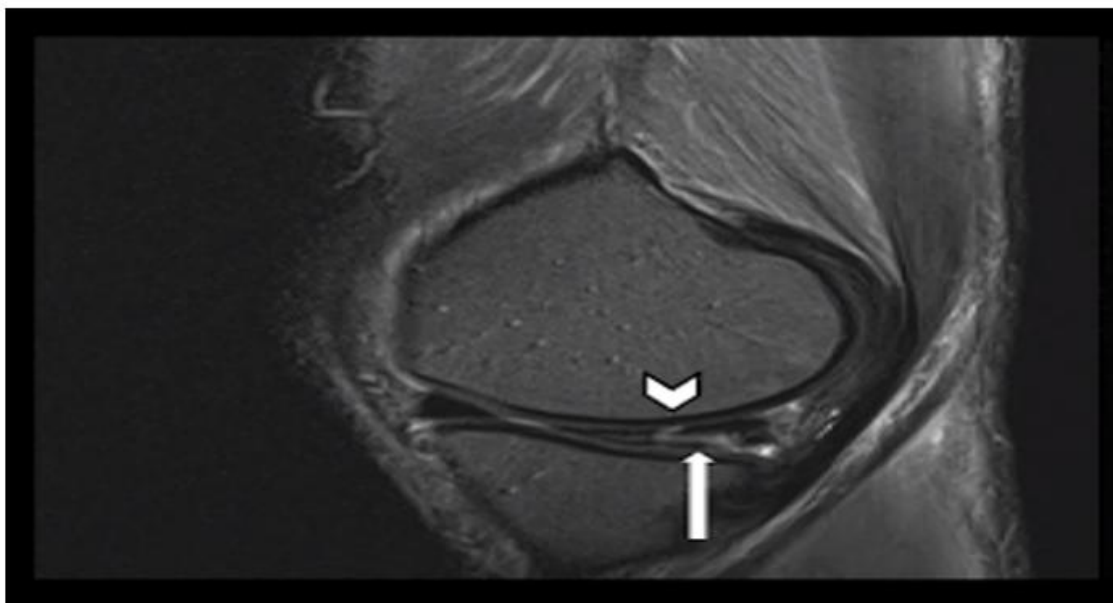
**Patterns of Meniscal Tears in participants with ACL injury**

Meniscal Tears	Medial Meniscal Tears N (%)	Lateral Meniscal Tears N (%)
Horizontal	1 (5.3)	2 (18.2)
Longitudinal/ Vertical	6 (31.5)	3 (27.2)
Radial	1 (5.3)	1 (9.1)
Root	3 (15.8)	2 (18.2)
Complex	5 (26.3)	2 (18.2)
Bucket Handle	3 (15.8)	1 (9.1)
<b>Total</b>	<b>19 (100)</b>	<b>11 (100)</b>

**Case1** :25 yr.malewithverticaltearintheposteriorhornofmedialmeniscus

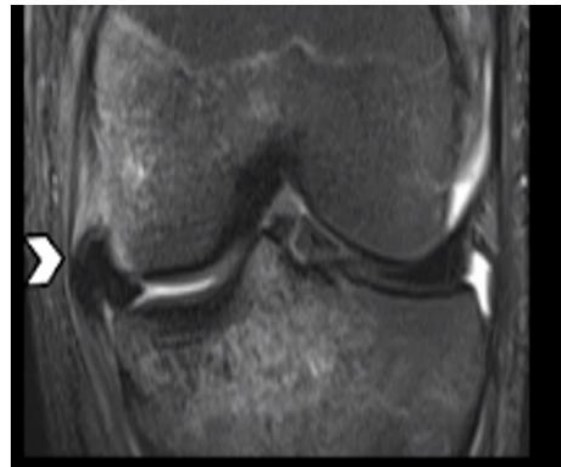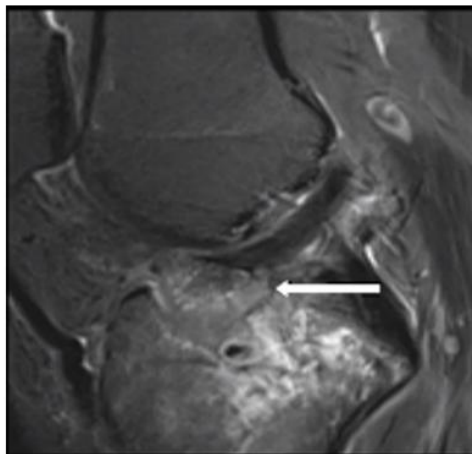


**Case2** :44 yr.malewithpartialACLtearshowingcomplextearofmedialmeniscus(horizontalandverticalcomponents)



**Case3**

:23yr.malewithinjurytoleftkneeshowingextrudedmedialmeniscus,withtearinanteriorrootofmedialmeniscusandavulsioninjuryofACL



**V. DISCUSSION-**

In this retrospective observational study of 118 patients ,88(75%) were males and 30(25%) were females, out of which 52 patients were having ACL tears.

Complete tears were identified in 39 (75 %) and partial tears were identified in 13(25%) patients. Study shows higher prevalence of ACL tears in male population than females. This is mainly because men are more actively involved in outdoor activities.

ACL injury prevalence was high in age group between 20 to 45 yrs(69%).

Incidence of meniscal injury was found to be 52% in patients with ACL injury.

Medial meniscal tears were more common than lateral meniscal tears ,likely due to the reason that medial meniscus less mobile and thus bearing more force during weight bearing.

Lateral meniscal tears are more in younger patients likely sports related and concomitant ACL tears.

Among all subtypes the most common subtype of medial meniscus tear is Longitudinal/vertical tears.

There is association between root tears and ACL avulsion injury due to close proximity to each other.

Significant proportion of root tears of both medial and lateral menisci showed extrusion.

**VI. Conclusion :**

Significant proportion of meniscal tears were associated with injury to ACL. Diagnosis and precise classification of meniscal tears in patients with ACL injury can facilitate better patient management.

**REFERENCES-**

- [1]. Fox MG. MR imaging of the meniscus: review, current trends, and clinical implications. *MagnReson Imaging Clin N Am.* 2007 Feb;15(1):103-23. doi: 10.1016/j.mric.2007.02.004. PMID: 17499184.
- [2]. Nguyen JC, De Smet AA, Graf BK, Rosas HG. MR imaging-based diagnosis and classification of meniscal tears. *Radiographics.* 2014 Jul-Aug;34(4):981-99. doi: 10.1148/rg.344125202. PMID: 25019436
- [3]. Ciuffreda P, Lelario M, Milillo P, Vinci R, Coppolino F, Stoppino LP, Genovese EA, Macarini L. Mechanism of traumatic knee injuries and MRI findings. *Musculoskelet Surg.* 2013 Aug;97 Suppl 2:S127-35. doi: 10.1007/s12306-013-0279-7. Epub 2013 Aug 15. PMID: 23949934.
- [4]. Granan LP, Bahr R, Lie SA, Engebretsen L. Timing of anterior cruciate ligament reconstructive surgery and risk of cartilage lesions and meniscal tears: a cohort study based on the Norwegian National Knee Ligament Registry. *Am J Sports Med.* 2009 May;37(5):955-61. doi: 10.1177/0363546508330136. Epub 2009 Feb 26. PMID: 19251674

Dr.B.R.NAGARAJ MD (RD),DMRD, et. al. "Patterns of Meniscal Tears in the Patients with Anterior Cruciate Ligament Injury." *IOSR Journal of Dental and Medical Sciences (IOSR-JDMS)*, 22(3), 2023, pp. 11-14.