

## Incidental Thyroid Nodules on Ultrasound: Frequency and Ultrasound Characteristics.

Dr. Karuna Hazarika, Dr. Halimuddin Ahmed, Dr. Chiranjeeta Dutta

1. DR. KARUNA HAZARIKA, PROFESSOR & HOD, DEPARTMENT OF RADIODIAGNOSIS, TEZPUR MEDICAL COLLEGE AND HOSPITAL, TEZPUR, ASSAM, INDIA.
2. DR. HALIMUDDIN AHMED, ASSISTANT PROFESSOR, DEPARTMENT OF RADIODIAGNOSIS, TEZPUR MEDICAL COLLEGE AND HOSPITAL, TEZPUR, ASSAM, INDIA.
3. DR. CHIRANJEETA DUTTA, PGT, DEPARTMENT OF RADIODIAGNOSIS, TEZPUR MEDICAL COLLEGE AND HOSPITAL, TEZPUR, ASSAM, INDIA.

Corresponding author: Dr. Chiranjeeta Dutta, Department of Radiodiagnosis, Tezpur Medical College and Hospital, Bihaguri-784010, Assam, India.

### ABSTRACT

**Background:** Incidental thyroid nodule is defined as a nodule that has been found by an imaging examination that was not previously clinically noticed or suspected. Concern over a thyroid nodule that was accidentally detected and management recommendations play a significant role. The purpose of this study was to assess the frequency of incidental thyroid nodules (ITN) found incidentally on ultrasound of the neck for indications other than the thyroid gland, to describe the sonographic characteristics of the nodules, and discuss the management of incidental thyroid nodules.

**Materials and methods:** The thyroid gland was evaluated in 350 patients by Ultrasound in patients who presented to the radiology department for US of neck for any non-thyroid cause and without any known thyroid disease. If the thyroid ultrasound revealed an abnormal scan, the patient was sent to the clinician for further clinical evaluation, and as per standard recommendations, a fine-needle aspiration (FNA) biopsy was performed where indicated after clinical and laboratory examination. The lesions were also analyzed based on their ultrasound characteristics.

**Results:** 68 patients (19.4 %) among the 350 were found to have a total of 84 incidental thyroid nodules. Incidence was more common in females than males. Among the 68 patients with incidental thyroid nodules, 62 patients (91.1%) were diagnosed as benign and 6 patients (8.8%) were diagnosed as malignant, all malignant lesions in the age group above 50 years. 5 out of 6 malignant lesions showed suspicious features on ultrasound.

**Conclusion:** In USG of the neck, incidental thyroid nodules are not an uncommon finding. Ultrasonography characteristics of the nodule can be used to decide on the optimal management measures. In order to minimize needless work-up, standard recommendations like ACR-TIRADS based on ultrasound risk stratification can be followed.

**Key Words:** Incidental, thyroid nodule, ultrasound, US, malignant, benign, imaging.

Date of Submission: 05-03-2023

Date of Acceptance: 17-03-2023

### I. INTRODUCTION

Incidental thyroid nodules, also referred to as "incidentaloma" are used to describe thyroid lesions that are small, asymptomatic & clinically nonpalpable, and are incidentally discovered on imaging. The reported incidence varies based on the imaging modality and demographic factors.<sup>1,2</sup> The importance lies in the concern of possible malignancy of an incidentally discovered thyroid nodule and guidelines regarding management. The workup of ITNs has resulted in higher expenses from additional procedures as well as, in some circumstances, higher patient risks due to the doctors' as well as patients' understandable worries about the possibility of malignancy and a delayed cancer diagnosis. Most people discover thyroid nodules accidentally while having a physical exam and having a neck image taken for another reason because thyroid malignancies typically do not have local symptoms.<sup>3</sup> Due to emerging use of high-resolution ultrasonography (US), detection of asymptomatic small thyroid nodules has become more common.<sup>4,5</sup> US imaging also allows a quantitative risk stratification of malignancy in thyroid nodules with standard reporting system or 'TIRADS' (thyroid imaging reporting and data system) by American college of radiology. The ACR TI-RADS classifies ultrasonography findings as benign, not suspicious, minimally suspicious, moderately suspicious, or highly suspicious for cancer as TR-1 to TR-5 respectively. Each ultrasonography characteristic of a nodule receives points, with additional points given for further suspicious characteristics.<sup>6</sup> The American Thyroid Association's guidelines published in 2015 on the

management of thyroid nodules, advocated thyroid ultrasounds for all patients in whom another imaging scan revealed the existence of a thyroid nodule. Separately, the recommendations suggested that, in general, only nodules larger than 1 cm require further evaluation.<sup>7</sup> This study's objectives were to determine the frequency of incidental thyroid lesions and analyse the US features of the nodules seen during neck ultrasounds for causes other than thyroid problems.

COMPOSITION		ECHOGENECITY		SHAPE	
Cystic or almost completely cystic	0 points	Anechoic	0 points	Wider-than-tall	0 points
Spongiform	0 points	Hyperechoic or isoechoic	1 point	Taller-than-wide	3 points
Mixed cystic and solid	1 point	Hypoechoic	2 points		
Solid or almost completely solid	2 points	Very hypoechoic	3 points		

MARGIN		ECHOGENIC FOCI	
Smooth	0 points	None or large comet tail artefacts	0 points
Ill-defined	0 points	Macrocalcifications	1 point
Lobulated or irregular	2 points	Peripheral (rim) calcifications	2 points
Extra-thyroidal extension	3 points	Punctate echogenic foci	3 points

*Fig. 1. Ultrasonographic characteristics of the nodule and respective points as per ACR Thyroid Imaging, Reporting and Data System (TI-RADS)*

## II. MATERIALS AND METHODS

**Study Design:** Prospective study

**Study Location:** Tertiary care hospital -- Tezpur Medical College and hospital, Tezpur, Assam.

**Study Duration:** December 2020 to December 2021.

**Study population:** Our study took the patients who presented to the radiology department for neck USG for any non-thyroid cause. A total of 350 patients were considered who came for USG from December 2020 to December 2021 for cervical lymphadenopathy, any non-thyroid swelling of the neck and face, and cases of carotid doppler. Cases found to have incidental thyroid nodules were evaluated with dedicated thyroid USG and lesions were characterized based on their sonographic features. Patients with known thyroid disease have been excluded from the study. Both male and female patients were included in the study and patients were within the age group of 15 to 75 years. The patient was then referred to the clinical department and after clinical and laboratory evaluation, ultrasound-guided fine-needle aspiration (FNA) cytology/biopsy was done if indicated as per recommended guidelines of ACR TI-RADS. Follow-up thyroid US was done to assess changes in size and appearance of nodules in those where FNA was not performed and nodules were considered benign if no changes occurred after two consecutive exams done at 6 monthly intervals.

### Imaging technique

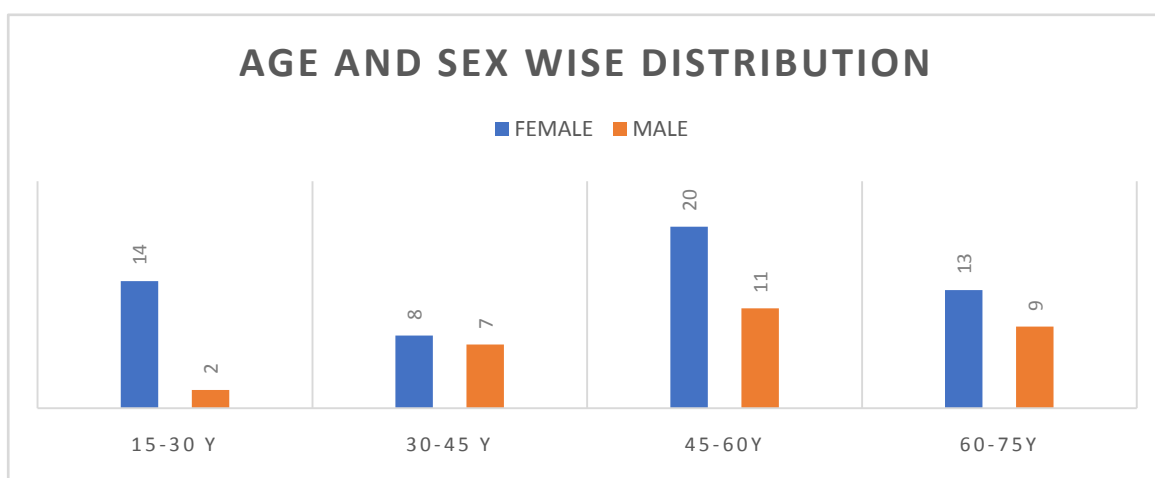
All the USGs were done using a Samsung RS80A ultrasound system using a linear transducer of 10 MHz. Thyroid scans were done in longitudinal and transverse planes covering both lobes and the isthmus. The lesions were assessed according to their composition, echogenicity (relative to strap muscles), orientation, presence or absence of calcification, and border description of all lesions, and the findings were recorded. TI-RADS score was given to lesions as per the American college of radiology. Following recommendations, fine-needle aspiration (FNA) cytology/biopsies were carried out under US guidance. The lesions were classified as benign or malignant according to histologic findings and/or follow-up.

### Data Analysis

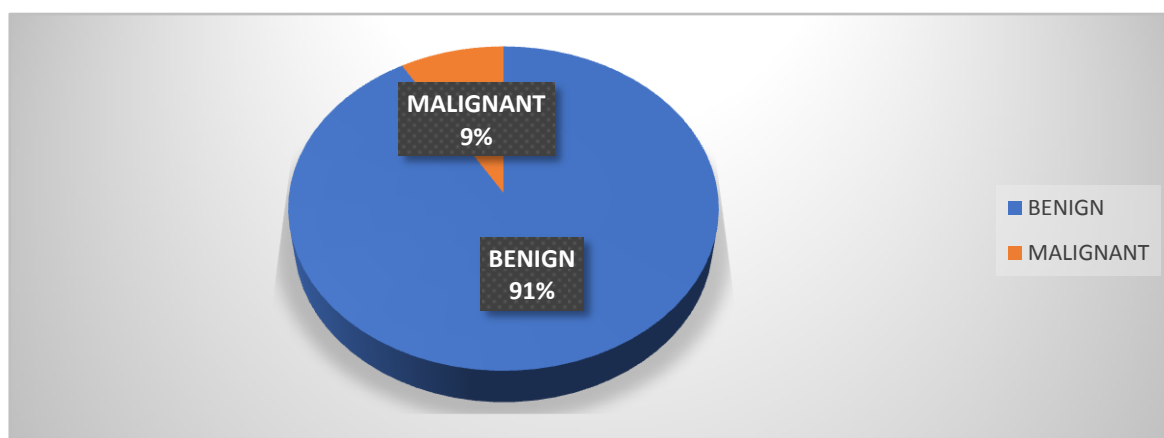
The statistical analyses of the results were done using the commercially available statistical software -- Statistical Package for the Social Sciences software (version 25.0; Chicago, Ill). Statistical analyses were performed by Univariate analysis. Statistical significance was set at p value <0.05.

### III. RESULTS

Among the 350 patients examined, we found a total of 84 nodules in 68 (19.4 %) patients. In patients with more than one nodule, the dominant nodule was characterised. We found 8 patients with diffusely heterogenous thyroid gland with no discernible nodules.



*Table 1. Age and sex wise distribution of patients with incidental thyroid nodules.*



*Table 2. Frequency of malignancy in incidental thyroid nodules*

Among the 68 patients with incidental thyroid nodules, 62 patients (91.1%) were diagnosed as benign and 6 patients (8.8%) were diagnosed as malignant. Of the 84 nodules, 43 (51.1 %) had nodules >10 mm while 16 (19.0 %) had nodules 15 mm. On the assessment of composition, 16 (19.0 %) nodules were cystic, 42 (50.0%) were solid or predominantly solid and 26 (30.9 %) were mixed solid-cystic. Analysis of echogenicity showed that 19 (22.6%) nodules were hypoechoic, 49 (58.3%) nodules were isoechoic/hyperechoic and 16 (19.0%) nodules were anechoic/cystic (Table 3). Analysis of shape showed 10 nodules with taller-than wide-orientation while others were wider-than-tall. 72 nodules had a smooth margin, 9 with ill-defined margins while 3 showed lobulated margin. And 28 of the lesions showed calcification of which 5 of them were punctate calcification, 7 lesions were peripheral calcification and 16 were macrocalcifications.

Appearance	Number
Composition	
Cystic	16
Solid	42
Mixed	26
Echogenicity	
Hypoechoic	19

---

Hyper/isoechoic	49
Anechoic	16
Shape	
Wider-than-tall	74
Taller-than-wide	10
Margin	
Smooth	72
Ill-defined	9
Lobulated/irregular	3
Calcification	
None/Comet-tail artefacts	40
Macrocalcification	16
Peripheral	7
Punctate foci	5

---

*Table 3. Sonographic characteristics of the incidentally detected thyroid nodules*

The minimum size of detected thyroid nodules was 3.2 mm and the maximum size was 31 mm. The mean (SD) diameter of nodules was 13.1+/- 7.5 mm. On analysis of thyroid function tests, only 6 of the patients had blood thyroid stimulating hormone (TSH) level abnormalities. In our study, fine needle aspiration was suggested to the 35 patients, as per the ACR guidelines, of whom 7 patients refused to undergo FNA.<sup>8</sup>In four cases, the smear was declared hemorrhagic. 6 patients were confirmed at pathology as malignant tumors. The remaining 18 lesions were classified as negative, and all were benign. The rest 33 patients underwent follow-ups at 6 monthly intervals and were declared benign after two follow-ups due to no significant increase in size or presence of any other suspicious malignant features on USG. Among the 6 cases declared as malignant on pathology, 4 of them showed punctate calcification while all 6 were hypoechoic. 5 out of the 6 malignant cases were in the higher age groups (>50 years).

#### IV. DISCUSSION

Depending on the investigation modality, the frequency of detection of incidental thyroid nodules can differ. In our study we found a prevalence of 19.4 %. The prevalence can vary depending on the demographic factors. Rad et al found a prevalence of 19.6 % of thyroid incidentalomas in their study in carotid doppler patients.<sup>9</sup> Kang et al, in their retrospective study of 1475 patients found a prevalence of 13.4 %.<sup>10</sup> Some studies have however reported a much higher prevalence, 73.9 % by Shetty et al in their study of incidental thyroid nodules on CT.<sup>11</sup> We found an increased tendency with increasing age, with peak frequencies identified in those aged 45 to 60 years. They were also notably more common in females than males.

A total of 16 (23.5%) patients had nodule(s) with at least one suspicious grayscale ultrasonographic feature (studies have stated suspicions of features such as solid hypoechoic, punctate calcific foci in the nodule, lobulated or irregular border).<sup>12-15</sup> We had 28 patients undergo US-guided FNA of which 4 smears were declared hemorrhagic or inadequate (14.2%). Danese et al reported inadequate samples in 8.5% of US-guided FNA in comparison to 14.1% in FNA biopsies without US guidance.<sup>16</sup> FNA cytology has revealed 18 (64.2 %) as benign and 6 (21.4%) were declared malignant. The malignant lesions showed significant relation with punctate calcific foci and hypoechoic echotexture (p-value<0.01). We have classified the lesions based on US features and follow-up US and got an overall rate of malignancy of 8.8%. Other studies too have reported a low incidence of malignancy in incidental thyroid nodules. Shetty et al have reported a malignancy rate of 4.9 % while Papini et al., have reported a malignancy of 5.7%.<sup>10,12</sup> However, Kang et al have reported a higher malignancy rate of 28.7 %.<sup>10</sup> The differences in our reported prevalence of incidental nodules and rate of malignancy could be attributed to the low study population and non-cooperation of patients.

#### V. CONCLUSION

Encountering an incidental thyroid nodule is common to radiologists these days and it presents a dilemma to the radiologist too along with the clinician about the management of an incidental finding. As reported malignancy among incidental thyroid nodules has been low, follow-up ultrasound can be considered a convenient option. Ultrasound is a non-invasive and affordable procedure and risk stratification with ultrasound allows for a significantly accurate assessment of the lesions. One of the risk stratification guidelines includes the

ACR-TIRADS where US characteristics are given points as described above in figure 1, and the point total determines the nodule's ACR TI-RADS level. Recommended guidelines can be followed to decide on the management, however, the patient's risk factors, comorbidities, life expectancy, and other pertinent factors should all be taken into account when deciding whether to perform FNA. As the reported malignancy of incidental thyroid nodules is low, it is important to emphasize the use of a conservative approach.

#### **CONFLICTS OF INTEREST**

There are no conflicts of interest.

#### **STATEMENT OF INFORMED CONSENT**

Informed consent was obtained from all individual participants included in the study.

#### **REFERENCES**

- [1]. Gharib H, Papini E, Paschke R. Thyroid nodules: A review of current guidelines, practices, and prospects. Vol. 159, *European Journal of Endocrinology*. 2008.
- [2]. Gharib H, Papini E, Paschke R, Duick DS, Valcavi R, Hegedüs L, et al. American Association of Clinical Endocrinologists, Associazione Medici Endocrinologi, and European Thyroid Association medical guidelines for clinical practice for the diagnosis and management of thyroid nodules: Executive summary of recommendations. Vol. 16, *Endocrine Practice*. 2010.
- [3]. Gough J, Scott-Coombes D, Fausto Palazzo F. Thyroid incidentaloma: An evidence-based assessment of management strategy. In: *World Journal of Surgery*. 2008.
- [4]. Naik KS, Bury RF. Review Imaging the Thyroid. *Clin Radiol*. 1998;53.
- [5]. Khurana KK, Richards VI, Chopra PS, Izquierdo R, Rubens D, Mesonero C. The role of ultrasonography-guided fine-needle aspiration biopsy in the management of nonpalpable and palpable thyroid nodules. *Thyroid*. 1998;8(6).
- [6]. Tessler FN, Middleton WD, Grant EG, Hoang JK, Berland LL, Teefey SA, et al. ACR Thyroid Imaging, Reporting and Data System (TI-RADS): White Paper of the ACR TI-RADS Committee. *Journal of the American College of Radiology*. 2017;14(5).
- [7]. Haugen BR, Alexander EK, Bible KC, Doherty GM, Mandel SJ, Nikiforov YE, et al. 2015 American Thyroid Association Management Guidelines for Adult Patients with Thyroid Nodules and Differentiated Thyroid Cancer: The American Thyroid Association Guidelines Task Force on Thyroid Nodules and Differentiated Thyroid Cancer. *Thyroid*. 2016;26(1).
- [8]. Hoang JK, Langer JE, Middleton WD, Wu CC, Hammers LW, Cronan JJ, et al. Managing incidental thyroid nodules detected on imaging: White paper of the ACR incidental thyroid findings committee. *Journal of the American College of Radiology*. 2015;12(2).
- [9]. Rad MP, Zakavi SR, Layegh P, Khooei A, Bahadori A. Incidental thyroid abnormalities on carotid color doppler ultrasound: Frequency and clinical significance. *J Med Ultrasound*. 2015;23(1).
- [10]. Kang HW, No JH, Chung JH, Min YK, Lee MS, Lee MK, et al. Prevalence, Clinical and Ultrasonographic Characteristics of Thyroid Incidentalomas. *Thyroid*. 2004;14(1).
- [11]. Shetty SK, Maher MM, Hahn PF, Halpern EF, Aquino SL. Significance of incidental thyroid lesions detected on CT: Correlation among CT, sonography, and pathology. Vol. 187, *American Journal of Roentgenology*. 2006.
- [12]. Papini E, Guglielmi R, Bianchini A, Crescenzi A, Taccogna S, Nardi F, et al. Risk of malignancy in nonpalpable thyroid nodules: Predictive value of ultrasound and color-doppler features. *Journal of Clinical Endocrinology and Metabolism*. 2002;87(5).
- [13]. Carroll BA. Asymptomatic thyroid nodules: Incidental sonographic detection. *American Journal of Roentgenology*. 1982;138(3).
- [14]. Steele SR, Martin MJ, Mullenix PS, Azarow KS, Andersen CA. The significance of incidental thyroid abnormalities identified during carotid duplex ultrasonography. Vol. 140, *Archives of Surgery*. 2005.
- [15]. Knudsen N, Laurberg P, Perrild H, Bülow I, Ovesen L, Jørgensen T. Risk factors for goiter and thyroid nodules. *Thyroid*. 2002;12(10).
- [16]. Danese D, Sciacchitano S, Farsetti A, Andreoli M, Pontecorvi A. Diagnostic accuracy of conventional versus sonography-guided fine-needle aspiration biopsy of thyroid nodules. *Thyroid*. 1998;8(1).

Dr. Chiranjeeta Dutta, et. al. "Incidental Thyroid Nodules on Ultrasound: Frequency and Ultrasound Characteristics." *IOSR Journal of Dental and Medical Sciences (IOSR-JDMS)*, 22(3), 2023, pp. 34-38.