

## Functional and Radiological Outcome of Mini Jess Fixator in Hand Trauma - A Prospective Study.

Dr. Sunil Choudhary<sup>1\*</sup>, Dr. Rajendra Didel<sup>2</sup>, Dr. Vijay Gehlot<sup>3</sup>, Dr. Laxman Choudhary<sup>4</sup>, Dr. Abhinav Singh<sup>5</sup>.

<sup>1</sup>Senior resident, Department of Orthopaedics, GMC, Pali, Rajasthan, India.

<sup>2</sup>Assistant professor, Department of Orthopaedics, GMC, Pali, Rajasthan, India.

<sup>3</sup>Senior resident, Department of Orthopaedics, GMC, Pali, Rajasthan, India.

<sup>4</sup>Assistant professor, Department of Orthopaedics, GMC, Pali, Rajasthan, India.

<sup>5</sup>Senior Resident, Department of Orthopaedics, SPMC, Bikaner, Rajasthan, India.

### ABSTRACT:

**BACKGROUND:** Fractures of Metacarpals and phalanges are quite common in developing countries. These are associated with RTA, machine injuries, and other modes. Mobility of the hand is very important for daily activities; therefore, preoperative planning must be emphasized. Treatment of these fractures is highly associated with stiffness.

**MATERIAL AND METHODS:** This prospective interventional study was conducted for a period of 6 months in our hospital. A total of 40 patients were included in the study. Among them, 25 patients (62.5%) were phalangeal fractures and 15 (37.5%) patients were Metacarpal fractures. All these patients were operated on with a mini-external fixator. Follow-up was done at 2 weeks, 6 weeks, 4 months, and 6 months and functional outcome was assessed using the DUNCAN score.

**RESULTS:** In our study out of 40 patients, 31 (77.5%) were males and 9 (22.5%) were females. The mean age of the patients was 33 (18-60) years. The mean duration of fracture union was 6 (4-8) weeks. DUNCAN Score at final follow-up was 21 (52.5%) patients had excellent outcomes, 13 (32.5%) patients had good outcomes, 4 (10%) patients had fair, and 2 (5%) patients had poor outcomes.

**CONCLUSION:** There are various modalities for the treatment of Metacarpal and phalangeal fractures, mini-external fixator provides better functional outcomes compared to k-wires, and conservative methods in terms of stability and preserving ROM, thus preventing post-operative stiffness.

**Keywords:** JESS, DUNCAN, RTA, K-WIRE, METACARPAL, HAND TRAUMA.

Date of Submission: 02-04-2023

Date of Acceptance: 13-04-2023

### I. Introduction

The human hand has evolved into an organ of exceptional prehensile function capable of highly complex movements and manipulation. Hands have got a very distinct and important role.<sup>1</sup> It is an organ both for powerful grasp as in lifting heavy objects as well as delicate pinch and hook functions. Hand injury is extremely common and accounts for about 15% of the attendance at accidents and emergency departments.<sup>2</sup> Fractures of metacarpals and phalanges are probably the most common fractures in the skeletal system. Some of the common causes of hand injuries are crush/compression injuries, blunt trauma, fall, road traffic accidents, machinery injury, sports-related activity, and explosions/firearm injuries. Various modes of treatment have been used for hand fractures which include K wire fixation, mini plates, and external fixator application.<sup>3</sup>

External fixation is a method of stabilization of bone fractures in which a number of percutaneous metal pins pass through the fractured bone segments with their ends connected to a rigid frame.<sup>4</sup> Joshi's External stabilization system is a widely used external fixation device for various fractures. JESS has been used for the treatment of post-burn contractures of the hand and wrist<sup>4</sup>, interphalangeal joint contractures in leprosy<sup>5</sup>, intraarticular distal radial fractures<sup>6</sup>, idiopathic clubfoot<sup>7</sup>, hand trauma and its sequels<sup>8</sup>, calcaneal fractures<sup>9</sup> and congenital talipes equinovarus<sup>9,10</sup>.

JESS works on the principle of distraction histoneogenesis<sup>11</sup> which can be widely used in case of compound fractures involving bone loss which will help in the generation of new bone. Owing to its simple design, lightweight, easy manoeuvrability, and low cost<sup>12-15</sup>, JESS provides stable fixation while avoiding damage to the already injured tissue thereby reducing the chance of infection. Moreover, it permits movement of adjacent joints and permits secondary procedures<sup>16,17</sup> without disturbing the fracture thereby reducing the incidence of joint stiffness and resulting in the achievement of early functional outcomes.

## II. Aim And Objectives

To study the functional and radiological outcome of fractures of the hands managed by Joshi's External Stabilization System.

## III. Material And Methods

After obtaining clearance from the ethical committee, A hospital-based prospective study was conducted at a tertiary-level hospital for a total duration of 6 months from January 2021 to January 2023, in patients with fractures of the hand managed by Joshi's external fixator. A total of 40 patients with Hand fractures (metacarpals and phalangeal) who attended the casualty or O.P.D. during this period were included in the study.

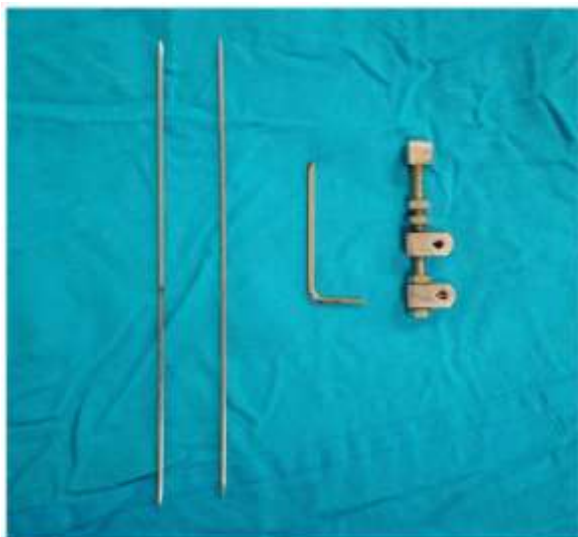
Inclusion criteria:

- Patients with the age group of 18-60 years.
- Closed comminuted metacarpal and phalangeal # of hand.
- Open metacarpal and phalangeal # of hand.
- Intra-articular fractures of the hand.

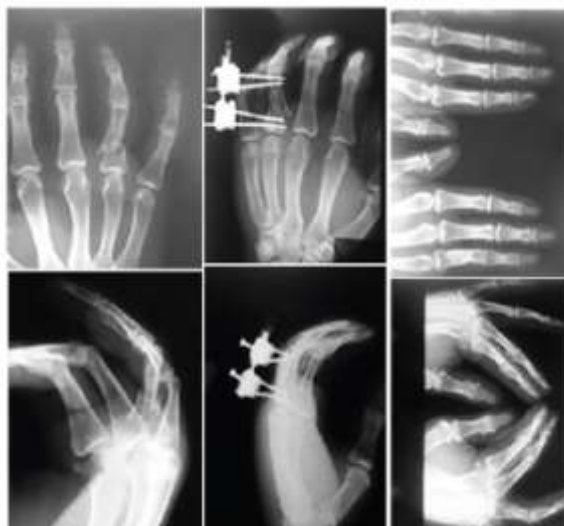Exclusion criteria:

- Pathological fractures.
- Crush hand with multiple compound Grade 3 fractures.
- Isolated fracture of the distal phalanx.
- Local infection.
- Simple two-part fracture.

After taking consent from the patient to participate in the study, after illustrating the study to them and letting them know how the study was performed and its purposes preoperative preparations were undertaken, which included history and examination, routine investigations, pre-operative x-rays, and pre-anaesthetic clearance. Under the supraclavicular block, the patient was placed in a supine position with the forearm on the side table. Closed reduction was achieved by traction and manipulation. To maintain reduction, an external fixator was applied by passing two or one K wires proximally and two or one K wires distal to the fracture and need of fracture pattern. These two constructs were connected using connecting rods. Acute and gradual Distraction was given if required. An image intensifier was used as a guide for the steps mentioned above




**Fig.1: Components of MINI JESS**



**Fig.2: Pre-op, intra-op and post-op X-ray at 6 weeks.**

Postoperatively the patients were taught active mobilization of the unaffected fingers, elbow, and shoulder from the immediate post-op period. Antibiotics were given for open fractures. Pin tract dressings were done regularly. Suture removal in 2 weeks. The external fixator was removed at 4 weeks. Patients were reviewed at 2 weeks, 6 weeks, 4 months, and 6 months on an OPD basis to assess the radiological and functional outcome: radiological assessment of fracture union is assessed with AP and lateral radiograph and function outcome is assessed using the DUNCAN scoring system.

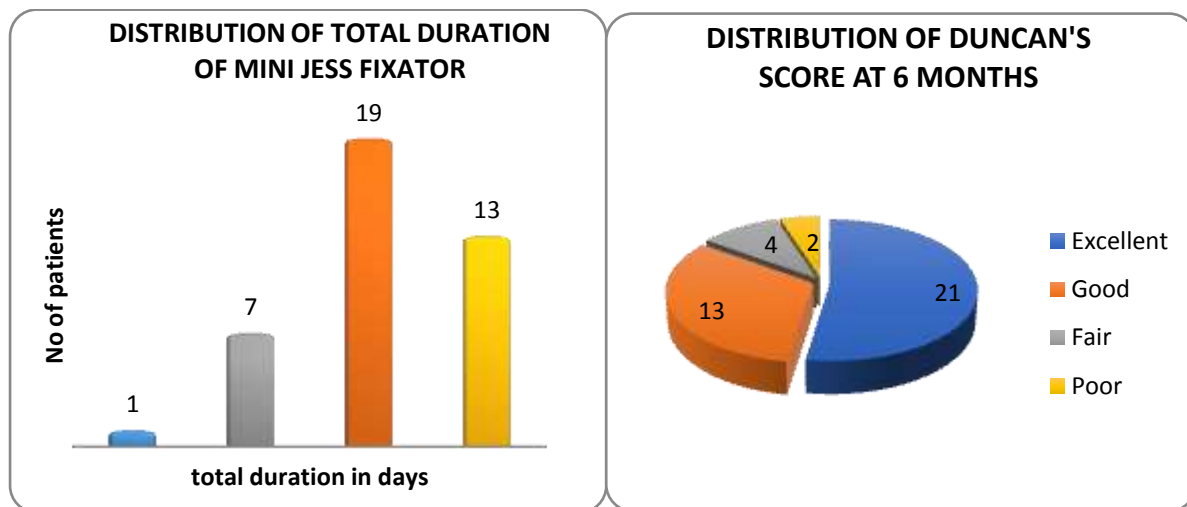


**Fig.3: Clinical photograph at 2 weeks post-op and 6 weeks post-op**

To collect the required information from eligible patients, a free structured pre-tested proforma was used. For data analysis, Microsoft Excel was used and data were analyzed with the help of frequencies, proportions, measures of central tendency, appropriate statistical tests.

#### IV. RESULTS

The following results were obtained from the study conducted on 40 patients with ages of the patients ranging from 18-60 years. The mean age of patients was 33.00 years. Among 40 patients, 31(77.5%) were male and 9(22.5%) were female. 25(62.5%) cases had fracture phalanx and 15(37.5%) cases had fractured metacarpal. The type of fracture involved 20(50%) patients with close fractures and 20(50%) patients with open fractures. Among 40 patients in the study, 30(75%) patients were involved in road traffic accidents followed by 10(25%) who were involved with machinery injuries. No patients were lost to follow-up.



The duration of fracture union ranged from 4 weeks to 8 weeks with the mean duration of fracture union being 6 weeks. The DUNCAN score at the final follow-up was 21(52.50%) patients having excellent surgical outcomes, followed by 13(32.50%) patients with good surgical outcomes, 4 (10%) patients with fair surgical outcomes, and 2(5%) patients with poor surgical outcome.

The complications encountered during the follow-up included k wire loosening in 3 patients, skin infections in 2 patients, and tendon impingement in 1 patient.

#### V. DISCUSSION

Most of the fractures of miniature bones are treated conservatively<sup>18,19</sup>, Open reduction and internal fixation are performed for unstable fractures for absolute stability, thereby promoting early union and movement of joints. But open reduction and internal fixation cannot be achieved in all cases due to the nature of the injury. Also, open reduction and internal fixation require additional soft tissue stripping which sometimes hinders union or leads to adhesion preventing active movement of digits. In our study, a mini-Jess fixator is applied to all types

of fractures, both closed and compound fractures of the hand except those associated with vascular injury. Mini Jess Fixator avoids additional injury to the soft tissue. It also promotes wound healing in case of compound fractures. The operative technique is simple with the use of an image intensifier.

In our study injury was seen more in males than in females; 31 males and 9 females which is comparable to the other studies. Naidu *et al*<sup>20</sup> had 26 males and 9 females, Parson *et al*<sup>21</sup> had 26 males and 4 females, and Schuind *et al*<sup>22</sup> had 21 males and 5 females in their respective studies. The increase in the incidence of injury in males is due to their type of occupation. Naidu *et al*<sup>20</sup> in their study showed the most common cause of injury is due to road traffic accidents in 11 patients (48.94%) which is equivalence to the current study. Parson *et al*<sup>21</sup> showed most injuries occurred due to road traffic accidents in 11(55%) patients in the study which is similar to the current study, where most injuries occurred due to road traffic accidents (75%). The average age group in our study was 33 years whereas the Parson *et al*<sup>21</sup> studies had an average age group of 28 years. The involvement of hand injury is more in the younger age group population as they are the ones involved mostly in road traffic accidents. The average radiological union was achieved at 6 weeks which is equivalence to the average union achieved by Parson *et al*<sup>21</sup> in their study which accounted for a duration of 4.8 weeks.

In our study of hand fractures functional outcome is analyzed using the DUNCAN score. It measures the total range of motion in the injured finger. The functional result obtained among metacarpal fractures is better compared to phalangeal fractures which in turn is better than combined fractures. The results obtained in our study are similar to the study conducted on 38 patients that include 17 phalangeal and 21 metacarpal fractures Mishra AK *et al* (2019). Excellent to good results are obtained in 85% of patients with metacarpal and phalangeal fractures in our study which is better than 80% and 93.33% with phalangeal and metacarpal fractures respectively, obtained in the above-mentioned study.

## VI. CONCLUSION

Mini external fixator helps in the preservation of movements and gives the best functional results by providing stable fixation. A simple surgical technique will minimize complications and an aggressive rehabilitation regime will ensure the best possible result. In general, the mini external fixator is an alternative treatment for the management of fractures of miniature long bones, especially in certain situations with the best functional outcome.

### CONFLICT OF INTEREST:

No conflict of interest.

## BIBLIOGRAPHY

- [1]. Scott W, William P, Scott HK, Mark C. Green's operative hand surgery. 4th ed. Philadelphia, US: Churchill Livingstone. 1999; p.711-57.
- [2]. De JJJ, Kingma J, van DLB, Klases HJ. Phalangeal fractures of the hand: an analysis of gender and age-related incidence and aetiology. The journal of Hand Surgery. 1994; 19(2):168-170.
- [3]. Reyes FA, Latta LL. Conservative management of difficult phalangeal fractures. ClinOrthopRelat Res. 1987; (214):23-30.
- [4]. Singh J, Jain KM, Ravishankar R. Outcome of closed proximal phalangeal fractures of the hand. Indian J Orthop. 2011; 45:432-8.
- [5]. Belsky MR, Eaton RG, Lane LB. Closed reduction and internal fixation of proximal phalangeal fractures. J Hand Surg [Am]. 1984; 9:725-9.
- [6]. Schuind F, Cooney WP III, Burny F, An K-N. Small external fixation devices for the hand and wrist. Clin Orth. 1993; 293:77-82.
- [7]. Watson-Jones R, Barton NJ. Fractures and Joint Injuries of the hand. In: Wilson JN, editor. Watson-Jones fractures and joint Injuries. 7th ed. Noida: Elsevier Publishers. 2009, 650-95.
- [8]. Schuind F, Donkerwolcke N, Burny F. External minifixation for treatment of closed fractures of the metacarpal bones. J Orthop Trauma. 1991; 5:146-529.
- [9]. Riggs SA Jr, Cooney WP III. External fixation of complex hand and wrist fractures. J Trauma. 1983; 23:332-6.
- [10]. Joshi BB. Percutaneous internal fixation of fractures of the proximal phalanges. Hand. 1976 feb;8(1):86-92.
- [11]. Thomas RK, Gaheer RS, Ferdinand RD. A simple external fixator for complex finger fractures. ActaOrthop Belg. 2008feb; 74(1):109-113.
- [12]. Jafari D, Ajvadi A. A Novel Handmade External Fixator for Phalangeal and Metacarpal Fractures. J Res Orthop Sci. 2017; 4(1):e8352.
- [13]. Crockett DJ. Rigid fixation of bones of the hand using K wires bonded with acrylic resin. Hand. 1974; 6:106-107.
- [14]. McCulley SJ, Hasting C. External fixator for the hand: a quick, cheap and effective method. J Royal Coll Surgeons Edinb. 1999; 44:99-102.
- [15]. Duncan RW, Freeland AE, Jabaley ME, Meydrech EF. Open hand fractures: an analysis of the recovery of active motion and of complications. J Hand Surg [Am]. 1993; 18:387-94.
- [16]. Drenth DJ, Klases HJ. External fixation for phalangeal and metacarpal fractures. J Bone Joint Surg. 1998; 80B:227-230.
- [17]. Parsons SW, Fitzgerald JA, Shearer JR. External fixation of unstable metacarpal and phalangeal fractures. J Hand Surg [Br]. 1992; 17:151-5.
- [18]. Barton N. Conservative treatment of articular fractures in the hand. J Hand Surg Am 1989; 14: 386-90. doi: 10.1016/0363-5023(89)90119-6.
- [19]. Wright TA. Early mobilization in fractures of the metacarpals and phalanges. Can J Surg 1968; 11: 491-8.

*Functional and Radiological Outcome of Mini Jess Fixator In Hand Trauma - A Prospective Study.*

---

- [20]. Naidu KVD. Management of metacarpal and phalangeal fractures with JESS fixator: A prospective study. *Int'l J Orthopaed Sci* 2018; 4: 3837.
- [21]. Parsons SW, Fitzgerald JA, Shearer JR. External fixation of unstable metacarpal and phalangeal fractures. *J Hand Surg Br* 1992; 17: 151-5.
- [22]. Schuind F, Noorbergen M, Andrienne Y, Burny F. Comminuted fractures of the base of the first metacarpal treated by distraction-external fixation. *J Orthop Trauma* 1988; 2: 314-21.

Dr. Sunil Choudhary, et. al. "Functional and Radiological Outcome of Mini Jess Fixator in Hand Trauma - A Prospective Study." *IOSR Journal of Dental and Medical Sciences (IOSR-JDMS)*, 22(4), 2023, pp. 40-44.