

# Optical Coherence Tomography Based Angiography Biomarkers For Predicting Visual Outcomes After Intravitreal Injection Of Ranibizumab In Diabetic Macular Edema

Dr . Bhagyashree<sup>1</sup>, Dr.(Sr. Prof) Nagendra Shekhawat<sup>2</sup>, Dr. Anushka Sharma<sup>3</sup>

<sup>1</sup>(Resident, Department Of Ophthalmology, S.M.S. Medical College, Jaipur, India)

<sup>2</sup>(Senior Professor, Department Of Ophthalmology, S.M.S. Medical College, Jaipur, India)

<sup>3</sup>(Resident, Department Of Ophthalmology, S.M.S. Medical College, Jaipur, India)

## Abstract:

**Background:** To predict the extent of visual improvement after ranibizumab treatment for diabetic macular edema (DME) with OCTA biomarkers.

**Materials and Methods:** Thirty eyes of 30 patients with DME and 30 eyes of 30 healthy persons were taken . Each eye underwent OCT angiography and OCTA image of the superficial layer was obtained at baseline and 1 month after 3 intravitreal injections of Ranibizumab at monthly intervals in the study group. OCTA images were also acquired from the control group. Two OCTA biomarkers, including foveal avascular zone area (FAZ-A) and parafoveal vessel density (VD), were analyzed comprehensively. Best-corrected visual acuity (BCVA) and central retinal thickness (CRT) also were obtained.

**Results:** : Eyes with DME had larger FAZ-A and lower VD than those in the control group ( $P < 0.001$  for both ) . After the loading ranibizumab treatment, these OCTA biomarkers improved but did not return to normal levels. Among all biomarkers, higher inner parafoveal VD in the superficial layer at baseline correlated most significantly with visual gain after treatment in the multiple regression model with adjustment for CRT and ellipsoid zone disruption ( $P < 0.001$ ). To predict visual improvement, outer parafoveal VD in the superficial layer at the baseline showed the largest area under the receiver operating characteristic curve (0.787;  $P = 0.004$ ). No baseline OCTA biomarkers showed any significant correlation specifically with anatomic improvement.

**Conclusion:** For eyes with DME, parafoveal VD in the superficial layer at baseline was an independent predictor for visual improvement after the loading ranibizumab treatment.

Date of Submission: 11-06-2023

Date of Acceptance: 21-06-2023

## I. Introduction

Diabetic macular edema (DME) is a leading cause of visual loss in patients with diabetic retinopathy (DR).<sup>[1]</sup> Antibodies against vascular endothelial growth factor (VEGF) and intravitreal steroids have demonstrated robust treatment effects on visual improvement in DME.<sup>[1-3]</sup> However, some patients do not achieve significant visual gain even after resolution of macular edema. Photoreceptor damage with ellipsoid zone disruption and macular ischemia are two possible reasons for poor visual improvement after the remission of macular edema.<sup>[4],[5]</sup> OCT can be used to detect the severity of ellipsoid zone disruption.

Macular ischemia traditionally is evaluated with fluorescein angiography (FA); however, the extent of macular ischemia can be difficult to quantify, and the ischemia around the fovea may not be revealed clearly because of the small area of involvement and capillary leakage from the adjacent area. OCT angiography (OCTA) is a noninvasive technique that shows the retinal vascular structure with an increased resolution compared with FA. Quantified microvascular parameters also can be obtained from OCTA images. Disorganization of the retinal inner layers with a larger foveal avascular zone (FAZ) has been shown to correlate with poor visual acuity (VA) in patients with resolved DME.<sup>[6]</sup>

The purpose of this study was to establish the correlation between quantitative OCTA features and clinical testing parameters and to verify whether quantitative OCTA parameters can serve as objective factors to predict visual improvement after treatment with ranibizumab for DME. Two OCTA biomarkers, FAZ area (FAZ-A) and vessel density (VD), were analyzed comprehensively and their correlations with clinical markers, that is, best-corrected visual acuity (BCVA) and central retinal thickness (CRT), were evaluated quantitatively.

## **II. Aims and objectives**

To study changes in Foveal Avascular Zone (FAZ) area and Vessel Density in superficial capillary plexus of retina in diabetic macular edema patients treated with anti-VEGF using OCTA.

To assess the pre injection and post injection Best Corrected Visual Acuity (BCVA) and central retinal thickness (CRT) of diseased eye.

## **III. Material And Methods**

This prospective interventional study was carried out on patients of Department of Ophthalmology at Sawai Man Singh Medical College and Hospital, Jaipur, Rajasthan from May 2021 to April 2022. A total 30 adult subjects (both male and females) of aged  $\geq 18$ , years were for in this study. (10)

**Study Design:** Prospective interventional study

**Study Location:** This was a tertiary care teaching hospital based study done in Department of Ophthalmology at Sawai Man Singh Medical College and Hospital, Jaipur, Rajasthan (10)

**Study Duration:** May 2021 to April 2022

**Sample size:** 30 patients.

**Sample size calculation:** Sample size was calculated at 95% confidence level and study power of 80% assuming the mean difference of  $0.21 \pm 0.28$  mm<sup>2</sup> of FAZ area at baseline v/s 3 months of anti VEGF treatment as per seed article. (Ophthalmol Retina. 2019 October ; 3(10): 826–834.

doi:10.1016/j.oret.2019.04.027.OCT Angiography Biomarkers for Predicting Visual Outcomes after Ranibizumab Treatment for Diabetic Macular Edema.

Yi-Ting Hsieh, MD, PhD1, Minhaj Nur Alam, MS2, David Le, BS2, Chia-Chieh Hsiao, MD1, Chang-Hao Yang, MD, PhD1,3, Daniel L. Chao, MD, PhD4, Xincheng Yao, PhD2  
1Department of Ophthalmology, National Taiwan University Hospital, Taipei, Taiwan.)

For the detection of mean difference of  $0.21 \pm 0.28$  mm<sup>2</sup>, the required sample size for this study was 30 subjects. (10)

**Subjects & selection method:** The study population was all patients with diabetic macular edema who required anti VEGF treatment who presented to SMS Hospital, Jaipur from May 2021 to April 2022. Patients were divided into two groups- study and control group (each group had 30 patients).

**Inclusion criteria:** (10 Bold)

- DR with focal or diffuse leakage in the macular area documented by FA
- macular edema with the presence of retinal thickening, intraretinal cysts, intraretinal hyperreflective foci, or subretinal fluid as documented by OCT.
- baseline BCVA between 20/400 and 20/40
- baseline CRT of more than 300 mm
- complete data of BCVA and OCTA at baseline and 1 month after the third intravitreal ranibizumab injection (10)

**Exclusion criteria:** (10 Bold)

- eyes with vitreomacular traction or tractional retinal detachment demonstrated by OCT
- eyes with choroidal neovascularization or any other retinal vascular diseases such as retinal vein occlusion documented by FA
- eyes with poor en face OCTA images with a signal strength index of less than 40 because of media opacity or significant motion artifact (10)

**Procedure methodology** (10 Bold)

This interventional study was done at a teaching hospital in Jaipur, India. This study was performed with the approval of the Institutional ethics committee. Written informed consent was obtained from all the patients after giving them a full explanation of the procedure and study. Patients with Diabetic macular edema requiring Ranibizumab injection were recruited for the study. Pre-operatively the medical histories of the patients were recorded. Comprehensive ocular examinations were performed including BCVA, slit lamp examination, Intraocular pressure (IOP) measurements with Non-contact tonometer, dilated funduscopy, OCT (Topcon 3D-OCT-1 Maestro), OCT-A (Zeiss Angioplex OCT angiography).

The diagnosis of DME was made by indirect ophthalmoscopy and OCT. In the pre injection OCT-A scans, the foveal avascular zone and vessel density at superficial layer was measured using the software in the Zeiss Cirrus 5000 angioplex OCT-A. BCVA was also recorded using Snellen’s chart and converted to decimal unit for statistical analysis. Follow up visit was done at 3 months. It included measurement of BCVA, inner parafoveal vessel density, foveal avascular zone area (FAZ) and central retinal thickness by OCTA scans. Statistical analysis was done using suitable test of significance.

**Statistical analysis (10 Bold)**

Collected data (Pre and Post-injection) was entered in Microsoft Excel Worksheet . Mean value ± Standard Deviation (SD) was calculated for all the parameters . Comparison and analysis as per the Aims and Objectives mentioned was done with an appropriate statistical est. Student t tests were used to compare OCTA biomarkers between the study and control group. Linear regression models were used to evaluate the correlations between the baseline OCTA biomarkers and the changes of BCVA and CRT after treatment. A p value less than 0.05 was considered statistically significant.

**IV. Result**

Our study showed that mean age of the patients was 64.50 years (Standard Deviation= 8.80). 11 (36.66%) of the participants had Age: 50-60 Years. 10 (33.3%) of the participants had Age: 61-70 Years. 9 (30%) of the participants had Age: >70 Years. Mean age of the control group was 64.27±9.28 years. Statistical difference was non significant ( p= 0.920 ). 53.34% of participants were male and 46.66% were females in case group and both were 50 % in control group. It shows that diabetic macular edema is common in males in 5<sup>th</sup>-6<sup>th</sup> decade.

Mean Fasting blood sugar value in case group and control group was 102.500 ± 18.57 mmHg and 84.50 ± 8.803 mg/dL respectively and this difference was statistically significant. The mean value of Post prandial sugar in case group and control group was 157.53 ± 24.63 and 169.46 ± 16.98 respectively and this was statistically significant. Mean HbA1c (in percent) in case group and control group was 8.510 ± 1.720 % and 4.900 ± 1.074 % respectively and this difference was statistically significant.

Our study showed that the mean foveal avascular zone area pre intravitreal injection of Ranibizumab is 0.627 mm<sup>2</sup> and decreased post 1 month after 3 intravitreal injections of Ranibizumab to 0.549 mm<sup>2</sup> in the study group.

The mean vessel density at superficial capillary plexus of retina pre injection is 39.78 and increased post 1 month after 3 intravitreal injections of Ranibizumab to 43.27 in the study group.

Our study showed that the best corrected visual acuity (logMAR) pre injection is 0.792 and it improved post 1 month after 3 intravitreal injections of Ranibizumab to 0.642 in the study group.

The mean central retinal thickness pre injection was 454.56 µm and it decreased post 1 month after 3 intravitreal injections of Ranibizumab to 393.13 µm in the study group

**Table 1: Comparison of FAZ, VD, BCVA, CRT values between case and control group pre injection and 1 month post injections.**

	Foveal Avascular Zone (Mean ± SD)		Vessel Density (Mean ± SD)		BCVA (In logMAR ) (Mean ± SD)		Central Retinal Thickness (Mean ± SD)		P value**
	Case Group	Control Group	Case Group	Control Group	Case Group	Control Group	Case Group	Control Group	
<b>Pre Injection</b>	0.627±0.160	0.347±0.046	39.78±5.42	51.734±3.463	0.792±0.299	0.326±0.087	454.567±104.742	254.533±8.862	<0.001
<b>1 Month</b>	0.549±0.150	0.342±0.055	43.27±5.14	51.731±3.471	0.642±0.317	0.324±0.088	392.133±104.952	255.600±9.565	<0.001
<b>P value*</b>	<0.001	0.199	<0.001	0.580	<0.001	0.609	<0.001	0.037	<0.001

\* this p value shows statistical difference between values taken pre injection and 1 month after ranibizumab injections.

\*\*this p value shows statistical difference of different parameters between case group and control group.

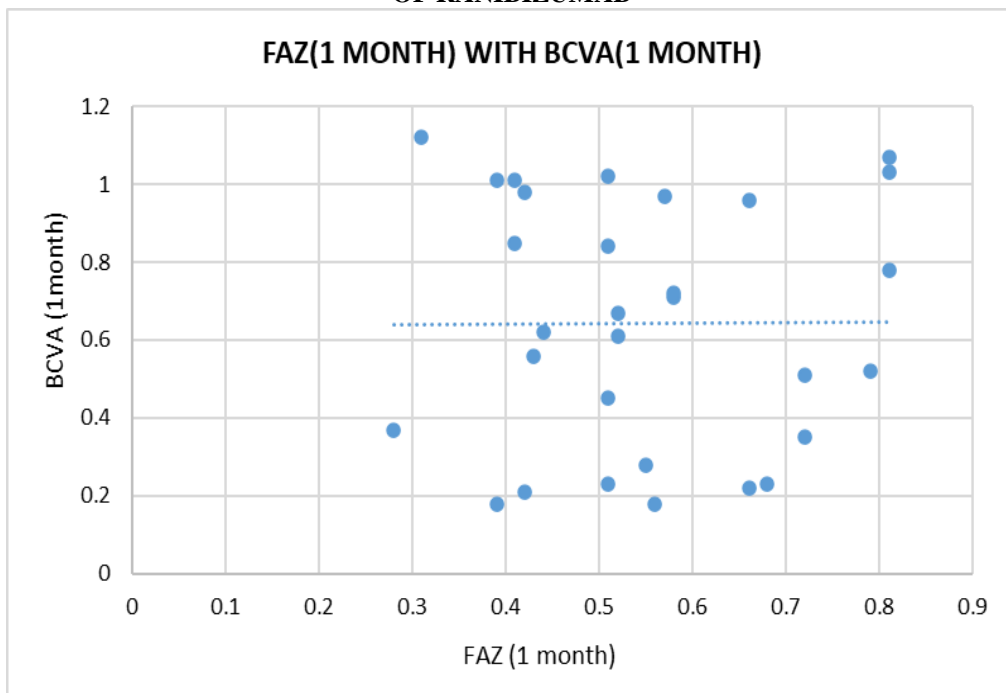
Graph 1 showed weak positive correlation between FAZ area and BCVA post 1 month after 3 intravitreal injections of Ranibizumab i.e. as FAZ area decreased, BCVA improved. But the correlation was not significant.

Graph 2 showed weak positive correlation between FAZ area and CRT post 1 month after 3 intravitreal injections of Ranibizumab i.e. as FAZ area decreased, CRT decreased. But the correlation was not significant.

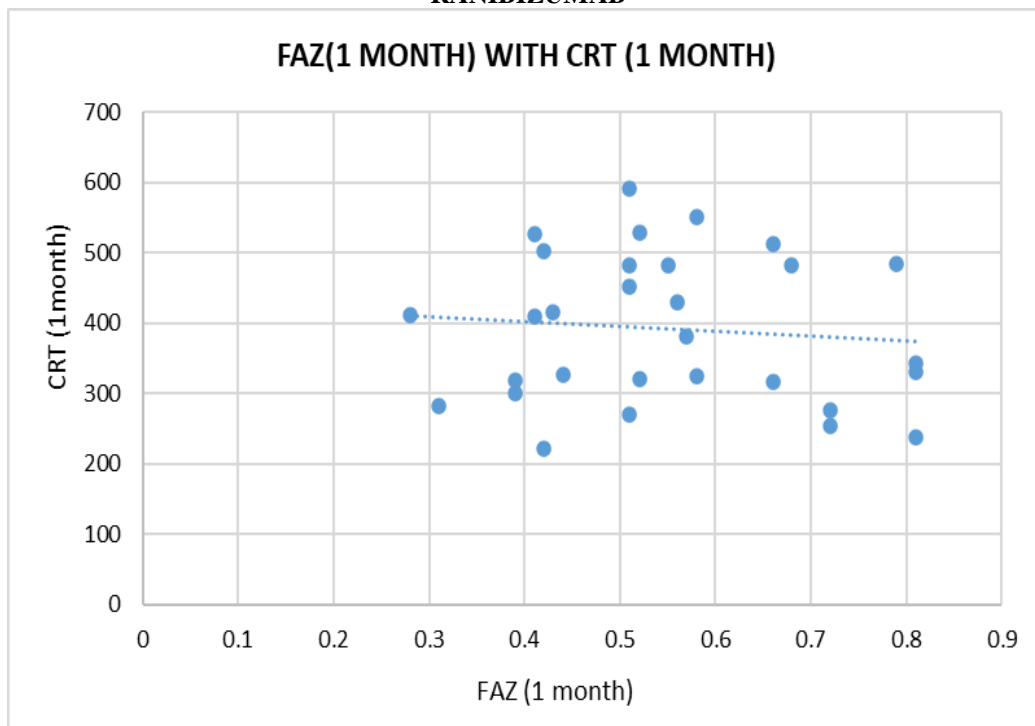
Graph 3 showed strong negative correlation between vessel density at superficial capillary plexus and BCVA post 1 month after 3 intravitreal injections of Ranibizumab i.e. as vessel density increased, BCVA improved. The correlation was significant.

Graph 4 showed weak negative correlation between vessel density at superficial capillary plexus and CRT post 1 month after 3 intravitreal injections of Ranibizumab i.e. as vessel density increased, CRT decreased. The correlation was not significant.

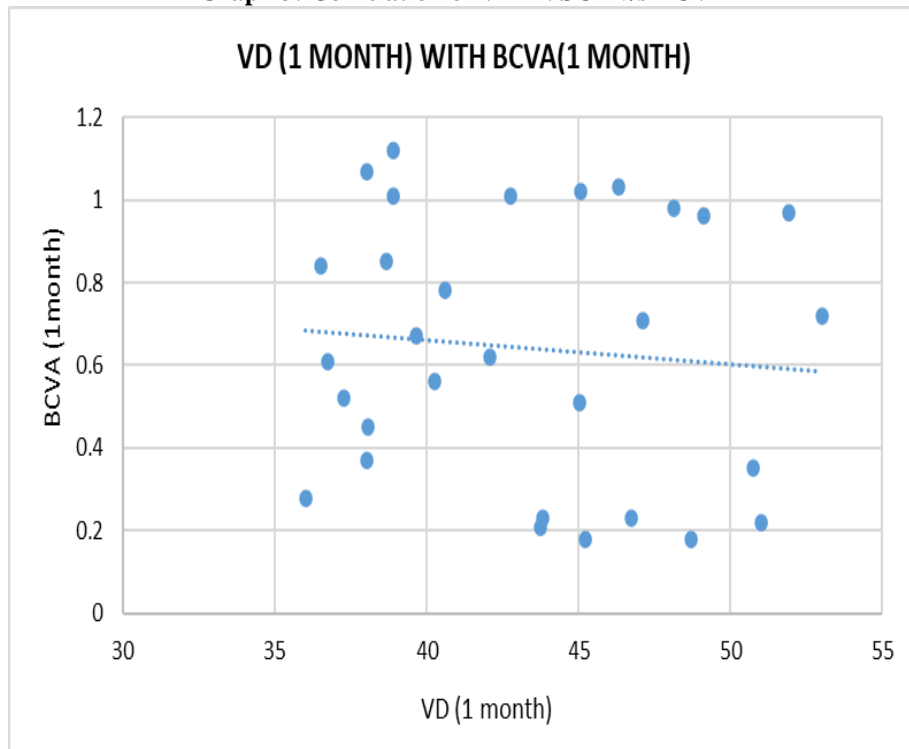
**Graph 1: Correlation of FAZ v/s BCVA POST 1 MONTH AFTER 3 INTRAVITREAL INJECTIONS OF RANIBIZUMAB**



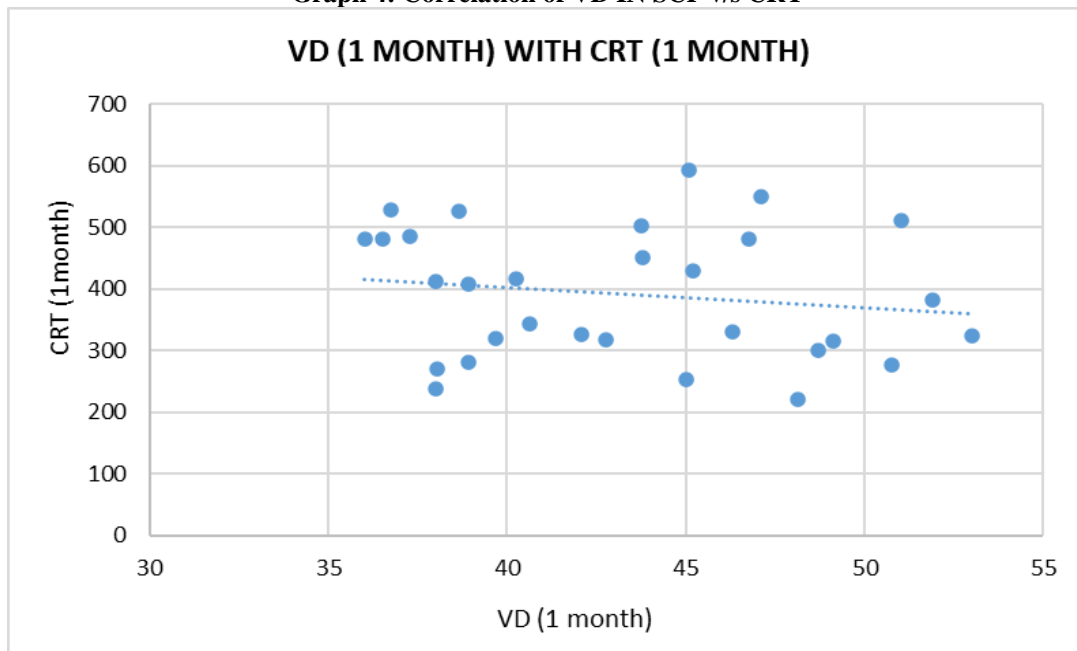
**Graph 2: Correlation of FAZ v/s CRT POST 1 MONTH AFTER 3 INTRAVITREAL INJECTIONS OF RANIBIZUMAB**



**Graph 3: Correlation of VD IN SCP v/s BCVA**



**Graph 4: Correlation of VD IN SCP v/s CRT**



## V. Discussion

OCT angiography has been an effective and noninvasive tool for investigating retinal vascular diseases such as DR. In this study, we first assessed the changes in OCTA parameters before and after giving 3 intravitreal injections of Ranibizumab on individual level and also correlated them with visual and anatomic outcomes in the form of BCVA and CRT respectively.

Samara et al<sup>[7]</sup> showed that poorer VD in SCP at the parafoveal area was correlated with both poorer BCVA and thicker CRT. However, in DME, this finding may suggest that poorer parafoveal vascular perfusion itself could result in poorer vision, or it could be caused by macular edema, which is the real reason for poorer vision. Therefore, when investigating the correlations between baseline OCTA parameters and visual improvement after ranibizumab treatment, we not only adjusted for baseline BCVA, but also for baseline CRT,

because it could affect both BCVA and vessel density. We found that lower parafoveal VD in the superficial layer was correlated with poorer visual improvement after treatment with ranibizumab. This demonstrated that poorer vascular perfusion itself resulted in visual impairment; even after the macular edema subsided, the vision of the eyes with macular hypoperfusion might not improve significantly. Such a result is useful for offering patients with DME reasonable expectations for treatment effects after undergoing anti-VEGF treatment.

It also has been shown that a larger FAZ-A and a poorer VD were associated with poorer VA in patients with DR. As for the clinical treatment for DME, ophthalmologists mostly focus on treating macular edema. However, not all patients who have achieved macular edema resolution show significant improvement in VA. It is possible that macular ischemia, in addition to macular edema and photoreceptor disruption, also contribute to the poor vision in these patients. However, whether baseline OCTA characteristics can be used to predict the visual improvement after treatment for DME has not been studied until the present study.

Durbin et al<sup>[8]</sup> showed that VD in the superficial layer, not the deep layer, was correlated with VA in DR. Our study also showed similar findings. It is possible that the projection artifact affects the deep layer more than the superficial layer. In addition, because all these patients had macular edema, the decay of image signals is more severe as the light source penetrates deeper in the retina. In the present study, we found that FAZ-A significantly decreased after ranibizumab treatment. This may have been the result of the nonperfused parafoveal capillary network becoming reperfused again after the macular edema subsided or of the capillary network masked by severe macular edema being detected better by OCTA after the macular edema subsided. However, FAZ-A was not correlated significantly with VA at baseline or with visual improvement after treatment. Although we found in the present study that the mean FAZ-A was larger in eyes with DME than those in normal eyes, the size and contour of FAZ may vary widely among normal populations.

Lee et al<sup>[9]</sup> found that DME patients who show a poor response to anti-VEGF treatment demonstrate a larger FAZ-A in the DCP. Our results showed that FAZ-A could not be used to predict visual improvement after ranibizumab treatment in eyes with DME. There were some limitations in this study. First, macular edema itself may affect the signal strength of OCTA measurement. Therefore, those with very severe macular edema would have been excluded in this study because of low SSI. Second, as mentioned previously, the projection artifact may interfere more with the imaging

quality of the superficial layer. With future advancements in OCTA hardware and software, we will be able to identify more precise predictors for the treatment outcomes of DME.

## VI. Conclusion

In conclusion, we found that parafoveal vessel density in the superficial retinal layer at baseline was an independent predictor for visual improvement after the loading ranibizumab treatment in eyes with DME. OCT angiography offers measurement for VD in the macula and could be used to predict the visual prognosis of anti-VEGF treatment in DME.

## References

- [1]. Wong TY, Sun J, Kawasaki R, et al. Guidelines on diabetic eye care: the International Council of Ophthalmology recommendations for screening, follow-up, referral, and treatment based on resource settings. *Ophthalmology*. 2018;125: 1608–1622. [PubMed: 29776671].
- [2]. Diabetic Retinopathy Clinical Research Network, Wells JA, Glassman AR, et al. Aflibercept, bevacizumab, or ranibizumab for diabetic macular edema. *N Engl J Med*. 2015;372: 1193–1203. [PubMed: 25692915].
- [3]. Lattanzio R, Cicinelli MV, Bandello F. Intravitreal steroids in diabetic macular edema. *Dev Ophthalmol*. 2017;60:78–90. [PubMed: 28427068].
- [4]. Douvali M, Chatziralli IP, Theodosiadis PG, et al. Effect of macular ischemia on intravitreal ranibizumab treatment for diabetic macular edema. *Ophthalmologica*. 2014;232: 136–143. [PubMed: 25171753].
- [5]. Serizawa S, Ohkoshi K, Minowa Y, Soejima K. Interdigitation zone band restoration after treatment of diabetic macular edema. *Curr Eye Res*. 2016;41:1229–1234. [PubMed: 26828673] Hsieh et al. Page 9 *Ophthalmol Retina*. Author manuscript; available in PMC 2019 December 19. Author Manuscript Author Manuscript Author Manuscript Author Manuscript.
- [6]. Moein HR, Novais EA, Rebhun CB, et al. Optical coherence tomography angiography to detect macular capillary ischemia in patients with inner retinal changes after resolved diabetic macular edema. *Retina*. 2018;38:2277–2284. [PubMed: 29068912].
- [7]. Samara WA, Shahlaee A, Adam MK, et al. Quantification of diabetic macular ischemia using optical coherence tomography angiography and its relationship with visual acuity. *Ophthalmology*. 2017;124:235–244. [PubMed: 27887743].
- [8]. Durbin MK, An L, Shemonski ND, et al. Quantification of retinal microvascular density in optical coherence tomographic angiography images in diabetic retinopathy. *JAMA Ophthalmol*. 2017;135:370–376.
- [9]. Lee J, Moon BG, Cho AR, Yoon YH. Optical coherence tomography angiography of DME and its association with anti-VEGF treatment response. *Ophthalmology*. 2016;123: 2368–2375.