

Single Tooth Replacement By Implant: A Case Report.

Dr Rujuta Churi, Dr Jyoti Tembhurne, Dr Arti Gangurde

Abstract:

For many years, conventional fixed bridges were considered to be the best treatment option for the replacement of missing single tooth. But extensive teeth preparations can result in devitalization of the pulp which later requires root canal therapy. The use of implant-supported single crowns has become a well-established and preferred approach to compensate missing single teeth. There are two different types of prosthetic restorations fixed on dental implants: Screw-retained and cemented restorations. This case report demonstrates the replacement of a missing mandibular molar using a screw retained implant prosthesis.

Date of Submission: 11-06-2023

Date of Acceptance: 21-06-2023

I. Introduction:

This article describes a case report of rehabilitation of missing mandibular 1st molar by implant supported screw retained prosthesis. A 37 year old male with missing left mandibular molar was reported to the dept of prosthodontics in GDC&H Mumbai. Comprehensive examination revealed that the patient had undergone extraction of the tooth 3 months back due to extensive caries and non-salvageable tooth structure. The edentulous ridge was examined and it was suitable for adequate dimensions of 1st molar. The adjacent teeth were vital with amalgam fillings placed. Radiographic examination showed the feasibility of implant placement in the edentulous site. A surgery was performed for implant placement. The determination of implant size imposes a three-dimensional evaluation of bone thickness. A minimum of 1.5 mm between the implant fixture and adjacent roots is required to avoid bone resorption and be in favor of papilla regeneration. Ideal tri-dimensional positioning of dental implants, requires adequate edentulous ridge with sufficient bone thickness.

II. Clinical report and procedure:

A 37-year-old male patient, with missing mandibular first molar, was reported to the department of prosthodontics after extraction. He expressed his wish for a minimally invasive treatment approach. Comprehensive examination revealed that an extraction treatment was done with respect to 36, due to caries and non-salvageable tooth structure, three months prior. The adjacent teeth are vital, with amalgam fillings placed in them, with a suitable crown volume and height. Oral hygiene was evaluated as good. (Fig.1&2)

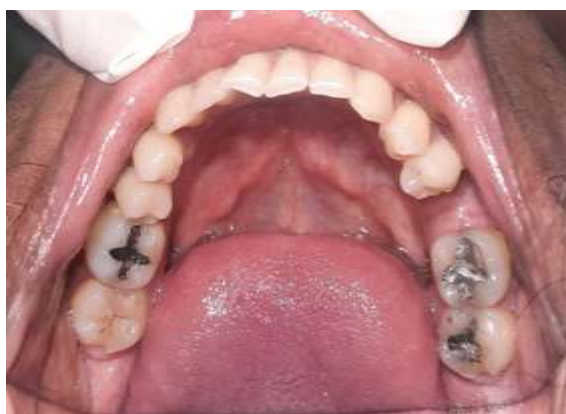

Fig. 1: Pre-op condition of patients arch

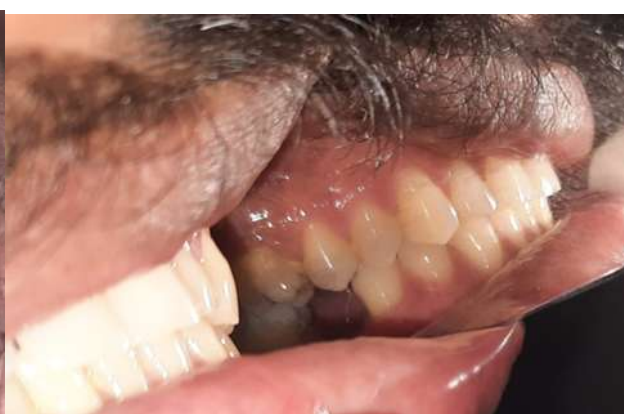

Fig. 2: Crown Height Space for restoration

Radiographic evaluation Cone Beam Computed Tomography (CBCT) showed the feasibility of implant placement in the edentulous site. It revealed thick cortical bone and adequate cancellous bone of type 3 quality in the molar area based on the classification of Lekholm and Zarb and no remarkable alveolar ridge resorption. The edentulous ridge was measured and it was suitable for adequate dimensions of a molar. The mandibular canal was placed off-center buccally of the mandible buccolingually and in the inferior 1/3 of the mandible

vertically, at a distance approximately 15.3mm from the alveolar crest. The buccolingual width of the edentulous site was 6.4mm (fig. 3&4). The decision of implant supported crown was so retained.

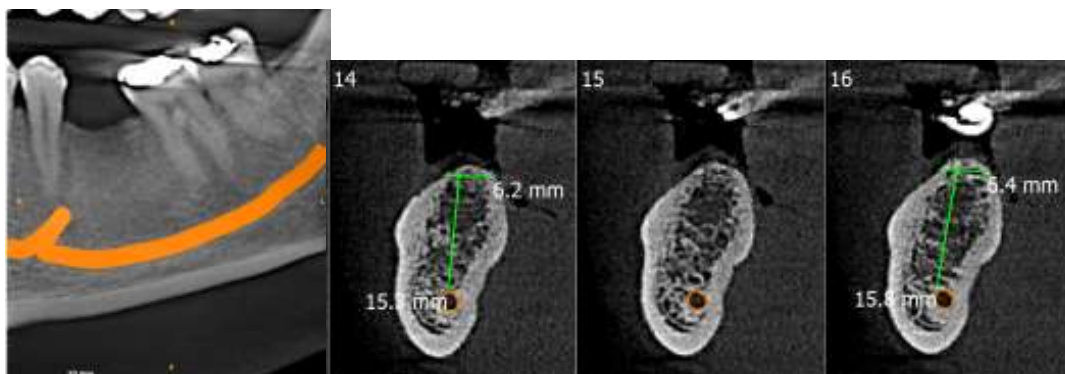


Fig. 3&4: CBCT of the concerned area

After administration of local anesthesia with a 2% lignocaine hydrochloride solution containing adrenaline at 1:80000mg, a flap was raised. Crestal, sulcular incisions were given (fig. 5&6). When drilling the implant site, a direction indicator was used to check the orientation of the fixture. An implant fixture (diameter 4.5 mm; Length 10 mm) was then placed (fig. 7,8,9&10). Initial stability was good (20 Ncm torque).

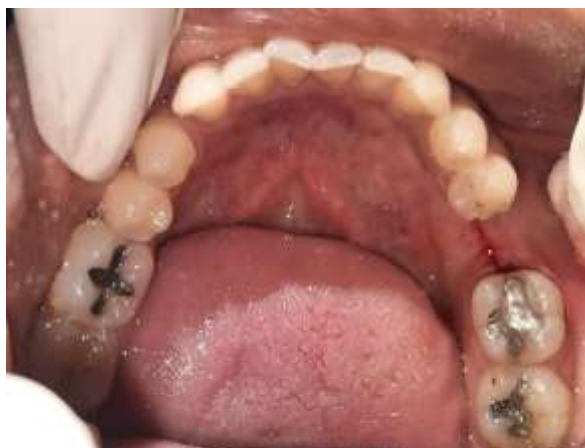

Fig. 5: Crestal and sulcular incision

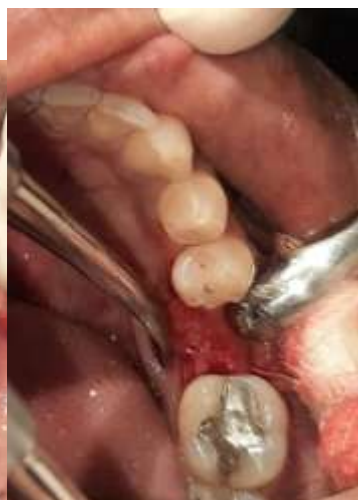

Fig. 6: Flap raised

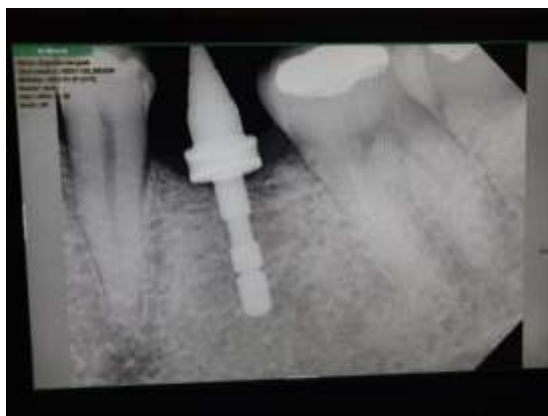

Fig. 7: Direction of the initial drill

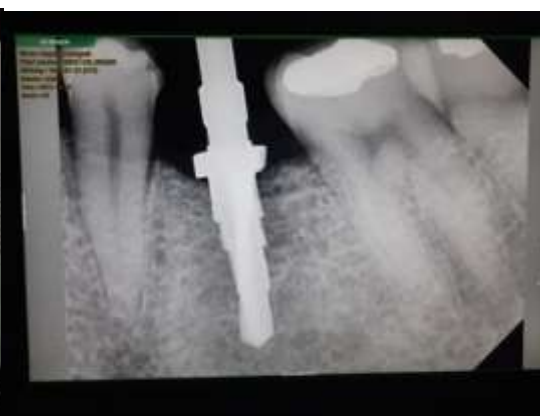

Fig. 8: Final drill

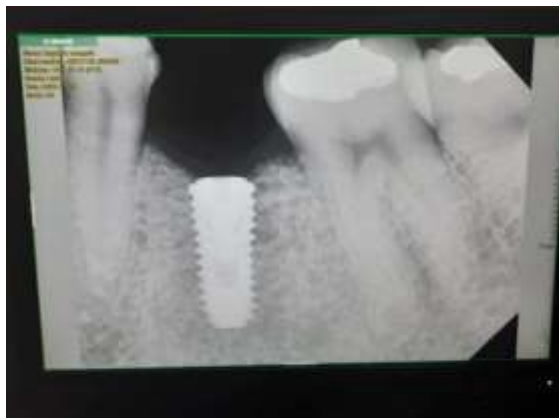

Fig. 9: Implant placed

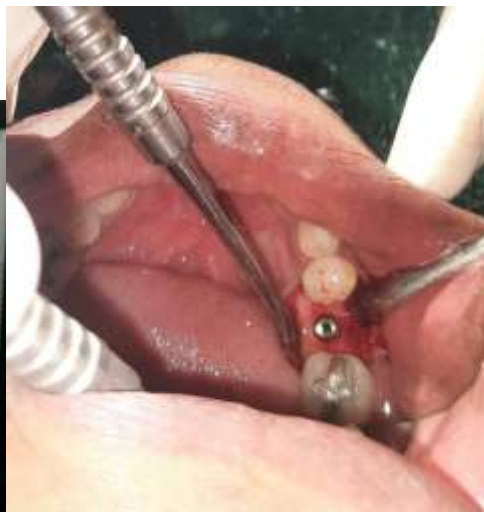

Fig. 10: Cover screw placed

As aesthetic was not a concern, provisional restoration was not given. One week post implant placement, sutures were removed and peri-implant tissues health was ideal. During the healing period, the patient did not express discomfort or neurological symptoms. Peri implant bone was also subsequently monitored by radiological evaluation. Osseointegration was excellent and no bone resorption has been observed around the implant.

After 3 months of healing and management of peri-implant soft tissues, a healing abutment was placed by giving only a small crestal incision (fig. 11)

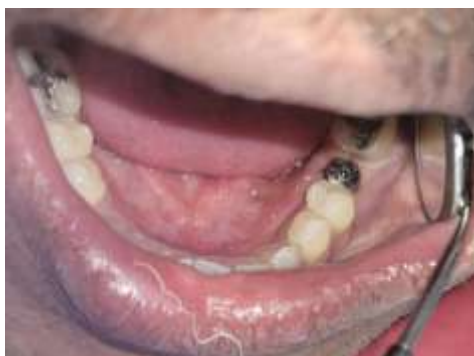

Fig. 11: Healing abutment placed

After waiting for 10 days, healing was evaluated. It was excellent with healthy perioral tissues (fig. 12). An accurate impression using the open tray technique was then performed. It uses copings and an open tray allowing the coronal coping screw to be exposed. The copings are then unscrewed to be removed along with the impression. The analogs are connected to the copings to fabricate the definitive cast (fig. 13)

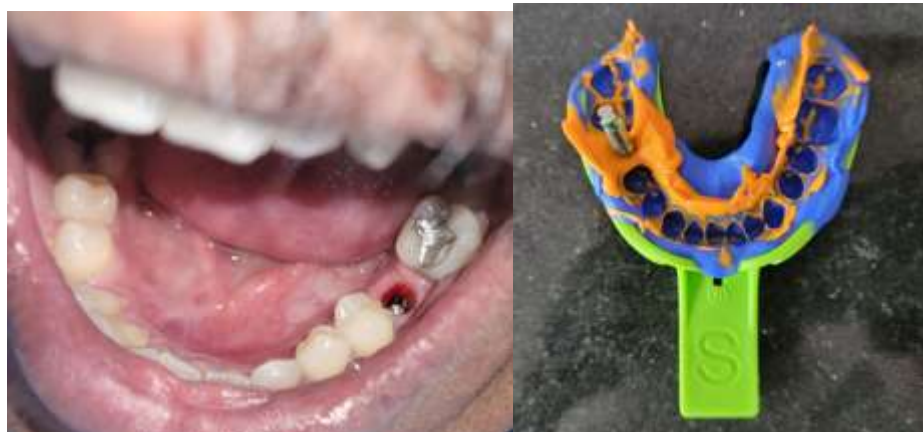

Fig. 12: Soft tissue healing

Fig. 13: Open tray Impression

A jig trial was fabricated and tried, which fitted perfectly(fig. 14,15 &16).Then an abutment was selected and prepared according to the adjacent and opposite teeth. A metal trial was fabricated over it and tried in the patient's mouth(fig. 17). The fitting was evaluated and a final restoration, which consists of metal ceramic crown, was fabricated(fig. 18&19). The fit was checked, and occlusion was adjusted for axial loads, by using articulating paper(fig. 20). A post-operative radiograph was taken after delivery of the final prosthesis(fig. 21).

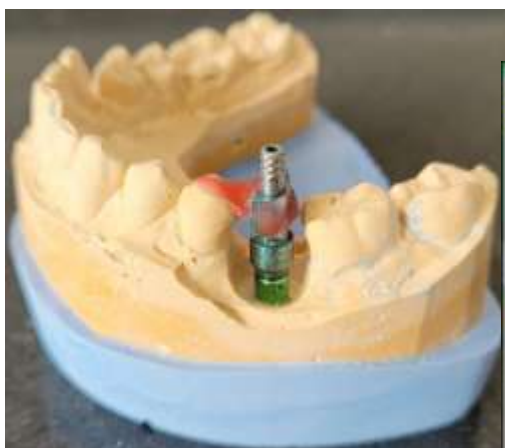

Fig. 14: Jig trial fabricated

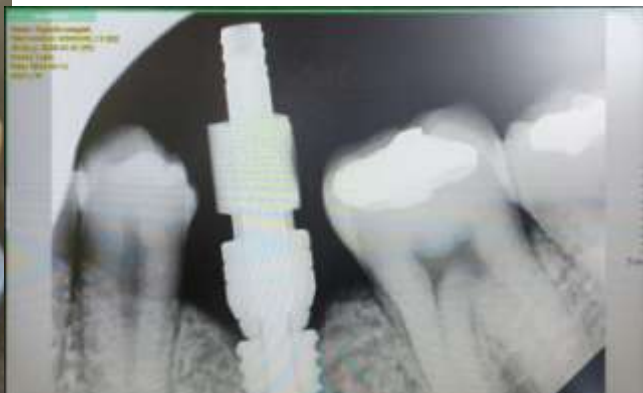

Fig. 15: Radiographic evaluation of fitting

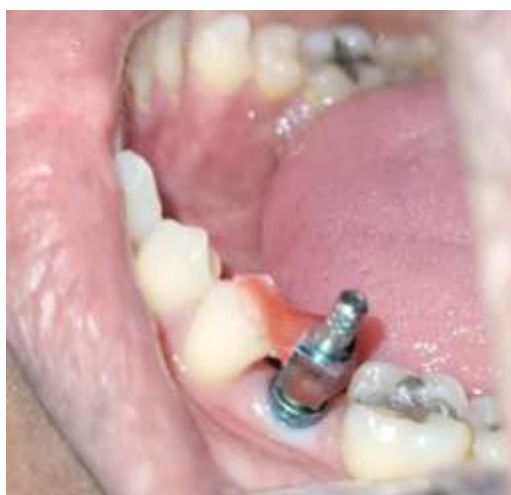

Fig. 16: fit checked intraorally

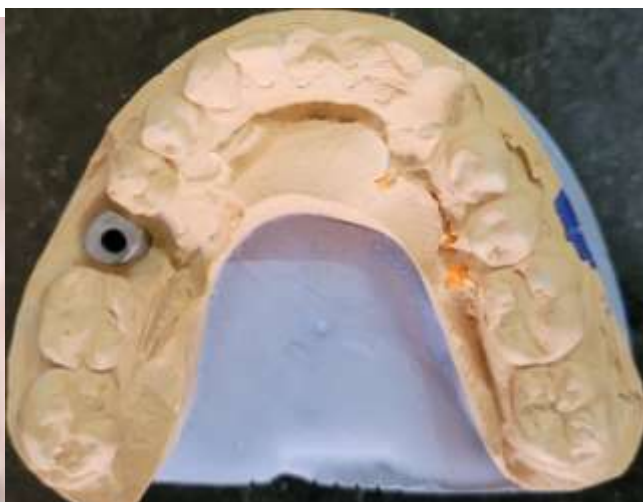
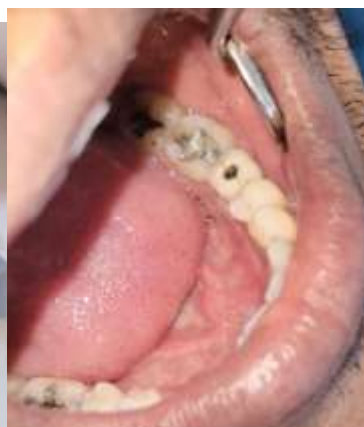
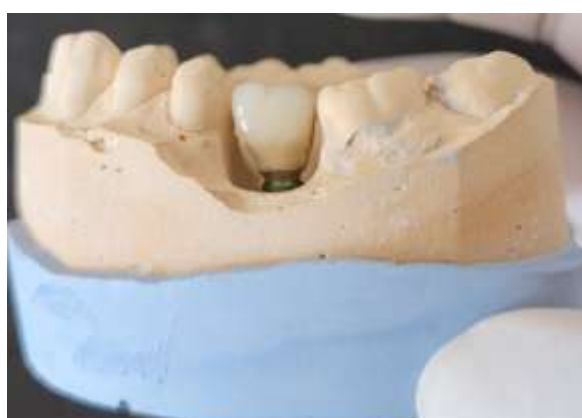Fig. 17: metal try in



Figs. 18&19: final prosthesis

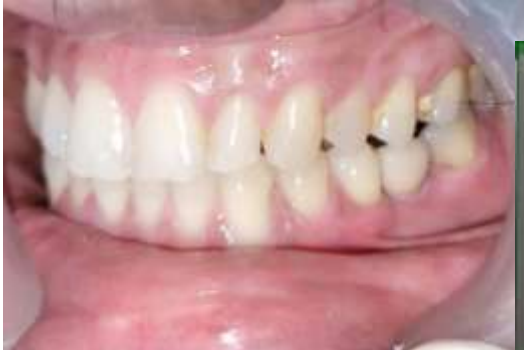

Fig. 20: In-Occlusion

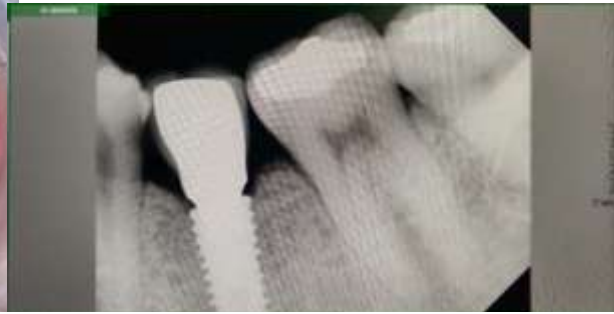

Fig. 21: Final prosthesis radiograph

After prosthetic treatment was completed, a follow up program was carried out for the patient. It offers the opportunity to examine the patient every 6 months in the first year and every 12 months in subsequent years.

III. Conclusion:

Replacing single missing teeth with implants is very successful and predictable. Successful osseointegration is possible in delayed implant placement. Soft tissue healing was satisfactory. It has numerous advantages over the conventional dental bridge. A single implant can serve as a good long-term and predictable treatment modality to replace a single molar with low complication and failure rates.

References:

- [1]. Assaf M, Gharbyeh AZA. Screw-retained crown restorations of single implants: A step-by-step clinical guide. *Eur J Dent.* 2014 Oct;8(4):563-570. doi: 10.4103/1305-7456.143645. PMID: 25512742; PMCID: PMC4253117.
- [2]. Rehabilitation single tooth loss with screw retained implant crown: Case report. Jane Amelia Vebriani Wibisono11Prosthodontic Departement, Faculty of Dentistry Maranatha Christian University, Indonesia *SONDE (Sound of Dentistry) Vol 6 No 1*
- [3]. Chandra Sekar A, Praveen M, Saxena A, Gautam A. Immediate implant placement: a case report. *J Indian Prosthodont Soc.* 2012 Jun;12(2):120-2. doi: 10.1007/s13191-012-0120-2. Epub 2012 Jun 2. PMID: 23858286; PMCID: PMC3382368.
- [4]. Kaur G, Jagadeesh H. G., Vikram J, Anand D, Single tooth implant placement with immediate temporisation: Case report. *IP Ann Prosthodont Restor Dent* 2018;4(2):47-49
- [5]. Vivek, Rajul & Soni, Romesh. (2015). Single Tooth Implant Placement in Anterior Maxilla: A Case Report. *Journal of Medical Science And clinical Research.* 10.18535/jmscr/v3i9.52.
- [6]. Hotta, Y., Ito, K., Komatsu, S. et al. Case presentation of two patients using diagonal platform-switched double implants for maxillary single-first-molar replacement as the alternative of a single-tooth implant. *Int J Implant Dent* 1, 29 (2015). <https://doi.org/10.1186/s40729-015-0031-1>