

Prosthodontic Management Of Acquired Maxillary Defect In Post-Covid Mucormycosis Patient:- A Case Report

Dr Sanjay Lagdive¹, Dr Rupal J Shah², Dr Real Brahmhatt³, Dr Pallavi Naik⁴,
Dr Monika Varma⁵

¹ Professor, Prosthodontics, Government Dental College & Hospital, Ahmedabad. ² Hod & Professor, Prosthodontics, Government Dental College & Hospital, Ahmedabad. ³ Post-Graduate Student, Prosthodontics, Government Dental College & Hospital, Ahmedabad. ⁴ Post-Graduate Student, Prosthodontics, Government Dental College & Hospital, Ahmedabad. ⁵ Post-Graduate Student, Prosthodontics, Government Dental College & Hospital, Ahmedabad.

Abstract

Mucormycosis Is An Opportunistic, Life-Threatening Fungal Disease That Mainly Affects Population With Reduced Immunity. Moreover It's Prevalence Has Upstriked Tremendously Post Covid-19 Pandemic. Immunosuppression Prevalled Due To Use Of Corticosteroid , Which Were Used For Management Of Covid-19 Patients, Has Been An Amplifying Factor For Mucormycosis Cases. The Progression Of The Fungus Can Cause It To Infiltrate The Palate, Sphenoid Sinus, Cavernous Sinus, Orbits, Or Even The Brain Via The Skull. Oral Ulceration Is Preceded By Pain And Swelling, And The Tissue Necrosis That Develops As A Result Might Lead To Palatal Perforation. Infection Spreads From The Sinuses Into The Mouth And Causes Ulcerations Of The Hard Palate That Are Painful And May Become Necrotic. One Such Case Of Maxillary Mucormycosis With Palatal Defect Came To The Department Of Prosthodontics, Government Dental College And Hospital, Ahmedabad. This Case Report Mentions Thorough Diagnosis And Treatment Planning For The Maxillary Mucormycosis Patient.

Keywords: Mucormycosis, Prosthetic Rehabilitation, Maxillectomy, Post-Covid.

Date of Submission: 17-06-2023

Date of Acceptance: 27-06-2023

I. Introduction

The Black Fungus, Also Known As Mucormycosis, Was One Of The Worst Side Effects Of Covid -19 Infection During The Second Wave In India. Uncontrolled Hyperglycemia, Overuse Of Corticosteroids For Immunosuppression, And Extended Hospitalizations In The Intensive Care Unit Are The Most Often Cited Factors In The Growth Of Mucormycosis In Covid-19 Patients(1,2). This Deadly Fungal Infection's Mortality And Morbidity Were Lowered By Early Detection And Treatment. The Post-Surgical Maxillary Deformity Is Frequently Linked To Hypernasal Speech, Fluid Leaks Into The Nasal Cavity, And Difficulty In Chewing.(3) The Main Goal Oriented To Prosthodontic Rehabilitation Is To Cover Up The Facial Deformities And Restore Speech, Mastication, And Deglutition Function. Restoration Of Such Flaws Should Focus On Ensuring Appropriate Retention, Greater Stability, And Optimum Vertical Support. The Size Of The Defect, The Number Of Surviving Teeth, The Quantity Of Residual Bone Tissue, And The Patient's Capacity To Adapt To The Prosthesis Are The Factors That Determine Whether The Therapy Is Effective.(4)

Here In For The Below Discussed Case, We Have Fabricated A One Piece Interim Obturator Inclusive Of Palatal Defect, Using Heat-Cure Acrylic Material.

II. Case Report:

A 42 Year Old Patient Reported To The Department Of Prosthodontics And Crown And Bridge, Government Dental College And Hospital, Ahmedabad Three Months Post Operation With The Chief Complaint Of Regurgitation Of Fluids , Inability To Chew Food And Hyper-Nasal Speech. As The Extent Of The Defect Was Very Large, It Was Impossible To Close It With Surgical Flap. Therefore, Only Option Available Was Prosthetic Rehabilitation. An Intra Oral Examination Revealed A Large Defect Extending(Class 4 Defect According To Aramany's Classification) Till Nasal Cavity, Exposing Nasal Septum, Nasal Conchae And Loss Of Teeth Respective To Resected Site(Fig:1).

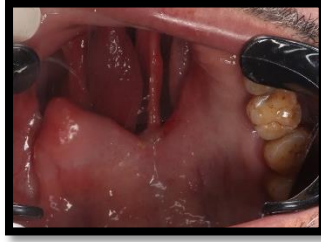

Figure 1:- Intraoral View Of The Maxillary Defect

Before Making Primary Impression The Internal Defect Was Covered With Adequate Gauze Piece. Preliminary And Final Impressions Were Made And Casts Were Poured Out Of Type 3 Dental Stone Respectively (Fig:2a, 2b, 2c, 2d)

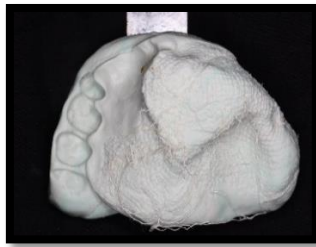

Figure 2a:- Primary Impression

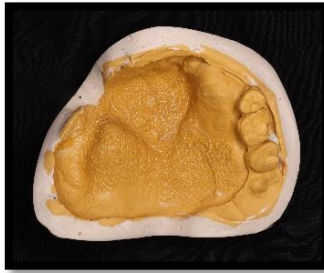

Figure 2b:- Primary Cast

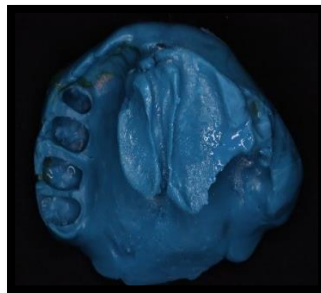


Figure 2c:- Final Impression

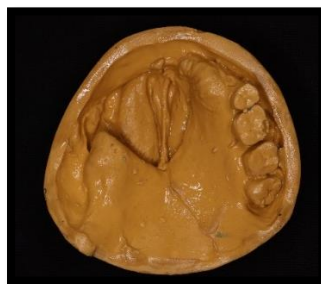

Figure 2d:- Final Cast

Self-Curing Resin Was Used To Make Denture Base, Onto Which Occlusal Rims Were Fabricated For Recording Jaw Relation (Fig:3).

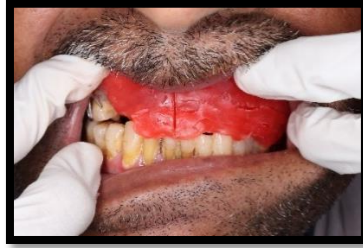

Figure 3:- Jaw Relation Recorded(Frontal View)

After Choosing The Proper Teeth Size, Teeth Setting Was Done Followed By Denture Try-In(Fig:4a,B,C).The Trial Denture Was Confirmed Intraorally And Occlusion Was Checked.

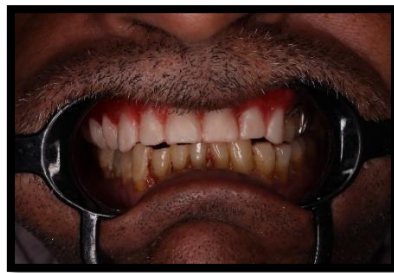

Figure 4a:- Final Denture Try-In (Front View)

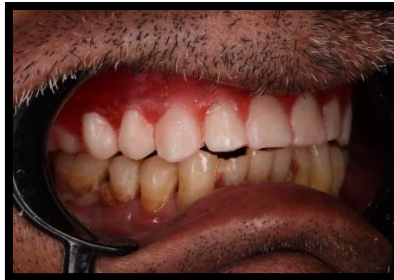

Figure 4b:- Final Denture Try-In (Right Lateral View)

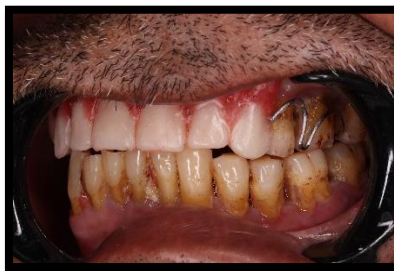

Figure 4c:- Final Denture Try-In (Left Lateral View)

The Final Prosthesis Then Was Fabricated Using Heat Cure Acrylic Resin (Lucitone) (Fig:5a,B).

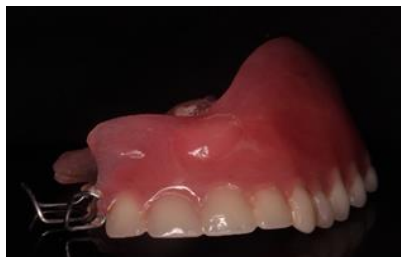

Figure 5a:- Final Prosthesis (Frontal View)

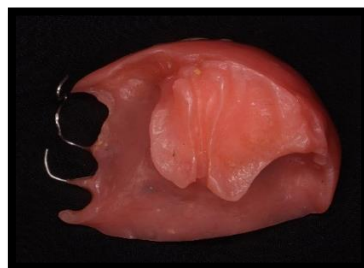

Figure 5b:- Final Prosthesis (Intaglio Surface)

In Order To Ensure Retention, Stability, Occlusion, And Peripheral Seal, The Final Prosthesis Was Intraorally Inserted And Checked(Fig: 6).

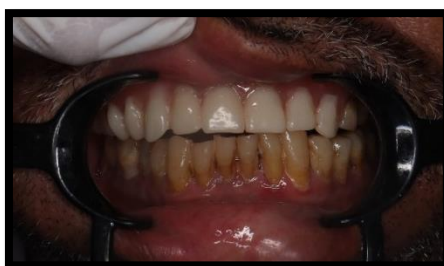

Figure 6:- Final Prosthesis (Intraoral Frontal View)

After Adequate Adjustments Post-Insertion Instructions Were Given. Patient Was Shown And Taught Steps For Insertion And Removal Of Prosthesis Respectively And Oral Hygiene Instructions Were Given. Initially Monthly Follow-Ups Were Taken, And Even After 8 Months Followup The Functionality Of The Prosthesis Was Integral. The Patient Was Happy With The Significant Enhancements In Speech, Mastication , And His Extra-Oral Appearance.

III. Discussion:

Mucormycosis Had Led This Patient With Difficult In Chewing Due To Loss Of Teeth, Regurgitation Of Oral Fluids Due To Palatal Defect, Hyper Nasal Speech – Leading To Poor Communication & Resulting In Phycological Trauma Forbidding Social Interaction(5,6). Extent Of The Palatal Defect After Removal Of The Lesion Was Too Large To Be Closed With A Flap, Thus The Only Option Left Was To Prosthodontically Rehabilitate The Patient. (7)

This Case Report Discusses The Rehabilitation Of The Case 4 Defect Aramany's Defect, The Primary Aim Of The Treatment Or Fabrication Was To Rehabilitate The Form And Function And Gain Back The Functional Integrity. (5)Undercuts Of The Defects Were Used As A Retentive Factor And Additional Metallic Clasp Were Given On The Adjacent Teeth For Extra Support(8). Post Insertion Adjustment Of The Prosthesis Were Done Lining Up To The Patient's Comfort And Satisfaction. Patient Was Taught Insertion And Removal Of The Obturator Following The Specific Parth Of Insertion And Removal Respectively. (9)

IV. Conclusion:

Restoration Of The Palatal Defect Caused By Post-Covid-19 Mucormycosis Is Difficult Because It Necessitates The Improvement Of Speech, Mastication, And Deglutition Functions As Well As The Creation Of A Stable, Retentive And Aesthetically Pleasing Prosthesis That Lessens Psychological Trauma Of The Patient(10).

But, With Peculiar Diagnosis And Treatment Planning The Above Mentioned Goal Can Be Achieved, Restoring Functional Integrity For The Patient. (11)

References:

- [1]. Patil Rb, Chandak A, Radke U, Sahai R, Kumbhare R. Mucormycosis And Its Prosthodontic Management: A Review. *Journal Of Advances In Dental Practice And Research*. 2022 Jun 30;1:18–23.
- [2]. Kalra A, Sharma P. Mucormycosis: A Case Report. Vol. 4, *Journal Of Dental Health & Research*. 2023.
- [3]. Bhuskute M, Medha V, Bhuskute M. Addendum-3). *Journal Of Prosthodontics Dentistry [Internet]*. 17(1):49. Available From: <https://www.researchgate.net/publication/360313934>
- [4]. Sharma A, Goel A. Mucormycosis: Risk Factors, Diagnosis, Treatments, And Challenges During Covid-19 Pandemic. Vol. 67, *Folia Microbiologica*. Springer Science And Business Media B.V.; 2022. P. 363–87.
- [5]. Rathee Drm, Singh Drs, Malik Drs, S Drd, Alam Drm. “Reconstruction And Rehabilitation Of Maxillary Defects Secondary To Mucormycosis.” *Saudi Journal Of Oral And Dental Research*. 2022 Jan 7;7(1):1–7.
- [6]. Sachdev Ss, Chettiankandy Tj, Sardar Ma, Ramaswamy E, Shah Am, Yaduwanshi K. A Comprehensive Review Of Pathogenesis Of Mucormycosis With Implications Of Covid-19: Indian Perspective. *Journal Of Global Oral Health*. 2021 Dec 31;4:116–22.
- [7]. Kumbul Yç, Akin V, Yasan H, Sivrice Me. Use Of Septal Button In Hard Palate Perforation Owing To Mucormycosis: A Case Report. *B-Ent*. 2021 Jan 1;17(1):49–52.
- [8]. Chaurasiya A, Yadav Ns, Hazari P, Badani S, Sultan S. A Case Report On Prosthetic Rehabilitation Of Post-Mucormycosis-Clinical Cases [Internet]. Available From: www.ijfmr.com
- [9]. Naveen S, Cicilia Subbulakshmi A, Babu Susai Raj S, Rathinasamy R, Vikram S, Gokul Raj S. Post Surgical Management Of Palatal Mucormycosis... Naveen S Et Al Case Report Mucormycosis Of The Palate And Its Post-Surgical Management: A Case Report. Vol. 7, *Journal Of International Oral Health*. 2015.
- [10]. Binder U, Maurer E, Lass-Flörl C. Mucormycosis - From The Pathogens To The Disease. Vol. 20, *Clinical Microbiology And Infection*. Elsevier B.V.; 2014. P. 60–6.
- [11]. Sahare P, Kulkarni S, Karmkar K, Badadare M. Open Access Journal Of Clinical Research Case Report Prosthetic Rehabilitation Of Mucormycosis Patients In The Covid 19 Pandemic. 2022.