

## Atrophic Tamoxifen Maculopathy : Case Report

Manal Samie, Samia Zamzami, Ghizlane Daghouj, Loubna El maaloum,  
Bouchra Allali, Asmaa Elkettani

---

### **Abstract :**

*Tamoxifen is an adjuvant hormone therapy used orally in breast cancer. Retinal toxicity to this product is an extremely rare condition. It is frequently characterized by its edematous and dose-dependent form. Stopping this treatment stops the development and prevents bilateralization of the pathology. We report the case of a 46-year-old patient, under hormone therapy with tamoxifen for 3 years for hormone-sensitive breast cancer, in whom atrophic maculopathy was discovered following a gradual decline in visual acuity that has progressed over the past year.*

**Key words :** Tamoxifen, maculopathy, cancer, breast

---

Date of Submission: 02-06-2023

Date of Acceptance: 12-06-2023

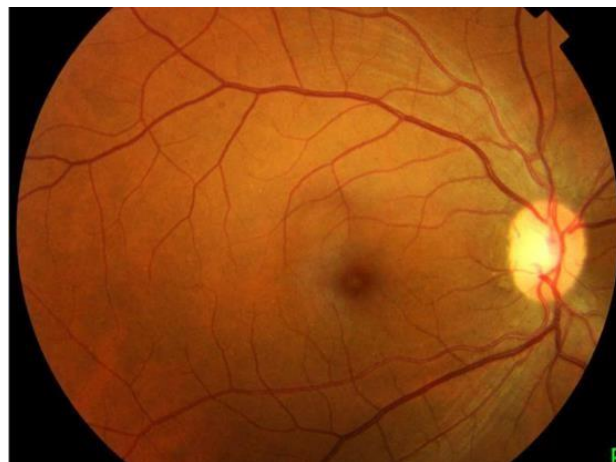
---

### **I. INTRODUCTION :**

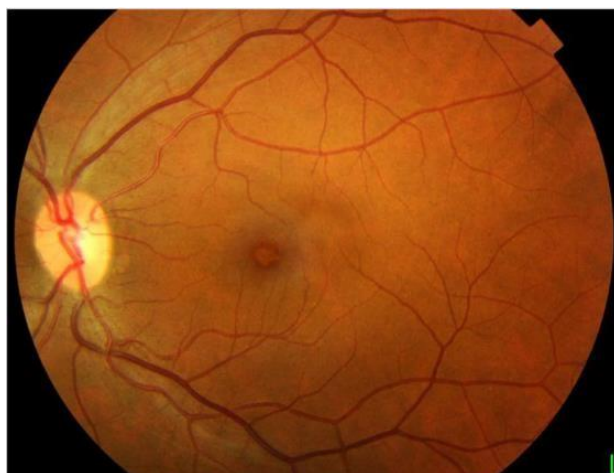Tamoxifen is a selective estrogen receptor modulator used orally in breast cancer. Retinal toxicity to this product is an extremely rare condition. It is frequently characterized by its edematous form, the beginner atrophic form is even less frequent.

### **II. CASE REPORT :**

A 46-year-old patient consults for a gradual decline in bilateral visual acuity that has progressed over the past year. The patient presents with a bilateral well-differentiated invasive lobular adenocarcinoma of the breast for which she underwent a right lumpectomy in 2010 and a left mastectomy in 2017 with additional radiotherapy. The patient had been on hormone therapy with tamoxifen for 3 years. Ophthalmologic examination found bilateral visual acuity of 5/10, the anterior segment was normal, the fundus showed fine perifoveolar pigmentations [figure 1].



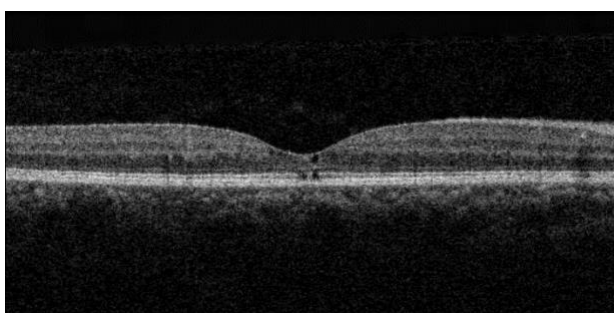
a : right eye



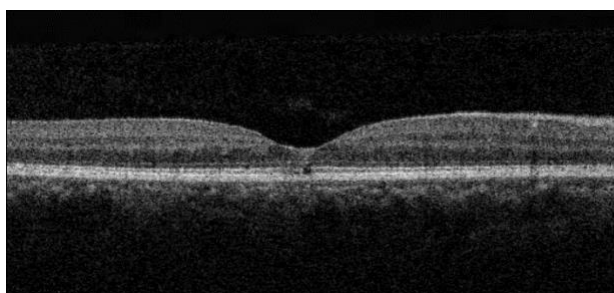
**b : left eye**

**figure 1 : a and b : fine perifoveolar pigmentations The macular optical coherence tomography**

(OCT) shows a localized interruption of the ellipsoid line in retro-foveolar on a surface which does not exceed 60 microns, with an alteration of the outer nuclear layer opposite, and the presence of a few cubicles of degenerative appearance at the level of the foveolar region without visible retinal thickening or exudates [figure 2].



**a : right eye**



**B : left eye**

**figure 2 : a and b : interruption of the ellipsoid line in retro-foveolar**

During the ophthalmologic check-up of our patient, seven months after stopping tamoxifen, visual acuity remained unchanged. Macular optical coherence tomography shows a stationary appearance whether it is the cubicles or the interruption of the external nuclear power.

### **III. DISCUSSION :**

Tamoxifen is an anti-hormonal drug used in the adjuvant treatment of hormone-sensitive breast cancer. This molecule blocks the action of estrogen on the breasts by binding to estrogen receptors.

The first cases of ocular toxicity to tamoxifen were characterized by refractile deposits localized in the inner plexiform layer and in the layer of nerve fibers of the para macular region which may be associated with pigment migrations and cystoid macular edema [1]. The retinal toxicity to this product is dose-dependent, the cumulative dose incriminated is defined from 100g [2].

The pathophysiology of this damage remains poorly understood; it is assumed that tamoxifen is bound to polar lipids, creating complexes that accumulate in lysosomes and alter the neuroepithelium [3].

#### **IV. CONCLUSION :**

The retinal toxicity to tamoxifen is an extremely rare attack, the diagnosis by macular optical coherence tomography and the stop of this treatment makes it possible to stop the evolution in the event of bilateral attack, and to protect the adelphe eye in the event of unilateral involvement.

#### **BIBLIOGRAPHY**

- [1] A.-A. Hui-Bon-Hoa a, S. Defoort-Dhellemmes b, T.H.C. Tran. Atrophic tamoxifen maculopathy. JFO. Doi : 10.1016/j.jfo.2010.09.017
- [2] Vinding T, Nielsen NV. Retinopathy caused by treatment with tamoxifen in low dosage. Acta Ophthalmol Scand 1983;61:45—50.
- [3] Imperia PS, Lazarus HM, Lass J. Ocular complications of systemic cancer chemotherapy. Surv Ophthalmol 1989;34:209— 30.