

Diabetes Muscle Infarction: Rare Complication Of Diabetes Mellitus – A Case Report

Dr. Sabaresh Velayutham¹, Dr. Siva Swaminathan Santhanam²,
Dr. Prince Soloman³, Dr. Ponnilavan Krishnan⁴, Dr. Muralidharan Rajendiran⁵.

¹Department of orthopaedics, Pondicherry Institute of Medical Sciences, Puducherry, India²Department of orthopaedics, Pondicherry Institute of Medical Sciences, Puducherry, India³Department of orthopaedics, Pondicherry Institute of Medical Sciences, Puducherry, India⁴Department of orthopaedics, Pondicherry Institute of Medical Sciences, Puducherry, India⁵Department of orthopaedics, Pondicherry Institute of Medical Sciences, Puducherry, India

Abstract:

Introduction: Diabetic muscle infarction is a rare and often a misdiagnosed complication of poorly controlled diabetes. Early detection and accurate diagnosis play a pivotal role in its management. It can be associated with other complications of poor glycemic control, including nephropathy, retinopathy, and neuropathy. Although, there has been previously reported cases, the incidence is less, probably due to the fact that it is often misdiagnosed.

Case presentation: A 45-year-old male presented with pain and swelling in the distal third of his left thigh for one month. He had been diagnosed with Diabetes mellitus for three years but had not been taking any medication. Examination revealed an ill-defined swelling of size 15*8*2 cm present over the medial aspect of the left distal third thigh. Ultrasonography and Magnetic resonance imaging of left thigh showed features suggesting possibilities of infectious Myositis. HbA1c was 11.0% and random blood sugar was 211mg/dl. Patient underwent Incisional biopsy and tissue culture showed no growth. Histopathology showed features suggestive of myositis secondary to Diabetic muscle infarction. Patient was treated with non-steroidal anti-inflammatory drugs and insulin for glycemic control. At six months follow up, pain and swelling subsided.

Conclusion: Diabetic muscle infarction should be considered as one of the differential diagnosis for uncontrolled diabetic patient presenting with swelling particularly in the lower limb. Although, a biopsy was done here, it is best treated conservatively with analgesics and anti-inflammatory agents.

Keywords: Uncontrolled diabetes mellitus, swelling, muscle infarction.

Date of Submission: 05-06-2023

Date of Acceptance: 15-06-2023

I. INTRODUCTION

Diabetic muscle infarction (DMI) also known as diabetic myonecrosis or septic myonecrosis is a rare complication of diabetes mellitus. It is defined as spontaneous ischemic necrosis of skeletal muscle that is unrelated to atheroembolism or occlusion of major arteries. It was first described in 1965 by Angervall and Stener and termed "tumouriform focal muscle degeneration". It can be associated with complications of poor glycaemic control, including nephropathy, retinopathy, and/or neuropathy. Most patients present with painful swelling of affected muscle, most often in the lower extremities. It is acute in onset and develops over days or weeks, with no history of trauma.

II. CASE PRESENTATION

History:

A Forty-five years old male was presented with pain and swelling in the distal third of his left thigh for one month. The swelling had initially started as a small bump and had gradually increased in size. It was accompanied by mild, pricking pain that had intensified over a period of fifteen days. The patient had also reported difficulty in walking and was unable to squat or sit cross-legged during this time. There was no history of trauma or fever. The patient had been diagnosed with Diabetes mellitus for three years but had not been taking any medication.

Local examination:

On examination, there was an ill-defined swelling of size 15*8*2 centimeters present over the medial aspect of the left distal third thigh above the level of patella, which was having a smooth surface, firm in

consistency and was not fixed to the underlying bone. Skin over the swelling appeared normal. Tenderness and local warmth were observed over the swelling. Range of movement of knee joint was 0-130 degrees. Fundus examination revealed severe non-proliferative diabetic retinopathy.

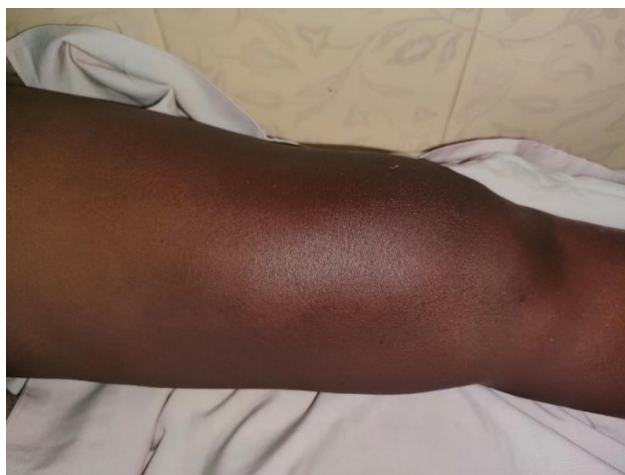

Figure 1 – clinical picture showing ill-defined swelling over the distal and medial aspect of left thigh.

Lab investigations:

His laboratory results showed white cell counts of $11.5 \times 1000/\mu\text{L}$, creatinine level of 1.2mg/dL , urea level of 36mg/dl , HbA1c of 11.0% , ESR (Erythrocyte sedimentation rate) of 5 mm/hour , CRP (C- reactive protein) was negative and random blood sugar was 211mg/dl

Imaging:

USG (Ultrasonography) of left thigh showed diffuse swelling and hyper echogenicity in superficial muscular plane of anterior aspect of left lower thigh suggested possibilities of inflammatory changes-? Myositis. MRI (Magnetic Resonance Imaging) of left thigh showed marked swelling with intramuscular hyperemia and streaks of thin intramuscular hematoma in the vastus medialis and vastus intermedius muscles in lower half of left thigh- likely infectious myositis.

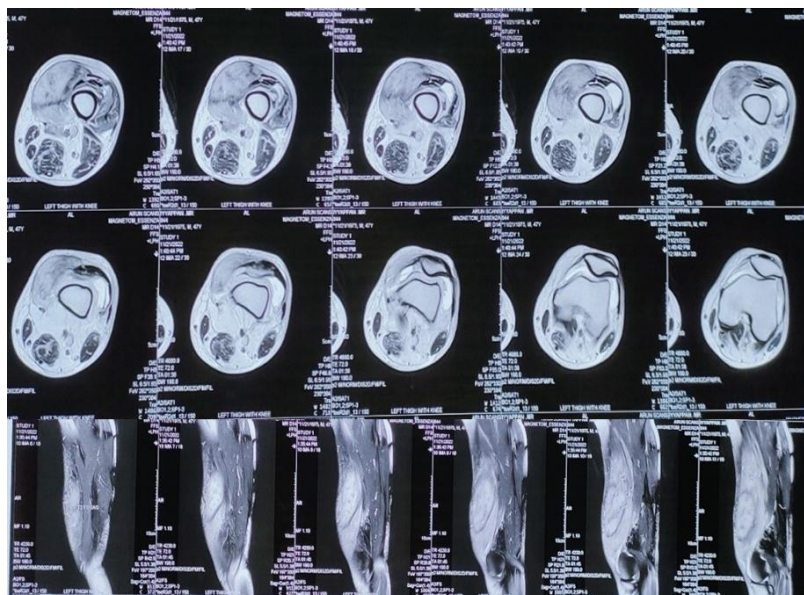


Figure 2 - MRI showing thin intramuscular hematoma in the vastus medialis and vastus intermedius muscles.

Treatment:

Patient underwent Incisional biopsy and tissues were sent for culture and histopathology. Tissue culture showed no growth and histopathology showed extensive necrosis of muscle fibers with fibrinoid necrosis of vessel walls and inflammatory infiltrate suggestive of myositis secondary to Diabetic muscle infarction. Patient was

treated with bed rest, NSAIDs (Non-steroidal anti-inflammatory drugs) and insulin for glycemic control. At 6 months follow up, pain and swelling subsided.

Histopathology:

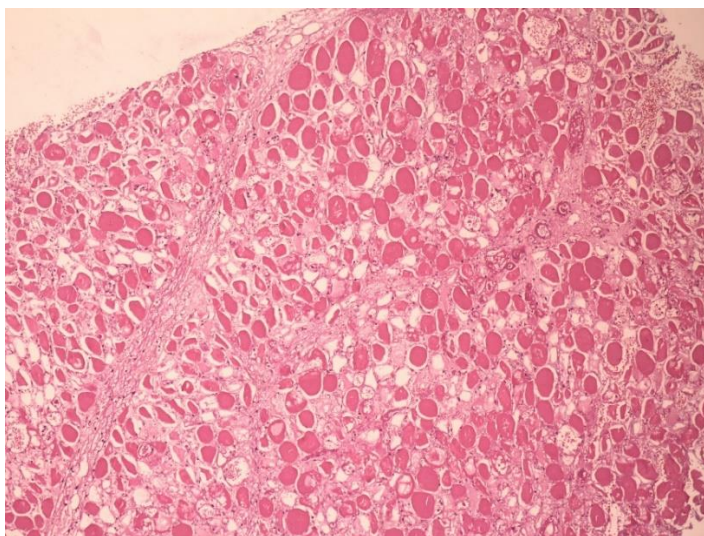


Figure 3 – Histopathology shows extensive coagulative necrosis of skeletal muscle tissue

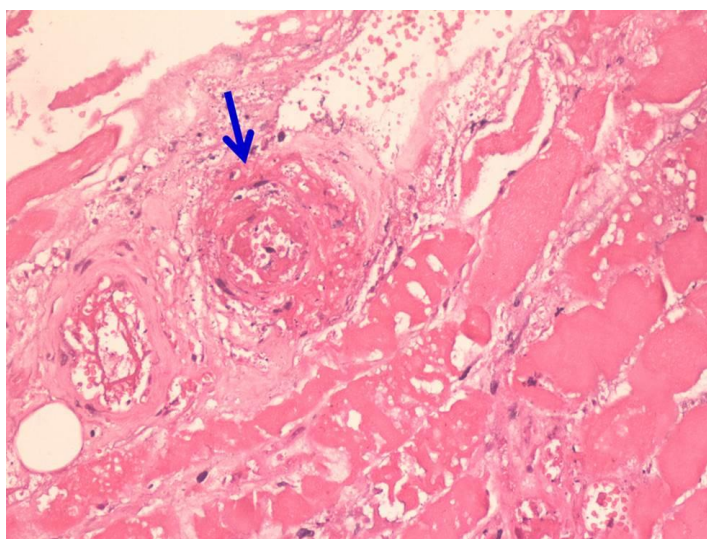


Figure 4 – Histopathology shows Fibrinoid necrosis of vessel wall

III. DISCUSSION

DMI is a rare complication which is usually associated with long-standing poorly controlled diabetes mellitus. Angervall and Stener described this condition in two non-insulin dependent diabetic patients as “tumoriform focal muscular degeneration”. Both patients were suspected to have neoplasm prior to the biopsy. Histopathology revealed no infection or tumor but a central area of hemorrhagic necrosis surrounded by muscle fibers in various stages of degeneration and regeneration, with hyalinosis and thickening of arterioles [1].

The condition is frequent in diabetic women with mean age of 42.63 years at presentation. Patients with DMI also have other diabetic complications, most often, Vascular complications of diabetes in the form of nephropathy, retinopathy, and neuropathy [2].

The pathogenesis of DMI is complex and multifactorial, involving various mechanisms that lead to ischemia and subsequent infarction of the skeletal muscle. Although the exact pathogenic mechanisms are still unclear, atherosclerosis, diabetic microangiopathy, vasculitis with thrombosis, ischemia-reperfusion injury, thromboembolic events secondary to microvascular endothelial damage have all been implicated in the pathophysiology of this condition [3]. Hypercoagulability is another proposed mechanism of DMI pathogenesis. Factor VII activity, plasminogen activator inhibitor and the plasma thrombomodulin level were elevated, the tissue plasminogen activator response to venous occlusion was depressed which can affect the microvasculature

of the skeletal muscle, leading to microthrombi formation and subsequent ischemia and infarction of the muscle tissue [4]. Study by Palmer et al suggested that antiphospholipid antibodies may be involved in the pathogenesis of diabetic muscle infarction [5].

DMI typically presents as an abrupt onset of pain in the affected muscle. The pain can usually be accompanied by local swelling. As the condition progresses, a palpable painful mass may appear in about one-third of cases. DMI most frequently affects the thigh, particularly the quadriceps muscle. Calf involvement and bilateral involvement is less common. Vastus lateralis and the vastus medialis are the muscles most frequently affected [2].

DMI can be detected through laboratory findings that may indicate mild to moderate leukocytosis, minimal increase in Creatine phosphokinase level, and rise in erythrocyte sedimentation rate levels [6]. USG can serve as an initial assessment method for DMI, revealing a well-defined, hypoechoic, intramuscular lesion with features like linear echogenic structures, absence of internal motion or swirling of fluid transducer pressure, and no predominance of anechoic areas [7]. However, the preferred diagnostic modality for DMI is MRI, which helps to rule out the differential diagnosis, such as deep venous thrombosis, pyomyositis, and primary or secondary muscle tumors. MRI displays increased signal from the affected muscle area (intra-muscular and peri muscular tissues) in T2-weighted, inversion-recovery, and gadolinium-enhanced images, and iso-intense or hypointense areas on T1-weighted images. This is due to the increased water content from oedema and inflammatory changes that occur during the infarction process [8].

Muscle biopsy is an effective method for diagnosis, but it is not recommended due to the risk of intra operative complications and delay in symptom improvement [9]. Biopsy should only be done if the clinical presentation is unusual or if standard treatment does not lead to improvement [10]. But in our case, as we suspected Infective myositis, biopsy was done. Before our pathologist brought it to our attention, we orthopaedic doctors were unaware that a condition known as diabetic muscle infarction existed.

The optimal treatment plan for DMI is unknown due to limited studies. Bed rest, glycemic control, and NSAIDs (Non-steroidal anti-inflammatory drugs) therapy are preferred treatment. Surgery and physical therapy should be avoided during the acute phase as it may prolong the recovery time [10]. Recurrences in the same or opposite limb are common.

IV. CONCLUSION

Diabetic muscle infarction is a rare complication seen in long-standing poorly controlled diabetes mellitus. It usually presents as a swelling associated with pain in the affected region. Most common site being the quadriceps muscle. MRI is the preferred diagnostic modality. Treatment involves bed rest, glycemic control and NSAID therapy.

REFERENCES

- [1]. Angervall L, Stener B. Tumoriform focal muscular degeneration in two diabetic patients. *Diabetologia*. 1965 Aug 1;1(1):39–42.
- [2]. Trujillo-Santos AJ. Diabetic muscle infarction: an underdiagnosed complication of long-standing diabetes. *Diabetes Care*. 2003 Jan;26(1):211–5.
- [3]. Hoyt JR, Wittich CM. Diabetic Myonecrosis. *J Clin Endocrinol Metab*. 2008 Oct 1;93(10):3690.
- [4]. Bjornskov EK, Carry MR, Katz FH, Lefkowitz J, Ringel SP. Diabetic muscle infarction: a new perspective on pathogenesis and management. *Neuromuscul Disord NMD*. 1995 Jan;5(1):39–45.
- [5]. Palmer GW, Greco TP. Diabetic thigh muscle infarction in association with antiphospholipid antibodies. *Semin Arthritis Rheum*. 2001 Feb 1;30(4):272–80.
- [6]. Naderi ASA, Farsian FN, Palmer BF. Diabetic muscle necrosis. *J Diabetes Complications*. 2008;22(2):150–2.
- [7]. Hinton A, Heinrich SD, Craver R. Idiopathic diabetic muscular infarction: the role of ultrasound, CT, MRI, and biopsy. *Orthopedics*. 1993 May;16(5):623–5.
- [8]. Goswami P, Baruah MP. The Role of MRI in Diagnosis of Diabetic Muscle Infarction : an Underdiagnosed Entity. *Int J Endocrinol Metab*. 2012 Jan 8;9(2):353–5.
- [9]. Morcuende JA, Dobbs MB, Crawford H, Buckwalter JA. Diabetic muscle infarction. *Iowa Orthop J*. 2000;20:65–74.
- [10]. Horton WB, Taylor JS, Ragland TJ, Subauste AR. Diabetic muscle infarction: a systematic review. *BMJ Open Diabetes Res Care*. 2015;3(1):: e000082.