

# A Simple Approach For Treatment Of Maxillary Diastema Closure Using A Clear Retainer – A Case Report

Dr. Toiaibha Syngkon<sup>1</sup>, Dr. Nabanita Baruah<sup>2</sup>, Dr. Arpita Kashyap<sup>3</sup>

<sup>1</sup>(Post graduate student, Department of Orthodontics and Dentofacial Orthopaedics/Regional Dental College/Srimanta Sankaradeva University of Health Science, India)

<sup>2</sup>( Professor & Head of Department , Department of Orthodontics and Dentofacial Orthopaedics/Regional Dental College/Srimanta Sankaradeva University of Health Science, India )

<sup>3</sup>(Reader, Department of Orthodontics and Dentofacial Orthopaedics/Regional Dental College/Srimanta Sankaradeva University of Health Science, India)

**Abstract:** Maxillary midline diastema is one of the most common orthodontic problems particularly a relapsed midline diastema requiring treatment mainly for esthetic reasons. This case presentation shows two cases whose chief complaint was a gap between the maxillary front teeth a few months post fixed orthodontic treatment. On examination the patients had symmetric face with competent lips with class 1 molar and canine relationship with a normal overjet and overbite. For the closure of this relapsed midline diastema, a clear Essix retainer was fabricated and made into two halves. A composite button was made on the vestibular surface of both the maxillary canines as attachments for elastics wear. After the midline diastema was favourably closed, a 3-3 bonded lingual retainer along with a clear Essix retainer for permanent retention was given. Therefore, this appliance was found to be sufficient to close a midline diastema varying from 1 mm to less than 3 mm for a short period of time for the patient's esthetic outcome.

**Key Word:** Maxillary midline diastema, Clear Essix retainer, Elastics.

Date of Submission: 17-07-2023

Date of Acceptance: 27-07-2023

## I. Introduction

Angle (1907) described dental midline diastema as a rather common form of incomplete occlusion characterized by space between the maxillary and less frequent in the mandibular central incisors. According to his functional and esthetic implication of midline diastema, he stated that "the midline diastema always creates an unpleasant appearance and interferes with speech according to its width"[1]

Maxillary midline diastema is defined as a space or gap in between two maxillary central incisors[2] which can compromise a person's smile attractiveness and facial disharmony[3]. The general treatment of midline diastema is usually due to esthetic and psychological purpose rather than functional reasons[4]. Midline diastema is one of the common reasons why people seek orthodontic treatment. Although this treatment is comparatively easy, but if retention protocols are not followed then relapse changes can highly occur. Midline diastema often requires fixed retainer post treatment.

When comprehensive orthodontic care is not the patient's choice of treatment and if function and alignment of the teeth are acceptable, clinicians can perform restorative or simple orthodontic treatment successfully.

This case report shows the simple treatment of relapsed midline diastema using thermoplastic clear retainer and intraoral elastics for closing the diastema.

## II. Case Report

### Case 1

A 22 year old female patient came with a chief complaint of space in between her upper front teeth eight months after debonding of fixed orthodontic treatment (Figure 1). On clinical examination, a 1mm midline diastema was seen in between the maxillary central incisors on measurement with a digital caliper. Treatment options were given for the closure of midline diastema including restoration composites, laminates and veneers. The patient opted for an esthetic but a more permanent treatment and was then advised a vacuum formed retainer and elastics to close the space of which the patient has agreed.

The tray was trimmed in the vestibular and lingual surfaces of the teeth, avoiding the gingival margins. The vacuum formed retainer was sectioned into two halves in between the maxillary central incisors to create a

separate right and a left tray. Composite buttons was made on the labial surface of both sides of the maxillary canine . These composite button were shaped and cured on the cast itself (Figure 2).

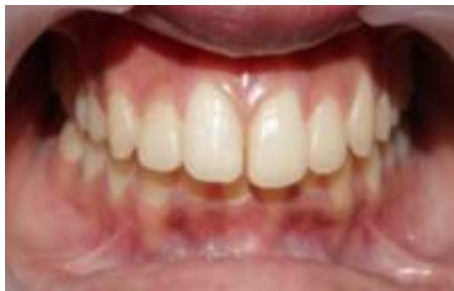An elastic (1/4<sup>th</sup> or 4.5oz) was connected from one composite button to the other on the vestibular surface of the maxillary canine, where the elastics were made to change after every 24hours (Figure 3 and figure 4). The patient was instructed to wear the appliance with the elastic full time except during meals.

On review after one week, the 1mm space was seen to be closed (Figure 5). The patient was advised to continue wearing the appliance along with the elastic for another one week.

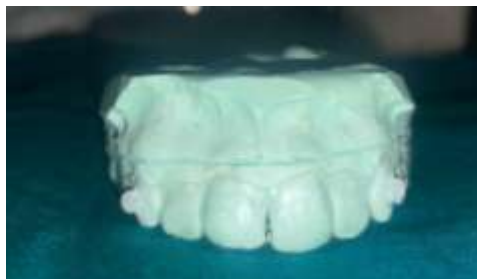The diastema was closed completely after a period of two weeks with coincident dental and facial midlines, Class 1 molar and canine relationship and overbite and overjet was maintained (Figure 6).

After the period of diastema closure, a fixed lingual retainer from maxillary canine to canine was given and along with it an clear essix retainer for retention (Figure 7).

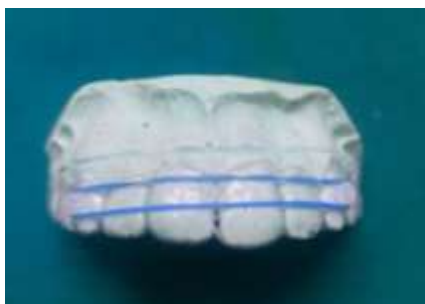For this particular case, a total treatment period was two weeks. The final Impressions were made and intraoral photographs were taken, the patient displayed closed diastema with well maintained dental relationship which shows an attractive and pleasing smile.



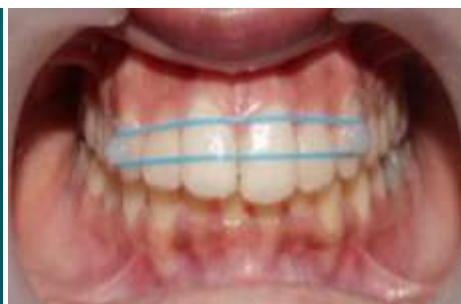**Figure 1: Pre-treatment Intraoral Photograph showing midline diastema**



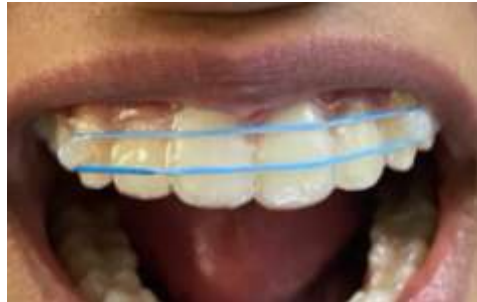**Figure 2: Clear retainer with fabricated composite buttons**



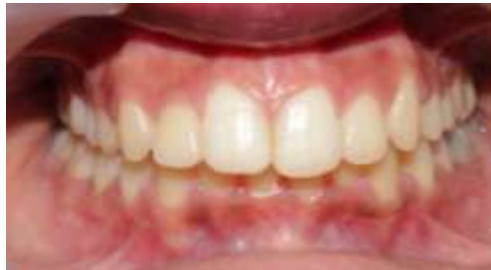**Figure 3 and**



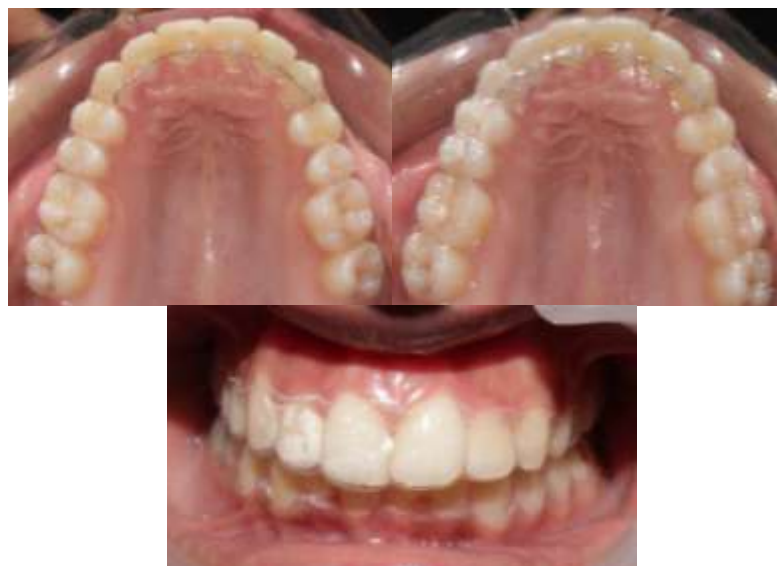**Figure 4: Clear Retainer with elastics**



**Figure 5: After 1 week of treatment**



**Figure 6: After 2 weeks of treatment**



**Figure 7: Post-treatment with lingual bonded fixed retainer and clear retainer**

**Case 2:**

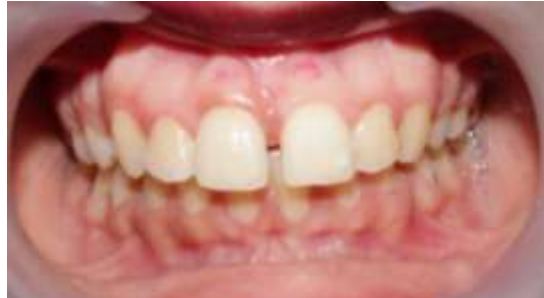A 24 year old female patient reported with a chief complaint of spacing in between her upper front teeth after nine months after debonding of the fixed orthodontic treatment (Figure 8). On examination, a diameter of 2.6mm was observed between the maxillary central incisors on measurement with a digital caliper. Treatment options was given accordingly. Fixed Orthodontic treatment was given as one of the permanent treatment for closure of the relapsed midline diastema since it is diastema of more than 2mm. But the patient denied retreatment using fixed orthodontic therapy and wants a faster and more convenient treatment option besides restorative treatment. An option which is more permanent was advised which includes a vacuum formed retainer and elastics to close the space where the patient opted for.

The treatment progress includes almost similar steps as the above case. The vacuum formed retainer was sectioned into two halves in between the two maxillary central incisors creating a left and right tray. Composite buttons were shaped and cured on the cast. A medium to light 3.5 oz elastics was started with by connecting from one composite button to another on the vestibular surface of the maxillary canine (Figure 9 and 10). Elastics were made to change after every 24 hours. Patient is instructed to wear the appliance full time except during meals.

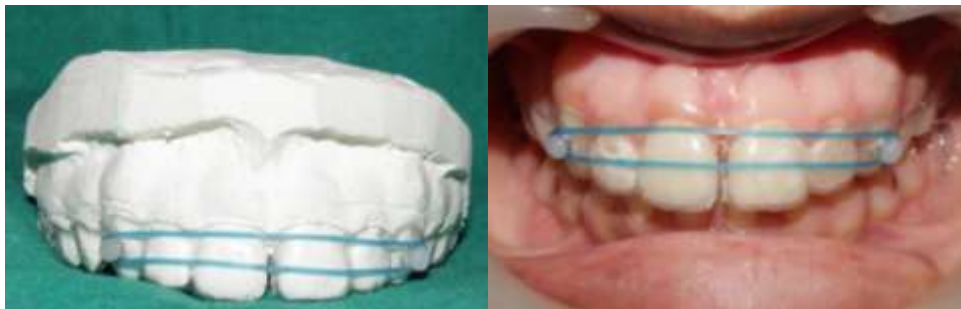
After a week of review, the space was seen to be minimized to 1.7mm (Figure 11). Then patient was reviewed again after a period of ten days, the space was seen to be minimized to 0.5mm (Figure 12). The patient was then made to switch to a heavier elastics of 4.5oz , and after a review of about seven days the space was seen to be closed. Patient was advised to continue with the appliance for another five days (Figure 13).

The midline diastema of 3mm was seen to be completely closed after a period of 29 days with coincident dental and facial midlines and class I molar relationship was maintained.

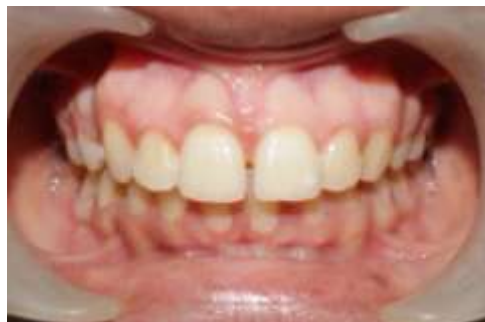A fixed lingual retainer from maxillary canine to maxillary canine was given along with a clear Essix retainer for retention (Figure14).



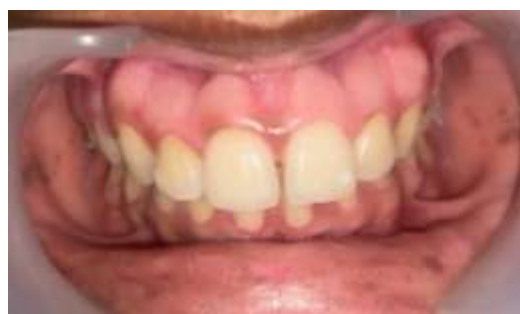**Figure8: Pre-treatment photograph**



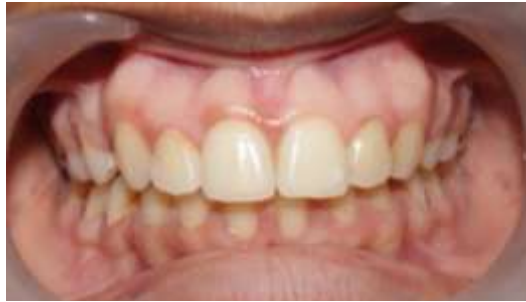**Figure 9 and 10:Clear retainer fabricated with composite buttons and elastics**



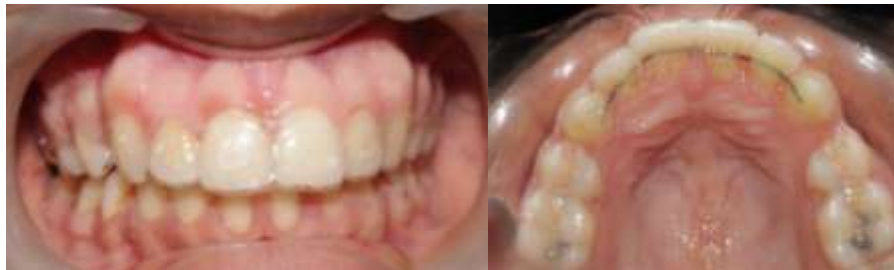**Figure 11: After 7 days of treatment**



**Figure 12: After 17 days of treatment**



**Figure 13: After 24 days of treatment**



**Figure 14: Post-treatment with lingual bonded fixed retainer and clear retainer**

### **III. DISCUSSION**

Midline diastema is presently one of the major esthetic concern of patients. It is one of the main reasons for people seeking orthodontic treatment. High aberrant frenal attachment is one of the major etiological aspects that can result in anterior midline diastema. Diastema cases with 'abnormal' frenum demonstrated a stronger potential for relapse after orthodontic treatment[5]. There are various techniques employed for the management of maxillary anterior space closure.

Small spaces can be closed using removable appliances. Midline diastemas of less than 2 mm can be treated by mesial tipping of the teeth together. But diastemas of more than 2mm may require bodily movement of the teeth and can be of major esthetic concern that might require fixed orthodontic treatment[6].

Midline diastema is also one of the most common post-orthodontic treatment problems. There are many techniques available in the literature for the treatment of small midline diastema which includes a single sitting space closure such as brass wire[7], elastomeric separators[8]and composites and veneers. Although numerous methods have been used for the correction of relapsed midline diastema, there are a few easy, time saving and cost-effective methods.

The patients in these cases did not want fixed orthodontic treatment or restorative treatment for the closure of relapsed midline diastema. Hence, an esthetic removable clear retainer was used. This appliance is comfortable, undetectable, and full patient compliance was achieved.

The removable appliance will close the anterior midline diastema by tipping of the crown of anterior teeth. They do not have any vertical control or torque control, which may have a tendency on relapse, so measures must be taken to avoid relapse[9]. For this case, a bonded 3-3 upper lingual retainer was placed and along with it, a clear essix retainer from upper 7-7 was given for retention and stability. Direct bonded retainer provides excellent patient acceptance and the failure rate was low[10].

The appliance presented in the case report was seen to be sufficient to close a small midline diastema within a span of 1 week for a space of 1mm and 29 days for a space of less than 3mm not causing any deleterious tooth movement. The appliance is easy to fabricate, convenient and time saving. The esthetic problem was resolved using the clear appliance sufficient to close a maxillary midline diastema [11]. When a patient is not interested in the fixed orthodontic treatment or any other adjunctive treatment, clear Essix retainer is a better alternative option for the management of minor midline diastema.

### **IV. Conclusion**

Relapsed maxillary midline diastema is one of the most common post orthodontic problem. Most of the patients do not want to opt for fixed orthodontic treatment again and also want the midline diastema to be closed in a short period of time. With this appliance a relapsed diastema can be resolved within a short period of time particularly in patients who refuse fixed orthodontic treatment. The appliance is easy to fabricate, esthetically pleasing and comfortable with a good patient compliance.

Thus the Clear Essix retainer with elastics can used effectively as a simple treatment option for the closure of a midline diastema.

### References

- [1]. Angle EH. In: Angle. Treatment Of Malocclusion Of The Teeth, 7th Edition. Philadelphia: S.S. White Dental Manufacturing Co.1907:167
- [2]. Huang WJ, Creath CJ. The Midline Diastema: A Review Of Its Etiology And Treatment. *Pediatr Dent* 1995; 17: 171-9.
- [3]. Furuse AY, Franco EJ, Mondelli J. Esthetic And Functional Restoration For An Anterior Open Occlusal Relationship With Multiple Diastemata: A Multidisciplinary Approach. *J Prosthet Dent* 2008; 99: 91-4
- [4]. Gkantidis N, Kolokitha OE, Topouzelis N. Management Of Maxillary Midline Diastema With Emphasis On Etiology. *J Clin Pediatr Dent* 2008; 32 :265-72
- [5]. Edwards JG. The Diastema, The Frenum, The Frenectomy: A Clinical Study. *Am J Orthod.* 1977 May;71(5):489-508.
- [6]. Proffit WR, Fields HW, Sarver DM. *Contemporary Orthodontics*. Elsevier Publications Sixth Edition, 2019.
- [7]. Tanaka OM, Clabaugh R 3<sup>rd</sup>, Sotiropoulos GG. Management Of A Relapsed Midline Diastema In One Visit. *J Clin Orthod*2012;46:570-1
- [8]. Kshetrapal A. Correction Of Relapsed Midline Diastema. *J Indian Orthod Soc* 2019;53:90-1
- [9]. Shashua D, ÅRtunJ. Relapse After Orthodontic Correction Of Maxillary Median Diastema: A Follow-Up Evaluation Of Consecutive Cases. *Angle Orthodontist* 1999; 69: 257-63
- [10]. Zachrisson BU. Clinical Experience With Direct-Bonded Orthodontic Retainers. *American Journal Of Orthodontics.* 1977 Apr 1;71(4):440-8.
- [11]. Şin, S., Beycan, K., &Ay, Y. Treatment Of Maxillary Midline Diastema Using Removable Clear Trays And Elastics: A Case Report. *Meandros Medical And Dental Journal.*2017.218,68-71