

Awake Brain Surgery While Patient Watches His Favourite Politician Video Of Sri YS Jagan Mohan Reddy Takes Oath As Andhra Pradesh Chief Minister - A Novel Political Cinematherapy.

Dr. Bhavanam Hanuma Srinivas¹, Dr. Bommisetty Trinath kumar², Dr. Akash³

¹Cosulatant Neurosurgeon, ex assistant professor, ²consultant anaesthetist, Assistant professors, ³Senior resident,

¹Department of Neurosurgery, Sri Sai Hospitals, Brinda Neuro Centre, Guntur, ex assistant professor in Guntur medical college, ²Department of anaesthesia ³, senior resident Sri Sai Hospitals, Brinda Neuro Centre, Guntur..

Abstract:

Awake brain surgery or awake craniotomy, is a type of surgical procedure performed on the brain while patient is awake and alert. Awake craniotomy is routinely used to treat some brain tumors which are located in functional areas or epileptic seizures. Here in we are reporting a case of right frontal glioma abutting right motor area in a 43 yr old male presenting with severe headache and recurrent seizures. He underwent awake brain surgery and gross total excision of tumor by using Intra operative Neuro navigation. The patient was very nervous, so to distract him while performing awake surgery as per his wish we played his favourite politician programme of Chief minister of Andhrapradesh 2019 Oath ceremony by ys Jagan mohan reddy and his favourite cinema star superstar Krishna movie Agniparvatam in a sterilised laptop. The surgery got over in two hours. To the best of our knowledge this is a more unique way of stress relief for the patient, as surgery performed successfully by using of political and cinema concept we named it as novel political cinema therapy.

Key words: Awake craniotomy, cinema, political,.

Date of Submission: 20-07-2023

Date of Acceptance: 30-07-2023

I. Introduction

Awake craniotomy is a very versatile and unique procedure in Neurosurgery initially introduced for surgical treatment of epilepsy, and has subsequently been used in patients with supratentorial tumors, vascular lesions, deep brain stimulation near critical regions of brain^{1,2,3}. During awake craniotomies, patients active participation is very crucial to facilitate the surgeon's intra operative decisions. Awake craniotomy offers the unique possibility of reducing postoperative morbidity, facilitating early discharge from the hospital. The primary aim of the neurosurgeon and his team is to make the operation safe and effective by reducing the psychophysical distress of the patient and morbidity. Previously we used to do awake surgery by playing music, later we used to play patients favourite movies like Bahubali, Suryavamsam, Bigboss shows while doing awake brain surgeries where we noticed patients are more comfortable, active and cooperating well. This time during pre surgery counselling sessions, we noticed that patient is more happy whenever political concept came rather than cinemas, which makes a thought of combining both political programme along with his favourite cinema. The planning of intra operative distraction of patient can be done effectively by playing his favourite politician video who is the present chief minister of Andhrapradesh along with old classic, blockbuster movie Agniparvatam. Here in we report a case of Right frontal glioma abutting premotor and motor area presenting with severe headache and recurrent seizures.

II. Case report:

A 43 yr old male admitted in our hospital under state govt sponsored health scheme (YSR Arogya Sri) with complaints of recurrent complex partial seizures for past 7 years.. On examination showed GCS 15/15 Neurological examination revealed no motor/ sensory deficits with MMSE 24/30. Cranial nerve examination normal. Family history is nil relevant.. MRI brain done (Fig 1) which showed 3.2 x 1.8 cm lesion present at right frontal region abutting premotor and motor area at parasagittal region.. In view of tumor extension into pre motor and abutting motor area, we planned for awake craniotomy. Thorough pre op evaluation done with proper pre op counselling by team of doctors includes neurosurgeon, neurosurgery resident, anaesthetist. During pre op counselling we noticed his apprehension for that we showed our previous operated patients

videos who is watching Bahubali, Bigboss etc.. i.e different options for distraction, he told he was fan of superstar Krishna, patient shown willing to see Krishna's old classic hit movie Agniparvatam which he watched that movie 20 times before. Routinely our surgical team will do multiple sittings of pre op counselling during that time we noticed he was tension free and more relaxed whenever the name of YS Jagan Mohan reddy & Late YSR name pronounced (as he was admitted under state govt sponsored YSR Aarogyasri scheme free health for poor people). So we given option to watch his favourite politician video clips along with Agniparvatam movie. In view of intra op requirement of Neuro navigation machine we did surgery in another hospital where this facility available locally. Intraoperatively scalp block given by senior anaesthetist by using 0.25% bupivacaine. After scalp block we used Mayfield for head fixation. Patient was positioned in a comfortable position. Navigation registration process done. After positioning, we started playing of Agniparvatam movie in a well sterilised laptop. while doing awake brain surgery as per patient wish, in a laptop we showed his favourite Agniparvatam movie initial and ending stages of surgery, at the time of tumor removal he watched his favourite politician video (TV 9 News) clip of YS Jagan Mohan Reddy takes Oath as Chief Minister of Andhrapradesh in 2019. He underwent right fronto-parietal craniotomy centered on tumor. After craniotomy ropivacaine soaked cotton gauge applied over dura for 5 min. After durotomy, by using navigation (figure 2,3) perfect localisation of tumor done and intraop movements of upper limbs and lower limbs tested while excising the tumor. Gross total excision of tumor was done. patient was quite comfortable through out the procedure, in fact he was more happy and chating regarding his favourite politician struggles to success story as become CM of Andhrapradesh (Figure 3). Throughout the procedure patient was managed by senior anaesthetist team and with the consent of patient we did video recording also. Post op patient had no fresh deficits and had seizure free in the 8 months follow up period.

III. Discussion

The first applications of awake craniotomy can be traced to remote antiquity, where practitioners performed trepanations of the skull to release demons and treat a variety of conditions, including seizures, contusions and fractures⁴. It is from these humble beginnings that this technique evolved to become a robust neurosurgical tool in the management of a variety of diseases affecting the CNS. The first contemporary use of awake craniotomy was for epilepsy surgery under local anaesthesia⁵. The expansion of the technique to other domains, namely neuro-oncology, is partially a result of improvements in anesthetic agents and patient-monitoring equipment, as well as enhancements in intraoperative functional mapping technology.

The main advantage of awake craniotomy is to allow for intraoperative electrocorticography and cortical mapping to identify eloquent brain areas, thereby decreasing postoperative neurological morbidity. The primary cortical regions of interest, which will be subsequently discussed, are those controlling motor and language function. A secondary advantage that has been proposed is the ability to perform more aggressive tumor resections. Furthermore, recent emphasis has been placed on innovative application of awake craniotomy to tumors that lie beyond the eloquent cortex to facilitate early patient discharge, and allow the conduct of brain tumor surgery in low-resource settings.

The success of awake brain surgery depends on several factors:

- 1) Appropriate patient selection
- 2) Preoperative psychological preparation
- 3) Rapport building between patient and surgical and anesthesia team.
- 4) Comfort in patient positioning
- 5) Appropriate scalp nerve block
- 6) Anesthetic technique selection
- 7) Appropriate intraoperative monitoring.
- 8) Continuous team communication.

Pre operative psychological preparation: This plays very crucial rule in the success of this awake craniotomy. Operating neurosurgeon as well as anaesthetist must gain the patient's confidence, as the patient will depend on him during the procedure. Prior to surgery, the patient must be informed about realistic description of the operating room, expected discomforts and level of co-operation expected, potential risks, safety measures and stages of the procedure. The patient must understand that these discomforts are essential for the success of the procedure. A visit to the operating room before surgery in order to familiarize the patient with the sounds and equipment in the rooms is a good idea. The patient should be explained the tasks that will be performed for speech and motor testing. Questions should be encouraged and if possible speaking to a prior patient who has undergone this procedure successfully in the past can be invaluable. During detailed preop counselling session we showed our previous awake brain surgery video clips where we did it by playing old classic songs in a cell phone, showing Bahubali, Suryavamsam, Bigboss show etc. in the sterilised laptop.. At that time he himself asked us to show his favourite politician YS Jagan Mohan Reddy, YSR video clips and his

all time favourite movie Agniparvatam. He previously watched that movie 20 times before still he want to watch that one only. .

Premedication: with sedatives and anticholinergic in patients is quite controversial, and decisions should be made based on the patient's clinical condition and the anesthetic technique. Midazolam and clonidine are among the most efficacious agents. Antiemetic prophylaxis is desirable as a preventive measure. Low dose propofol administration is useful to prevent perioperative nausea and vomiting.⁶ The majority of antiemetics used were metoclopramide (10 mg)^{7,8}, ondansetron (4-8 mg), droperidol (0.625-2.5 mg) and dexamethasone (4-16 mg).^{9,10,11,12,13}

Scalp block: is quite indispensable for an awake craniotomy. The branches of cranial nerves blocked are supratrochlear, supraorbital, auriculotemporal, greater and lesser occipital, great auricular, zygomatic and infraorbital nerves. Local anesthetic (40-60 mL) with epinephrine assures long duration of block. Large volume of local anesthetic and well-vascularized areas predispose to anesthetic toxicity hence individual nerve blocks are preferred over wide areas of infiltration to decrease probability of local anaesthesia toxicity. The use of adrenaline (5 µg/mL, 1:200 000 dilution) both minimizes acute rise in plasma concentration and maximizes the duration of the block. Bupivacaine is the most commonly used local anesthetic but ropivacaine and levobupivacaine appear to be safer than bupivacaine. Our anaesthetist used the bupivacaine 0.25% for scalp block.

Monitored Anaesthesia care: According to the American Society of Anesthesiologists, monitored anesthesia care is a specific anesthetic protocol that includes careful monitoring and support of vital functions. The ASA recommends that the provider of MAC be qualified and prepared to convert to general anesthesia if necessary.¹⁴ Propofol is widely employed for awake craniotomy because of its easily titratable sedative effect and rapid recovery with clear-headedness. Propofol decreases cerebral oxygen consumption, reduces intracranial pressure, and has potent anti-convulsant properties. Propofol also has antiemetic properties and may be administered using a target controlled infusion (TCI) technique Normally, propofol infusion for TIVA is set to 100-200 mcg/kg/min; this does not appear to interfere with electrocorticography (ECoG) if infusion is stopped 15 min before recording according to Herrick and 20 min in pediatric settings. Some employ propofol sedation only in combination with local anesthesia and without opioids infusion and are able to achieve good pain control.

Dexmedetomidine is a highly selective α_2 -agonist with dose-dependent sedative, anxiolytic, and analgesic effects without ventilation suppression.¹⁶ Dexmedetomidine has been used to treat discomfort in patients sedated with a propofol and remifentanyl combination. Generally, a dexmedetomidine load of 0.5 to 1 µg/kg/h over 20 min is followed by infusion at rates of 0.1 to 0.7 µg/kg/h to 20 min prior to testing. During cortical mapping the infusion rate is usually set to 0.1 to 0.2 µg/kg/h. In our case our anaesthetist used Dexmedetomidine which given good result for patient.

Intraoperative monitoring: It typically includes electrocardiogram, invasive and non-invasive blood pressure measurements, pulse oximetry, respiratory rate, capnography, and temperature. If large blood losses are expected, a large bore IV and or a central venous catheter are inserted. Intra-operatively, the respiratory rate and end-tidal carbon dioxide are measured by means of nasal prongs-port with capnometry. Urinary catheter may or may not be inserted. In our case we not introduced urinary catheter. During surgery we used Neuronavigation for perfect localisation of tumor site. In our setup we don't have cortical mapping. So while removing tumor we intermittently checking upper limb and lowerlimb movements. At the time of tumor removal while watching CM Jagan's Oath ceremony he himself expressing his happiness by way of nice talks and commands with surgical team.

During surgery, to distract him we played not only his favourite politician video clips abut also his all time favourite movie, Agniparvatam. The surgery got over in two hours. Now we can able to tell the introduction of political and cinema concepts into awake brain surgeries will definitely give benefit to therapy, so named as Political Cinematherapy.

IV. Conclusions

The success of awake craniotomy based on patient cooperation, technology and technical skill of operative team. Among them psychological support of patient had utmost importance. Politics, cinemas and sports had always association and great impact on the medical field. In awake brain surgeries addition of any of these 3 amusements like showing favourite politician video clips, movies, sports, etc may definitely gives unimaginary advantage to scientific results.

References

- [1]. Burchiel KJ, Clarke H, Ojemann GA, Dacey RG, Winn HR. Use Of Stimulation Mapping And Corticography In The Excision Of Arteriovenous Malformations In Sensorimotor And Language-Related Neocortex. *Neurosurgery*. 1989;24:322–7.
- [2]. Duffau H, Capelle L, Sichez JP, Faillot T, Abdennour L, Law Koune JD, Et Al. Intra-Operative Direct Stimulations Of The Central Nervous System: The Salprière Experience With 60 Patients. *Acta Neurochir (Wien)* 1999;141:1157–67.
- [3]. Lüders JC, Steinmetz MP, Mayberg MR. Awake Craniotomy For Microsurgical Obliteration Of Mycotic Aneurysms: Technical Report Of Three Cases. *Neurosurgery*. 2005;56(1 Suppl):E201.
- [4]. July J, Manninen P, Lai J, Et Al. The History Of Awake Craniotomy For Brain Tumor And Its Spread Into Asia. *Surg. Neurol.* 2009;71(5):621–624. Discussion 624–625. A History Of The Use Of Awake Craniotomy.
- [5]. Penfield W. *No Man Alone. A Neurosurgeon's Life.* Little Brown, MA, USA: 1977.
- [6]. Tramèr M, Moore A, Mcquay H. Propofol Anesthesia And Postoperative Nausea And Vomiting Quantitative Systematic Review Of Randomized Controlled Studies. *Br J Anaesth.* 1997;78:847–55.
- [7]. Keifer JC, Dentchev D, Little K, Warner DS, Friedman AH, Borel CO. A Retrospective Analysis Of A Remifentanyl/Propofol General Anesthetic For Craniotomy Before Awake Function- Al Brain Mapping. *Anesth Analg.* 2005;101:502–8.
- [8]. Tobias JD, Jimenez DF. Anaesthetic Management During Awake Craniotomy In A 12-Year-Old Boy. *Paediatr Anaesth.* 1997;7:341–4.
- [9]. Herrick IA, Craen RA, Mclacklan RS, Girvin JP, Parrent AG, Eliasziw M, Et Al. Propofol Sedation During Awake Craniotomy For Seizures: Patient Controlled Administration Versus Neurolept Analgesia. *Anesth Analg.* 1997;84:1285–91.
- [10]. Sarang A, Dinsmore J. Anesthesia For Awake Craniotomy Evolution Of A Technique That Facilitates Awake Neurological Testing. *Br J Anaesth.* 2003;90:161–5.
- [11]. Tijero T, Ingelmo I, García-Trapero J, Puig A. Usefulness Of Monitoring Brain Tissue Oxygen Pressure During Awake Craniotomy For Tumor Resection. *J Neurosurg Anesthesiol.* 2002;14:149–52.
- [12]. Whittle IR, Midgley S, Georges H, Pringle AM, Taylor R. Patient Perceptions Of Awake Brain Tumour Surgery. *Acta Neurochir (Wien)* 2005;147:275–7.
- [13]. Schulz U, Keh D, Fritz G, Barner C, Kerner T, Schneider GH, Et Al. Schlaf-Wach-Schlaf Technik Zur Wachkraniotomie. *Anaesthetist.* 2006;55:585–98.
- [14]. American Society Of Anesthesiology House Of Delegates. Position On Monitored Anesthesia Care. *ASA Standards, Guidelines And Statements.* 2005.
- [15]. Hans P, Bonhomme V. Why We Still Use Intravenous Drugs As The Basic Regimen For Neurosurgical Anesthesia. *Curr Opin Anaesthesiol.* 2006;19:498–503.

Figure 1. MRI

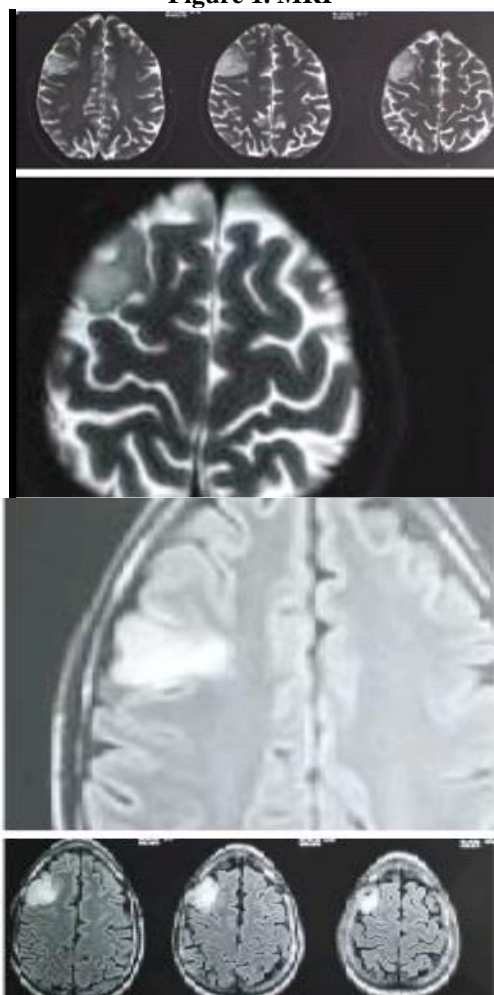


Figure 2:

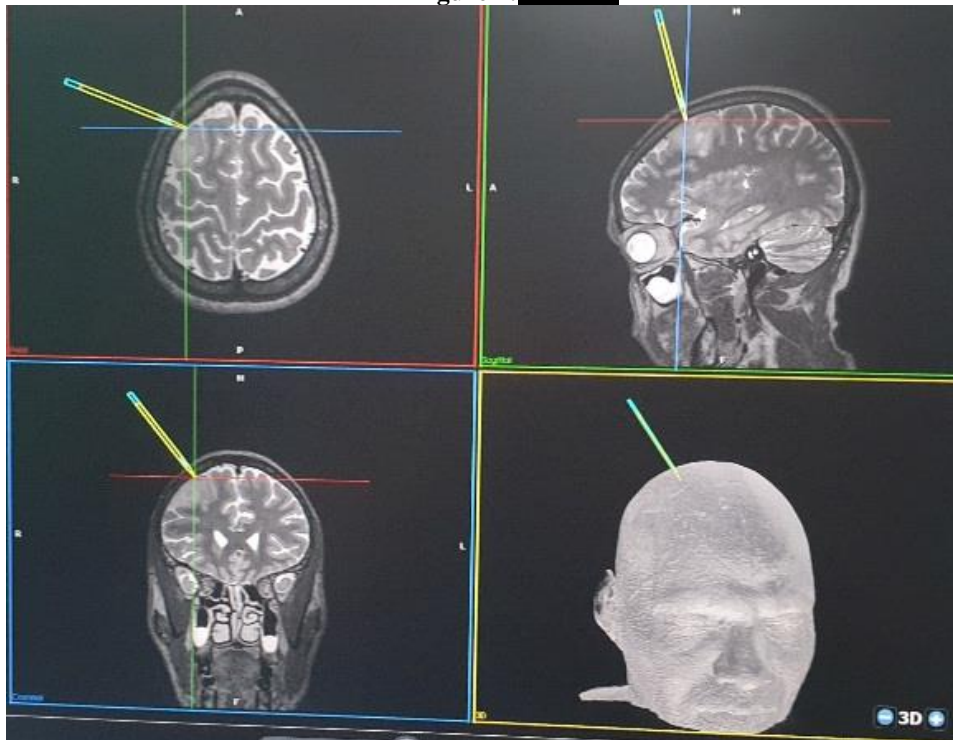


Figure3:

