

# Evaluation Of Computer Guided Zygomatic Implant Placement Stability Using Customized Guided Drill Keys In Severely Atrophic Maxilla (Clinical Case Series Study)

Hagar Ahmed Hussein<sup>1\*</sup>, Mohamed El-Khashab<sup>2</sup>, Tarek El-Faramawi<sup>1</sup>,  
Nadia Galal<sup>1</sup>

<sup>1</sup> Oral and Maxillofacial Surgery Department, Faculty of Dentistry, Cairo University, Cairo, Egypt  
<sup>2</sup> Prosthodontics Department, Faculty of Dentistry, Cairo University, Cairo, Egypt

---

## Abstract:

**Background:** Rehabilitation with dental implants improves the quality of life of edentulous patients. The aim of this work was to evaluate the stability of computer-guided zygomatic implant placement associated with customized guided drill keys

**Materials and Methods:** This study was carried out on 6 edentulous patients with severely atrophic upper arch were included. Each patient received 2 conventional implants in the anterior maxilla and 2 zygomatic implants on either side in the zygomatic bone. The zygomatic implants were all surgically drilled using a computer-guided approach and computer-guided stent. Clinical and radiographic follow-up was conducted for each patient.

**Results:** The success rate of zygomatic implants was 100% for Zygomatic implants and conventional implants. The mean  $\pm$  standard deviation values of zygomatic implant stability were  $67 \pm 4.00$  with a minimum of 61 and a maximum of 71 mm.

**Key Word:** Zygomatic implant, Guided surgery, Computer aided implantology.

---

Date of Submission: 06-08-2023

Date of Acceptance: 16-08-2023

---

## I. Introduction

The goal of modern dentistry is to restore patients' oral health in a predictable manner. With a traditional prosthesis, the partially or completely edentulous patient may be unable to regain normal function, aesthetics, comfort, or speech<sup>[1]</sup>.

Osseo integrated dental implants have been developed to restore the edentulous atrophic maxilla. Because of its form and structure, the maxilla is a challenging arch to reconstruct with Osseo integrated dental implants. As a result, numerous various methods of treating atrophic maxilla have been described. incorporating the use of zygomatic implants, short wide implants, implants in the pterygoid apophysis, grafting the floor of the maxillary sinus, and tilting implants in the Para sinus region<sup>[2]</sup>.

The reconstruction of missing teeth in the posterior area of the jaw has always been affected by limited bone availability and insufficient bone quality and may require additional surgical intervention to augment bone levels<sup>[3]</sup>.

Various graft-less solutions have been reported to improve patient acceptability and comfort, including tilted implants in the para-sinus region, implants in the pterygoid process, and short and wide implants. Zygomatic implants are an alternative to bone grafting in the atrophic maxilla<sup>[3]</sup>.

In addition to placing zygomatic implants in the maxilla's molar and premolar areas, placing two to four conventional dental implants in the anterior maxilla enables the creation and stabilization of cross arch bars. It gives a fixed hybrid implant supported prosthesis mechanical stability and retention<sup>[4]</sup>.

The aim of this work was to evaluate the stability of computer-guided zygomatic implant placement associated with customized guided drill keys.

## II. Material And Methods

The present study was conducted on 6 patients who had severely atrophic edentulous upper arch, to be treated with 12 zygomatic implants, at least 8-12 mm vertical bone height in anterior maxilla to allow placement of 2 conventional implants, ZAGA 3 or ZAGA 4 patients, both sexes, medically free patient.

Exclusion criteria were any systemic illness/medications that interfere with the treatment, radiation therapy to the head and neck region, bisphosphonates medication, heavy Smoking, pregnant and lactating women, alcohol/ drug addiction, maxillary sinusitis.

**Study Design:** Clinical case series study

**Study Location:** The study was done after approval from the Ethical Committee Cairo University Hospitals, Egypt. An informed written consent was obtained from the patients.

**Sample size:** 6 patients.

**Subjects & selection method:** The present study was conducted on 6 patients who had severely atrophic edentulous upper arch, to be treated with 12 zygomatic implants, at least 8-12 mm vertical bone height in anterior maxilla to allow placement of 2 conventional implants, ZAGA 3 or ZAGA 4 patients, both sexes, medically free patient.

**Inclusion criteria:**

1. Patients who had severely atrophic edentulous upper arch, to be treated with 12 zygomatic implants, at least 8-12 mm vertical bone height in anterior maxilla to allow placement of 2 conventional implants,
2. ZAGA 3 or ZAGA 4 patients.
3. Both sexes.
4. Medically free patient.

**Exclusion criteria:**

1. Patients with any systemic illness/medications that interfere with the treatment.
2. Radiation therapy to the head and neck region.
3. Bisphosphonates medication.
4. Heavy Smoking.
5. Pregnant and lactating women.
6. Alcohol/ drug addiction.
7. Maxillary sinusitis.

**Procedure methodology**

**Implants and Surgical Guide Planning & Fabrication:** The resulting axial slices were uploaded into software and segmentation of the maxillary-zygomatic complex was performed to create STL model. As second step, two ZIs were planned with implant planning software (3diagnosys version 4.2, 3diemme Italy). One for each side, with an extra-sinus path with a lateral upward angulation. Implants angulations, positions and dimensions were adjusted. The implant's apex was positioned to pass through the zygomatic bone in a bi-cortical manner to obtain the maximum anchorage. Once the surgical plan was finished, the dataset allowed to design the Zygora drill surgical guide using Platyclade 3diemme, Italy designing software then exported as a STL (standard triangulation language) file to be fabricated using 3D printing process.

**The Zygora drill custom-made keys** was designed with a cylindrical tunnel to guide the long twist drill for the Zygomatic implant osteotomy at the entrance point with drill keys and sleeves that are aligned along the same axis. The design and production of this device made use of the latest digital technologies including CAD software and additive manufacturing. Titanium prototypes and the final optimized device were produced using SLS.

**Surgical Procedure**

A full-thickness palatal-crestal incision is made in the alveolar ridge tissue from first molar to first molar. Two oblique distal releases are made on each side of the incision to provide full visibility of all the anatomical structures involved, specifically, the lateral wall of the maxilla in the area of the maxillary sinus, base of the orbit and infraorbital foramen and rim of the zygomatic process. Additionally, part of the palate is dissected to facilitate access and visibility. The bone-supported surgical drill guide was placed and fixed with two 2.2 mm diameter mono-cortical osteosynthesis screws to provide a stable fitting of the guide to the bone preventing any tilting or movement, then implant site preparation continued. Firstly with a round bur creating a notch in zygomatic bone facilitating the approach for the next drill, progressively increasing the diameter of the drills to avoid overheating the bone and to facilitate insertion of the implant. Drilling begins with Ø 2.8 JDZygora and continues with 3.2 JDZygora and Ø 3.6 JDZygora. The entire drilling process is carried out with abundant irrigation to avoid overheating, the drill passes through the drill guide key and surgical guide and perforates the alveolus, to reach the inferior surface of the zygomatic process and make sure that it makes a penetrating point to achieve bicortical stabilization of the zygomatic implants. Visual confirmation of the exit of the drill is very important. In all patients the implants used were (JDZygora Ø 4.3mm), the implants were

carried on by their fixture mount and inserted manually into position at the prepared osteotomy. Two conventional implants have been placed in the anterior region.

Measurements (ISQs) of zygomatic implants were taken by Osstell device. The resonance frequency value of the implant was measured through a transducer (JDEvolution type 32 100440 SmartPeg) with maintain approximately 1-3 mm, angle of 90 degrees, and 3 mm above the soft tissue which is mounted directly to the implant with a screw. The measurements were performed in the mesial, distal, buccal and palatal/lingual directions, for zygomatic implant and taken twice by two different observers. The mean of the measurements is 60 Ncm.

After implant insertion, conical abutments are placed to correct lack of parallelism between the implants and facilitate screw-retained prosthesis.

Connection of the Straight Conical Abutment JDEvolution by Screw it onto the head of the implant in the correct position using the plastic transporter that comes assembled. Once the abutment is in position the plastic transporter manually detaches from it. Then the Screw torqued in the abutment at 35 Ncm using the dynamometric key JD Torque®.

Connection of the Angled Conical Abutment JDEvolution abutment by its preassembled transporter. The Multi-unit Aligning Instrument is helping to optimize the final abutment position and prosthetic design. Then screw torqued in at 35 Ncm using the dynamometric key JD Torque®.

The surgical wound was irrigated with sterile saline then the flap was repositioned back and sutured with 4-0 vicryl suture in a continuous suture manner.

Post-operative Protocol: use external cold application to the surgical area for (4-6 hours) to reduce the post-operative edema, also were instructed to eat soft diet for the first 8 weeks. Oral hygiene measures required, and patients were dismissed and recalled after 24hours for checkup. After one week the patient presented for suture removal.

A Post-operative CT scan of each patient with implants was taken after the surgery for the post-operative comparison.

**Prosthetic Follow-up:** During surgery and after all implant installation a multiunit abutment were installed with the aid of multiunit guide to place the proper inclination (17-30-45) degree, after four months, the patient was recalled. The implants were relocated using the surgical stent and exposed by punching out the covering soft tissue under local anesthesia. the permanent transmucosal titanium abutments (Multiunit abutments) were torqued to 35N using torque ratchet.

Using Exocad software patient old denture was scanned extra-orally and stl file was imported to exocad for reshaping denture flange, fitting surface, tooth shape, texture, size and printed with 3d printer, Titanium sleeves was fixed on patient mouth and titanium bar was fixed in a passive fit over the sleeves and welded by intra oral welding using JD welding machine and passivity checking test was done by using one screw test then the 3D printed complete denture was empties over the fixed titanium sleeves, pickup of the sleeves with acrylic resin material placed on complete denture fitting surface, after acrylic resin material harden trimming of excess titanium sleeve was done then the prosthesis was screwed intra-orally and fine occlusal adjustments were made, the prosthetic screws were tightened to 10 Ncm with a torque wrench. The access holes were partially plugged with Teflon tape and completely blocked with light cure flowable composite.

**Zygomatic Implant Stability:** resonance Frequency Analysis (RFA) is available for the assessment of implant stability as a function of interface stiffness during treatment., measures the resonance frequency (RF) of a transducer that is attached to the implant. With the JDEvolution type 32 100440 SmartPeg Fig (54), the RF in Hz is translated to an implant stability quotient (ISQ) unit between 1 and 100, where increased values reflect increased stability.

### **Statistical analysis**

Statistical analysis was done by SPSS v20®, Graph Pad Prism® and Microsoft Excel 2016. All quantitative data were explored for normality by using Shapiro Wilk and Kolmogorov Normality test and presented as minimum, maximum, means and standard deviation (SD) values.

### **III. Result**

The present study was conducted on 6 patients: 3 males (50%) and 3 females (50%). The mean with a mean age of 48.75 years old. Each patient received two to four zygomatic implants and two conventional implants. Table 1

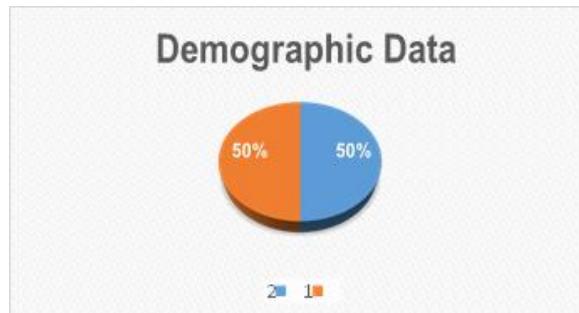


Figure 3: Demographic Data With 1- 50% Male And 2- 50% Female

Zygomatic Implant Dimensions are shown in table

Table 1: Zygomatic Implant Dimensions

Implant number	Implant size (mm)	
	Diameter	Length
1	4.3	30
2	4.3	35
3	4.3	37.5
4	4.3	40
5	4.3	42.5
6	4.3	45
7	4.3	47.5
8	4.3	50
9	4.3	52.5
10	4.3	55
11	4.3	57.5
12	4.3	60

Data originated from normal distribution (parametric data) resembling normal Bell curve in all groups. Table 2

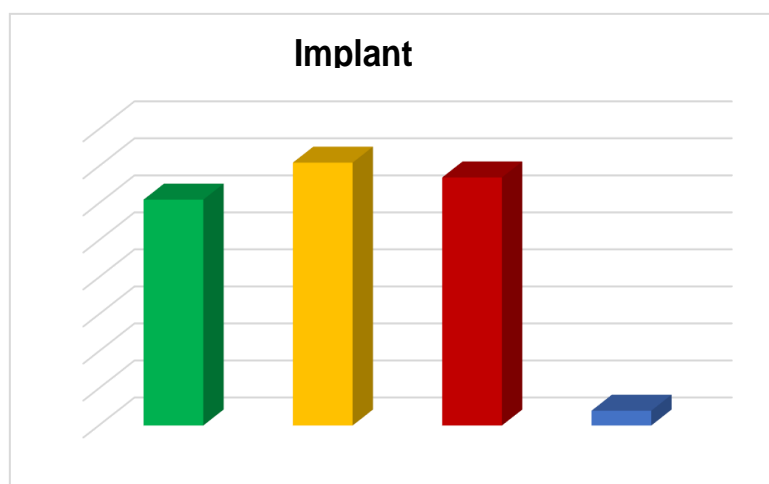
Table 2: Normality exploration of all groups:

	P value	Indication
M-D angle degrees	>0.05	Normal data
B-L angle degrees	>0.05	Normal data
Coronal Linear deviation mm.	>0.05	Normal data
Apical Linear deviation mm.	>0.05	Normal data
Vertical deviation	>0.05	Normal data

The mean ± standard deviation values of zygomatic implant stability was 67 ± 4.00 with a minimum of 61 and a maximum of 71 mm. Table 3, figure 4

Table 3: Implant stability, minimum, maximum, mean and standard deviation of implant stability

	Implant stability
Minimum	61.00
Maximum	71.00
Mean	67.00
Std. Deviation	4.00



**Figure 4: Bar chart representing Minimum, maximum, mean and standard deviation of implant stability**

#### IV. Discussion

The use of zygomatic implant however necessitates a thorough understanding of the anatomy of zygoma and its related structures to avoid iatrogenic injury to important structures such as orbital plate, infra orbital nerve, and the zygomatic arch.

In comparison to conventional surgical and prosthetic treatments, the computer-guided surgical protocol appears to be superior. Because of its minimally invasive nature, predictability, and reduced operational and recuperation time requirements, it offers prosthetically driven surgery. According to studies by Aparicio et al [6], Papaspyridakos et al. [5], zygomatic implants as a therapeutic modality shown a high rate of success in the treatment of atrophic maxilla when paired with conventional implants.

Computer-guided surgery is intended to support preoperative preparation for a more secure and reliable treatment result. Transferring dental implant planning on a computer screen has many benefits, including improved anatomical case visualization, precise measurements, data processing for the best implant allocation and size selection, as well as comprehensive documentation of patient care.

For edentulous patients, guided surgery is either soft tissue- or bone- supported, where the soft tissue above the ridge is totally reflected and the guide is settled and rests on the bone directly. Guided surgery is tooth-supported when there are available teeth near the implant site.

In order to measure the accuracy of virtual computed planning of the implants, an overlap of the planned and post-operative position was made using the same planning software and it was found that there was apical, coronal and vertical deviation.

For implant stability the mean  $\pm$  standard deviation values of zygomatic implant stability were  $67 \pm 4.00$  with a minimum of 61 and a maximum of 71 mm.

From our experience in this study, deviation between the planned and post-operative position of zygomatic implant could be affected by more than one factor: the multiple steps including hardware, software, and surgery procedure, the shift of long zygomatic drill within the key during drilling with difficulty in manipulation and working under stress as a result of posterior location of point of entry at premolar molar area especially with patient with limited mouth opening or patients who have teeth in the lower jaw, minute deviation between the drill and the key with the long drills used for zygomatic implants, this small deviation in the coronal area due to shifting of the drill in the key which may be reflected with relatively larger deviation in apical, the nature of Zygoma bone (compact bone and its shape) which leads to the slippage of the initial drill at the zygomatic surface, the surgical guide used in this study controlled the entry point and the drill direction but not the exit point at the zygomatic bone.

In order to decrease this deviation some trials were made like the device was done by Chow et al [10] designed a device that guides the osteotomy from the entry point to the exit point, allowing optimal positioning, to increase the precision of the guided surgical placement of zygomatic implants.

#### V. Conclusion

The reconstruction of the atrophic maxilla made use of computer-guided zygomatic implant placement associated with customized guided drill keys. allow for precise, safe, graft-free, minimally invasive surgery and high patient satisfaction.

### References

- [1]. Aparicio C, Perales P, Rangert B. Tilted Implants As An Alternative To Maxillary Sinus Grafting: A Clinical, Radiologic, And Periotest Study. *Clin Implant Dent Relat Res.* 2001;3:39-49.
- [2]. Toljanic JA, Baer RA, Ekstrand K, Thor A. Implant Rehabilitation Of The Atrophic Edentulous Maxilla Including Immediate Fixed Provisional Restoration Without The Use Of Bone Grafting: A Review Of 1-Year Outcome Data From A Long-Term Prospective Clinical Trial. *Int J Oral Maxillofac Implants.* 2009;24:518-26.
- [3]. Balshi TJ, Wolfinger GJ, Shuscavage NJ, Balshi SF. Zygomatic Bone-To-Implant Contact In 77 Patients With Partially Or Completely Edentulous Maxillas. *J Oral Maxillofac Surg.* 2012;70:2065-9.
- [4]. Vrielinck L, Blok J, Politis C. Survival Of Conventional Dental Implants In The Edentulous Atrophic Maxilla In Combination With Zygomatic Implants: A 20-Year Retrospective Study. *Int J Implant Dent.* 2022;8:27-8.
- [5]. Papaspyridakos P, Chen C-J, Singh M, Weber H-P, Gallucci G. Success Criteria In Implant Dentistry: A Systematic Review. *J Dent Res.* 2012;91:242-8.
- [6]. Aparicio C. A Proposed Classification For Zygomatic Implant Patient Based On The Zygoma Anatomy Guided Approach (ZAGA): A Cross-Sectional Survey. *Eur J Oral Implantol.* 2011;4:269-75.
- [7]. Van Steenberghe D, Malevez C, Van Cleynenbreugel J, Bou Serhal C, Dhoore E, Schutyser F, Et Al. Accuracy Of Drilling Guides For Transfer From Three-Dimensional CT-Based Planning To Placement Of Zygoma Implants In Human Cadavers. *Clin Oral Implants Res.* 2003;14:131-6.
- [8]. Chrcanovic BR, Oliveira DR, Custódio AL. Accuracy Evaluation Of Computed Tomography-Derived Stereolithographic Surgical Guides In Zygomatic Implant Placement In Human Cadavers. *J Oral Implantol.* 2010;36:345-55.
- [9]. Van De Wiele G, Teughels W, Vercruyssen M, Coucke W, Temmerman A, Quirynen M. The Accuracy Of Guided Surgery Via Mucosa-Supported Stereolithographic Surgical Templates In The Hands Of Surgeons With Little Experience. *Clin Oral Implants Res.* 2015;26:1489-94.
- [10]. Chow J. A Novel Device For Template-Guided Surgery Of The Zygomatic Implants. *J Maxillofac Surg.* 2016;45:1253-5.