

# Histopathological Study Of Colonoscopic Biopsies In Pediatric Age Group Patients At A Tertiary Care Hospital Of South India

Dr. Bibhas Saha Dalal<sup>1</sup>, Dr. Vikas Karamchand Dagar<sup>1</sup>,  
Dr. Sudhanshu Shekhar<sup>1</sup>, Dr. Santosh Kumar Mondal<sup>2</sup>, Dr. Rangaswamy M<sup>3</sup>,  
Dr. Sunila<sup>3</sup>

<sup>1</sup>(Assistant Professor, Department of Pathology & Lab Medicine, AIIMS Kalyani, India)

<sup>2</sup>(Professor and HOD, Department of Pathology & Lab Medicine, AIIMS Kalyani, India)

<sup>3</sup>(Professor, Department of Pathology, JSS Medical College, India)

---

## Abstract:

**Background:** Colonic diseases, including polyps, impose a substantial health burden, impacting millions annually. Colonic polyps, although less common in children, require early detection due to potential complications, including malignancy. This study aimed to investigate pediatric colonic biopsies, their clinical presentation, and histopathological findings, shedding light on the prevalence of juvenile polyps and Hirschsprung disease in this population.

**Materials and Methods:** A one-year descriptive study was conducted at a tertiary care teaching hospital in India. Pediatric patients (<12 years) who underwent colonoscopic biopsies from 2011 to 2012 were included. Clinical data and colonoscopic findings were recorded. Biopsies were histopathologically evaluated, and correlations between colonoscopic and histopathological diagnoses were made.

**Results:** Of the 20 pediatric cases studied, 15 met inclusion criteria. The majority were males (86.66%), with ages ranging from neonates to 11 years. Rectal bleeding (91.67%) was the most common clinical presentation, followed by constipation (20%). Histopathological examination revealed 11 cases of juvenile polyps, 3 cases of Hirschsprung disease, and 1 case of non-specific colitis. All cases provisionally diagnosed as rectal polyps on colonoscopy were confirmed as juvenile polyps histopathologically, while Hirschsprung disease and colitis diagnoses were also consistent.

**Conclusion:** This study underscores that juvenile polyps are the most prevalent colonic lesion in pediatric patients presenting with painless rectal bleeding. Hirschsprung disease is the leading cause of constipation in infants. The limited number of cases in this study may be attributed to the hesitance towards invasive procedures like colonoscopy in children. Early colonoscopy is recommended in symptomatic pediatric patients to diagnose and treat colorectal lesions promptly, preventing potential long-term complications. Larger multicentric studies are needed to provide a more comprehensive understanding of these conditions in the pediatric population.

**Key Word:** Colonoscopic biopsies; Pediatric; Histopathology; Polyps; Hirschsprung disease

---

Date of Submission: 20-09-2023

Date of acceptance: 30-09-2023

---

## I. Introduction

Colonic diseases pose a significant health burden, causing both morbidity and mortality, affecting millions of individuals annually.<sup>1</sup> Among these conditions, colonic polyps are frequently diagnosed during colonoscopy, characterized by abnormal growths from the colonic mucosa, which can appear as either pedunculated or sessile outgrowths.<sup>2</sup> The advent of flexible endoscopes has led to a substantial rise in the number of examinations and colonic mucosal biopsies conducted.<sup>1</sup> While colonic polyps are less common in children compared to adults, it is still very crucial to detect and remove them early, as they can result in complications such as intestinal obstruction, anaemia, haemorrhagic shock and even cancer.<sup>3,4</sup>

Most polyps identified in childhood are typically benign, sporadic and few in numbers. They can be classified into various pathological types, including juvenile, inflammatory, hamartomatous, hyperplastic, and adenomatous polyps. Benign polyposis syndromes such as juvenile polyposis syndrome (JPS) and adenomatous polyps with malignant potential associated with syndromes like familial adenomatous polyposis (FAP), Gardner's syndrome, and Turcot's syndrome are also encountered in children.<sup>3,4,5</sup>

Polyps should be suspected in children presenting with abdominal pain, altered bowel habits and rectal bleeding. While colonoscopy is not commonly performed in children due to its invasive nature, it should be considered in suspected polyp cases. Full colonoscopic evaluation is essential, and parents of patients with more than three polyps and/or a family history of polyposis should be informed about the increased risk of future malignancy if polyps persist or recur.<sup>4,6</sup>

## **II. Material And Methods**

This descriptive study was carried out on pediatric colonoscopic biopsies received in the Department of Pathology in collaboration with Department of Gastroenterology at JSS medical college Mysuru, Karnataka, India. The duration of study was 1 year. After institutional ethical clearance, a total of 20 colonoscopic biopsies were received in Department of Pathology. After taking consent from the parents of pediatric patients, the cases were included in the study and histopathological evaluation of the submitted biopsies were done after recording all the patients' details.

**Study Design:** Descriptive observational study

**Study Location:** This was a tertiary care teaching hospital-based study done in Department of Pathology, at JSS Medical College & Hospital, Mysuru, Karnataka, India.

**Study Duration:** 1 year, from 2011 to 2012.

**Sample size:** 15 patients.

**Sample size calculation:** All the pediatric patients who underwent colonoscopy biopsies during 2011 -2012 were included after taking the consent.

### **Inclusion criteria:**

1. All the colonic biopsies from patients aged <12 years were included.

### **Exclusion criteria:**

1. Inadequate biopsy material for histopathology reporting
2. Age of patients >12 years
3. Patient denying consent for the study

### **Procedure methodology**

Clinical details along with a detailed description of the colonoscopic findings and procedure performed were obtained and maintained according to the proforma. During the procedure, any gross pathology was noted and biopsies were taken from representative areas. An attempt was made by the clinician to give a colonoscopic diagnosis in all the cases. All the colonoscopic biopsy specimens were immediately fixed in 10% formalin for 24 hrs. It was then processed and embedded in paraffin. Five microns thick serial sections were prepared and then stained with Haematoxylin and Eosin. Detailed study of the sections was performed under the light microscope. Adequacy of biopsy was assessed and an attempt was made to correlate the histopathological diagnosis with the colonoscopic diagnosis offered. Histopathological colonoscopic biopsy diagnosis was correlated with the histopathological diagnosis of the colectomy specimens in 8 cases.

Special stains like PAS, Alcian-Blue, Mucicarmine, Congo-red and AFB were done wherever necessary.

### **Statistical analysis**

Data was analyzed using Microsoft office excel 2021.

## **III. Result**

During the period of present study, 2011 to 2012, in the Department of Pathology, JSS Medical College & Hospital, Mysuru, 20 pediatric patients colonoscopic biopsy specimens were examined. Of the 20 cases, 03 parents denied to give consent, 02 cases were classified as biopsy specimen inadequate for an accurate interpretation and hence excluded from the study.

Of the 15 cases, 11 cases were diagnosed as Juvenile polyps, 03 cases were diagnosed as Hirschsprung disease and 01 case was diagnosed as non-specific colitis after histopathological examination of biopsy specimens.

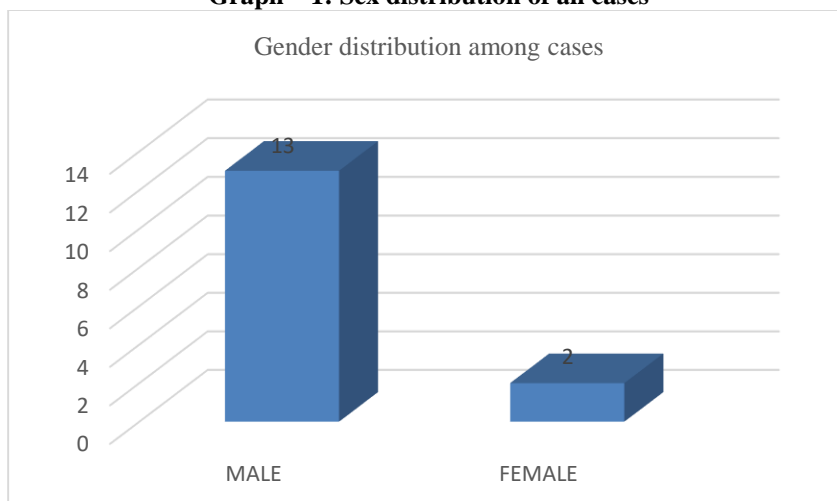
### **Clinical presentation**

In the present study involving fifteen cases, colonoscopic biopsy was performed on patients of age groups <12 years, ranging in age from a 7 days old neonate to 11 years old child. The majority of cases were males 13(86.66%) with females comprising 02 (13.34%) cases (**Table 1, Graph 1**).

**Table-1: Sex distribution of all cases**

Sl. No.	Sex	Number of cases	Percentage
1.	Male	13	86.66%
2.	Female	02	13.34%
Total		15	100%

**Graph – 1: Sex distribution of all cases**



Maximum numbers of cases 06 (40%) cases were observed in the 4-5 years age group, followed by 0-1 year in which 4 (26.66%) cases were noted (**Table 2**). Of all the cases, 12 were vegetarians and 03 were breastfeeding.

**Table – 2: Age distribution of all cases**

Age group (Years)	Number of cases	Percentage
0-1	4	26.66%
2-3	1	6.66%
4-5	6	40%
6-7	2	13.33%
8-9	1	6.66%
10-11	1	6.66%
12	0	0%
Total	15	100%

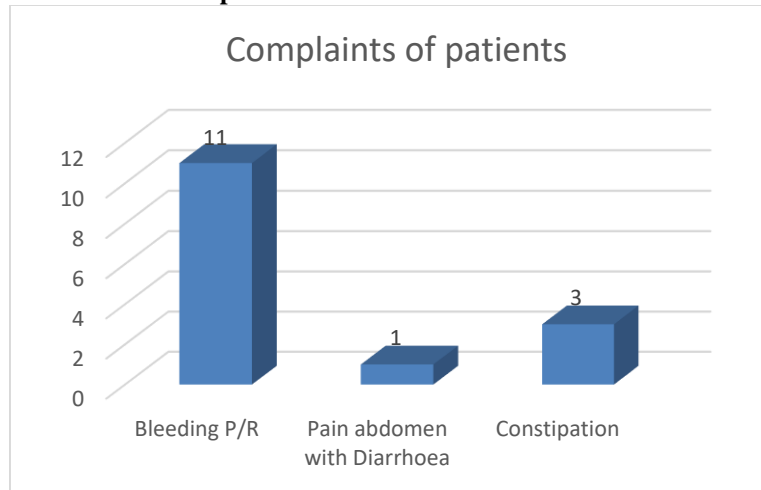
In the present study, the clinical features observed in order of frequency were rectal bleeding 11(91.67%), pain in abdomen with diarrhoea 01 (8.33%) and constipation 03(20%) cases (**Table 3, Graph 2**). Same patient had both symptoms of pain in abdomen with diarrhoea.

**Table – 3: Clinical features of all cases**

Sl. No.	Clinical feature	Number of cases	Percentage
1.	Bleeding P/R	11	73.33%
2.	Pain abdomen with Diarrhea	01	6.66%

3.	Constipation	03	20%
----	--------------	----	-----

**Graph –2: Clinical features of all cases**



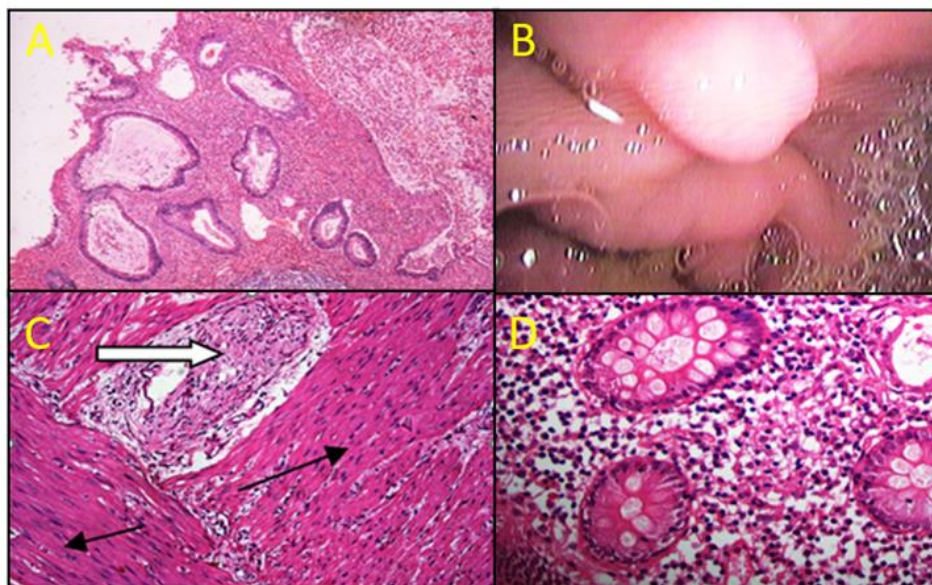
**Microscopic features in all cases**

In the present study, 11 cases were rectal polyp, 03 cases were diagnosed as Hirschsprung’s disease and 01 case was of non-specific colitis.

There were 11 cases of juvenile polyps which were characterised by ulceration covered by granulation tissue at the surface. Beneath, there were cystically dilated glands filled with mucus, devoid of atypical features, and separated by an inflamed and oedematous stroma (**Fig. 1 A**). All the studied polyps were negative for dysplasia.

Three cases were diagnosed as Hirschsprung disease characterised by nerve hypertrophy in the myenteric plexus with absence of ganglion cells (**Fig. 1B**).

Non-specific colitis showed well-preserved architecture of mucosal glands, normal goblet cells, and a mixed inflammatory cell infiltrate composed of neutrophils, lymphocytes and plasma cells in the lamina propria along with mild oedema and crypt cell proliferation with sometimes necrosis (**Fig. 1C**).



**Fig 1. (A) Juvenile polyp - Cystically dilated glands filled with mucus, (4x: H&E), (B) Colonoscopic picture of a rectal polyp, (C) Hirschsprung disease -Thick white arrow showing hypertrophic nerves, and thin black arrows showing absence of ganglion cells, (20x: H&E), (D) Chronic non-specific colitis - Mild oedema with mixed inflammatory cell infiltrate in the lamina propria, (10x: H&E)**

**Correlation of Clinical and Colonoscopic findings among cases**

In the present study as shown in **Table no. 4**, 11 cases diagnosed as rectal polyps on colonoscopy, clinically presented as rectal bleeding, 3 cases presenting with constipation were provisionally diagnosed as Hirschsprung disease and 01 case presenting with pain in abdomen with diarrhoea was provisionally labelled as a case of colitis.

**Correlation of Colonoscopic and histopathological findings among cases**

In the present study as shown in **Table no 4**, the cases diagnosed as rectal polyps on colonoscopy were proven to be juvenile polyps on histopathological examination in 100 percent cases. The polyps were 0.5-3 cm in size and single in number in all cases (**Fig. 1C**). All 03 cases which were provisionally diagnosed as Hirschsprung disease on colonoscopy were confirmed on histopathological examination. The single case provisionally diagnosed as colitis on coloscopy was reported as non-specific colitis after histopathological examination.

**Table-4: Correlation of Colonoscopic and histopathological finding among cases**

Sl. No.	Clinical feature	Colonoscopic diagnosis	Histopathological diagnosis	Number of cases (n=15)
1.	Bleeding P/R	Rectal polyp	Juvenile polyp	11(73.33) %
2.	Pain abdomen with Diarrhea	colitis	Non-specific colitis	01(6.66%)
4.	Constipation	Hirschsprung's disease	Hirschsprung's disease	03(20%)

**IV. Discussion**

The mean age of the patients was 4.19±3.04 years. Similar results were also observed in studies conducted by Mandhan et al.<sup>7</sup> in Pakistan and Ko et al.<sup>8</sup> in Taiwan. A majority of the children were males and aged between 2.5 and 12 years. A similar preponderance of males was observed by Mandhan et al.<sup>7</sup>, Ko et al.<sup>8</sup>, Poddar et al.<sup>9</sup>, and Thakkar et al.<sup>10</sup>. This could be because parents in India, even today are more biased towards male child than female child.

The most common indication of colonoscopy in the present study was bleeding per rectum in 73.33% cases, all of whom were diagnosed as rectal polyps on colonoscopy. In the study published by Alison Morag Campbell et al.<sup>11</sup> 57% of the patients with colorectal polyps on colonoscopy, also presented with painless rectal bleeding. Similarly, Khushdil et al's<sup>12</sup> paper gives the rate of almost a 60% polyp pickup rate among patients presenting with rectal bleeding in Pakistan, and a paper from India by Poddar et al. also revealed a 61% pickup rate<sup>9</sup>.

In the present study all the polyps in 11 cases were rectal in origin and solitary in nature. In the study done by Subarna Rani Das et al.<sup>13</sup> found that 57% of the polyps were located in the rectal region. Yinghui Wang et al.<sup>4</sup> also concluded that solitary rectal polyps are the most common type of polyps (50.6%) in children. In their study they also found that polyps were detected predominantly in males (72.9%) with rectal bleeding being the primary clinical manifestation (80.25%), which is also in concurrence with the present study. In the study done by Yinghui Wang et al<sup>4</sup> most of the polyps were juvenile (88.9%) and solitary); were located in the rectosigmoid area. In the study done by Lee BG et al,<sup>14</sup> 75.9% polyps were solitary and located most commonly in rectum in 61.4% cases. The polyp size in this study, ranged from 0.3 to 5 cm, which is also similar to our findings of polyp size 0.5-3 cm.

In our study, after histopathological examination, 100 % cases were consistent with juvenile polyps, which were provisionally diagnosed as rectal polyps by colonoscopy. Similar findings were noted in the study done by Subarna Rani Das et al,<sup>13</sup> in which the histopathological diagnosis of juvenile polyps correlated with colonoscopic findings in 100% cases. Similar histopathological features for solitary juvenile polyps were reported in these studies which showed typical dilated cystic glands, exuberant lamina propria with marked vascularity, areas of ulcerations, and increased numbers of inflammatory cells, including neutrophilic granulocytes.

In the present study we found 03 cases of Hirschsprung disease presenting with similar complaints of constipation and the age of the patients were 7 days, 4 month and 7 months respectively with average age of 3.74 months. This is similar to the findings of the study done by Puri P<sup>15</sup> in which 80%-90% of neonates diagnosed as Hirschsprung disease, typically present with delayed passage of meconium, bile-stained vomiting, and abdominal distension. In the present study all the three cases which were provisionally diagnosed as Hirschsprung disease by colonoscopy had undergone histopathological examination and Hirschsprung disease was confirmed in 100% cases. In the study done by Muise ED et al<sup>16</sup> in 2016, histopathological findings reported in cases of Hirschsprung disease were absence of ganglion cells in myenteric and submucosal ganglia with a thickness of nerve bundles, which is similar to our study as well.

There are some limitations in this study. This was a single-center observational study for a short duration and included small number of cases which might not be a true representation of a large population. This could be due to parental apprehensions regarding an invasive procedure like colonoscopy in pediatric patients. So, multicentric studies with larger sample size are required.

## V. Conclusion

In conclusion, the study shows that the most common lesion in pediatric age group patients, presenting with complaint of painless rectal bleeding, is juvenile polyp. None of the cases had more than one polyp and hence Juvenile Polyposis Syndrome was ruled out. Moreover, of all the cases presenting with painless rectal bleeding, none was diagnosed with anemia, which is more commonly associated with polyposis syndromes. The newborn cases presenting with constipation were all diagnosed as Hirschsprung disease. The lower number of cases in our study can be possibly attributed to lower acceptance rate of an invasive procedure like colonoscopy, especially in pediatric age group. As pediatric patients are unable to explain the exact symptoms, most of the treatable causes are often neglected. This negligence leads to impaired growth, nutritional deficiencies, inactiveness, impaired learning abilities, etc. We strongly recommend colonoscopy in symptomatic pediatric age group patients to diagnose colorectal lesions at an early age.

## References

- [1]. Teague RH, Salmon PR, Read AE. Fiberoptic Examination Of The Colon: A Review Of 255 Cases. *Gut* 1973; 14:139.
- [2]. Øines M, Helsing LM, Brethauer M, Emilsson L. Epidemiology And Risk Factors Of Colorectal Polyps. *Best Pract Res Clin Gastroenterol.* 2017 Aug;31(4):419-424.
- [3]. Adolph VR, Bernabe K. Polyps In Children. *Clin Colon Rectal Surg.* 2008 Nov;21(4):280-5
- [4]. Wang Y, Fang L, Huang K, Pan T, Lu H, Yan X. Characteristics And Risk Factors For Colorectal Polyps Among Children In An Urban Area Of Wenzhou, China: A Retrospective Case Control Study. *BMC Pediatr.* 2023 Aug 19;23(1):408.
- [5]. Durno CA. Colonic Polyps In Children And Adolescents. *Can J Gastroenterol.* 2007 Apr;21(4):233-9
- [6]. Pillai RB, Tolia V. Colonic Polyps In Children: Frequently Multiple And Recurrent. *Clin Pediatr (Phila).* 1998 Apr;37(4):253-7
- [7]. Mandhan P. Juvenile Colorectal Polyps In Children: Experience In Pakistan. *Pediatr Surg Int* 2004; 20:339-42.
- [8]. Ko FY, Wu TC, Hwang B. Intestinal Polyps In Children And Adolescents--A Review Of 103 Cases. *Zhonghua Min Guo Xiao Er Ke Yi Xue Hui Za Zhi* 1995; 36:197-202.
- [9]. Poddar U, Thapa BR, Vaiphei K, Et Al. Colonic Polyps: Experience Of 236 Indian Children. *Am J Gastroenterol* 1998; 93:619-22.
- [10]. Thakkar K, Alsarraj A, Fong E, Et Al. Prevalence Of Colorectal Polyps In Paediatric Colonoscopy. *Dig Dis Sci* 2012; 57:1050-5.
- [11]. Campbell AM, Sugarman I. Does Painless Rectal Bleeding Equate To A Colonic Polyp? *Arch Dis Child.* 2017; 102:1049-1051.
- [12]. Khushdil A, Ali S, Malik R, Et Al. Etiology Of Lower GI Bleeding In Paediatric Patients, At Colonoscopic Surgery. *Pak Armed Forces Med J* 2014; 64:484-7.
- [13]. Das SR, Karim ASMB, Rukonuzzaman M, Mazumder MW, Alam R, Benzamin M, Marjan P, Sarker MN, Akther H, Mondal M. Juvenile Polyps In Bangladeshi Children And Their Association With Fecal Calprotectin As A Biomarker. *Pediatr Gastroenterol Hepatol Nutr.* 2022 Jan;25(1):52-60.
- [14]. Lee BG, Shin SH, Lee YA, Wi JH, Lee YJ, Park JH. Juvenile Polyp And Colonoscopic Polypectomy In Childhood. *Pediatr Gastroenterol Hepatol Nutr.* 2012 Dec;15(4):250-5.
- [15]. Puri P. *Newborn Surgery* 3rd Ed. London: CRC Press; 2011.
- [16]. Muise ED, Cowles RA (2016) Rectal Biopsy For Hirschsprung's Disease: A Review Of Techniques, Pathology, And Complications. *World J Pediatr* 12(2): 135-341.