

Pituitary Apoplexy Revealed By Bilateral Blindness : (About A Case And Literature Review)

Louday L¹, Damoune I^{1,2}, Ajdi F^{1,2}, Chraibi A²,

¹ Endocrinology, Diabetology And Metabolic Diseases Department Chu Agadir Morocco

² Faculty Of Medicine And Pharmacy Ibn Zohr Agadir Morocco.

Abstract:

Pituitary apoplexy is a rare and potentially fatal endocrine and neurosurgical emergency, corresponding to sudden haemorrhage, infarction or necrosis within a pre-existing pituitary adenoma. We report the case of a 46-year-old patient who presented with sudden onset of headache with vomiting and bilateral blindness. Hormonal assessment and magnetic resonance imaging revealed a pituitary macroadenoma with haemorrhagic remodelling, and the patient underwent emergency surgery via the subfrontal route.

Keywords: Pituitary apoplexy, pituitary adenoma, hypopituitarism.

Date of Submission: 07-03-2024

Date of Acceptance: 17-03-2024

I. Introduction :

Pituitary apoplexy corresponds to an infarction or haemorrhage in a pituitary adenoma. It is associated with sudden headaches, consciousness disorders, endocrine signs and sometimes severe visual disorders, such as chiasmatic syndrome and oculomotor paralysis. Despite its relative rarity, it must be borne in mind because of the diagnostic difficulties and the medical and sometimes neurosurgical treatment decisions it requires as an emergency[1].

Clinical Case :

We report the case of a 46-year-old man, a chronic smoker who had weaned himself off the habit one month prior to admission, and who had neglected a visual problem in his right eye for years. He presented to emergency with a sudden onset of intracranial hypertension, intense headache, vomiting and bilateral blindness. The patient also reported decreased libido and erectile dysfunction.

The preoperative hormone profile showed hyperprolactinemia at 7544 ng/ml, with a slightly low LT4 of 7.70 pmol/l, TSH: 0.84 mui/ml, and ACTH: 10.8 ng/l.

The initial cerebral CT scan revealed a pituitary macroadenoma measuring 40 x 26 x 27 mm and compressing both optic nerves. Hypothalamic-pituitary magnetic resonance imaging showed a 40 x 26 mm apoplectic pituitary adenoma (Figures 1 and 2) with suspected retinal detachment and a retinal haemorrhage in the right eye. Visual function tests were consistent with end-stage bilateral optic neuropathy.

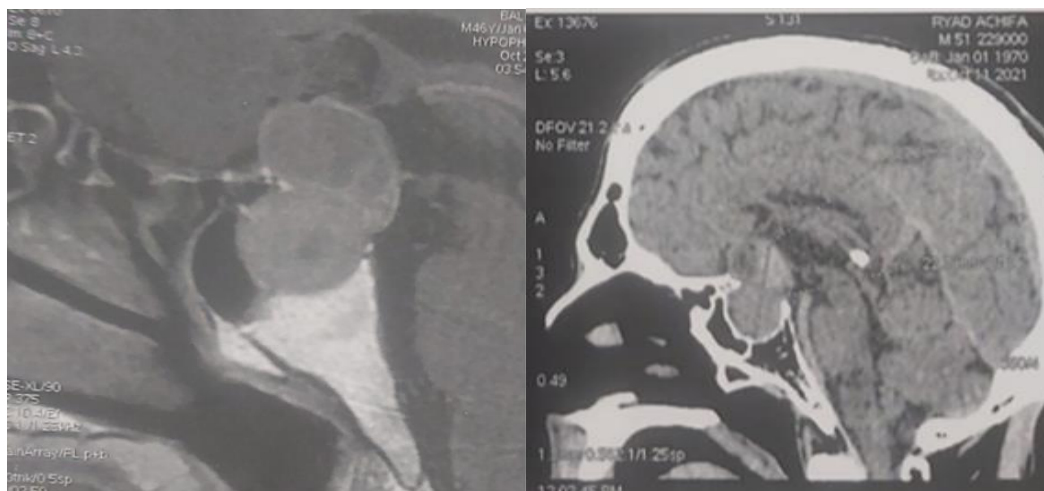


Figure 1 : MRI Of The Pituitary In Sagittal Section : Pituitary Macroadenoma 40x 26 Mm In Apoplexy
Figure2 : Pituitary CT Sagittal Section : Pituitary Macroadenoma 28x23 Mm

In the face of this apoplexy, the patient underwent emergency supplementation with 100 mg Hydrocortisone IV before being transferred to the operating theatre, and then underwent sub-frontal neurosurgical intervention. The patient was treated medically with Hydrocortisone supplementation of 100 mg IV, which was gradually reduced to 20 mg per day per os on discharge. The anatomopathological study was in favour of ischaemic necrosis of a pituitary adenoma with no sign of malignancy, and the immunohistochemical study was in favour of a pituitary adenoma expressing prolactin. The evolution was marked by a regression of headaches but without recovery of vision. A follow-up hormonal assessment revealed an anteropituitary insufficiency, which was replaced, along with persistent hyperprolactinaemia at 5670 ng/ml. The patient was then started on Cabergoline at the anti-tumour dose.

II. Discussion :

Definition And Epidemiology :

The term pituitary apoplexy was coined by Brougham in 1950, following a series of five patients who presented with the complete clinical syndrome of sudden onset of headache, vomiting, disturbed consciousness, visual abnormalities and haemodynamic instability in the context of haemorrhagic infarction of an adenoma [1].

Pituitary apoplexy is a rare but serious complication. It is an endocrine and neurosurgical emergency, which may occur as a result of haemorrhage or ischaemia in the pituitary gland. It affects 3% of patients with pituitary adenomas. In more than 2/3 of cases, patients are unaware of the existence of their adenoma before the acute complication [1,2].

Its incidence may vary between 0.6% and 16.8% in the general population (2-7% in pituitary adenomas) [3]. It occurs most often in macroadenomas but may also occur in microadenomas [4].

Pathophysiology Of Pituitary Apoplexy:

The pathophysiology of pituitary apoplexy remains poorly understood, but several factors may contribute to its occurrence : rarefied vascularisation of macroadenomas in a weak vascular context, the high energy demand of pituitary tumours, compression of feeder vessels by the mass against the sellar diaphragm, or the parietal fragility of capillaries. In this context, any source of hypoperfusion or increased metabolic demand (i.e. dynamic tests of the hypothalamic-pituitary axis) may precipitate apoplexy [3,5]. The use of anticoagulants but not anti-platelet agents [3].

Clinical Manifestations :

The clinical course of pituitary apoplexy may vary from subacute to more acute depending on the speed of onset and extent of intrasellar haemorrhage, necrosis and oedema [4, 5, 6].

The classic symptom is severe headache, present in over 80% of patients, which may be retro-orbital, frontal or diffuse. They are often associated with nausea and/or vomiting, mimicking a migraine or meningeal syndrome [6].

Visual disturbances are the second main symptom of pituitary apoplexy, with the classic bitemporal hemianopia linked to compression of the optic chiasm, leading to complete blindness depending on the extent of the lesions. Oculomotor paralysis also occurs in more than half of patients (due to compression of cranial nerves III, IV and VI running through the cavernous sinus) [6].

From an endocrine point of view, acute pituitary damage results in failure of one or more lineages of the hypothalamic-pituitary axis. The most common type of damage is to the corticotrophic line, which is observed in 50 to 80% of HA cases [6]. This is particularly important as it can be life-threatening in the event of acute decompensation [7].

Thyrotropic and gonadotropic axis abnormalities are seen in 50% and 75% of cases respectively [8].

Pituitary magnetic resonance imaging (MRI) is the gold standard for the positive diagnosis of pituitary apoplexy. However, if it is unavailable, cerebral computed tomography (CT) may help to establish the diagnosis [9].

MRI will show ischaemia, haemorrhage or a mixed necrotic/haemorrhagic appearance, which is most common in HA, with alternating hypointense and hyperintense areas depending on the weighting chosen. Unlike CT, MRI will be able to show haemorrhage, even several days after the acute episode. It will show the typical thickening of the mucosa of the sphenoid sinus, as well as assessing the tumour's relationship with adjacent structures, in order to help with management [8, 9].

Treatment :

Management of pituitary apoplexy is medical and surgical, with immediate surgical intervention indicated in cases of severe visual acuity loss, severe and persistent visual field amputation, or lasting impairment of consciousness [10].

A conservative approach is reserved for patients whose haemodynamic and neuro-ophthalmological condition stabilises following initial management with intravenous fluids and glucocorticoids [11].

For medical management, the Society for Endocrinology Endocrine Emergency Guidance suggests stabilisation of haemodynamic status with the immediate need for glucocorticoid supplementation, particularly in patients with indications for surgery, who are at greater risk of death[12].

In adults, the dose of hydrocortisone is 100 mg as an initial intramuscular (IM) bolus, followed by IM injections of 50 to 100 mg every 6 hours, or an initial intravenous (IV) bolus of 100 to 200 mg, followed by an infusion of 2 to 4 mg/hour using an IVSE electric syringe [13]. This is followed by a course of oral hydrocortisone acetate, generally in the region of 20 to 30 mg/day.

Careful ophthalmological and neurological monitoring should be undertaken in the event of conservative treatment, especially in the case of unilateral paresis and moderate visual field alterations, with surgery indicated in the event of clinical deterioration.

Hormonal supplementation of the affected cell lines, particularly the corticotrophic line, is always necessary in the acute phase, regardless of the management decision, whether interventional or not [13]. Thyroid hormone replacement therapy with L-Thyroxine should be started after corticosteroid therapy because of the risk of revealing relative adrenal insufficiency [13,14].

Prognosis And Follow-Up :

The prognosis depends on early diagnosis and treatment to preserve the visual prognosis by preventing the ultimate stage of irreversible and vital blindness[15].

However, there are factors with a poor prognosis, such as damage to the optic nerve or oculomotor muscles, as in the case of our patient. Or in the case of subarachnoid haemorrhage [14, 15].

Whereas 80% of patients present with residual hypopituitarism after apoplexy (with or without surgical decompression), and the risk of growth of an underlying adenoma is estimated at more than 20% in the 5 years following pituitary apoplexy [14]. Long-term follow-up is therefore essential [15].

III. Conclusion:

Despite its relative rarity, pituitary apoplexy must be borne in mind because of the diagnostic difficulties and the medical and sometimes neurosurgical therapeutic decisions that it requires as an emergency.

References

- [1]. Claessens M, Place S, Ruelle M, Dumasy V Et Vandemergel X : Thunderclap Headache As A Presenting Manifestation Of Pituitary Apoplexy Centre Hospitaliser Epicura, Mons Rev Med Brux 2019 ; 40 : 173-6
- [2]. Moreno C, Gomes L, Paiva I, Ruas L, Carrilho F (2015) Apoplexia Hipofisária No Serviço De Urgência. Revista Portuguesa De Endocrinologia, Diabetes E Metabolismo 10: 171-174
- [3]. Moller-Goede Di, Brandle M, Landau K, Bernays Rl, Schmid C. Pituitary Apoplexy: Re-Evaluation Of Risk Factors For Bleeding Into Pituitary Adenomas And Impact On Outcome. Eur J Endocrinol. 2011;164: 39-43.
- [4]. A. Semenov, E. Denoix, M. Thiebaut, A. Michon, J. Pouchot :Pituitary Apoplexy Following Coronary Bypass Surgery: A Case Report And Literature Review 2020 Published By Elsevier
- [5]. Li Y, Qian Y, Qiao Y, Chen X, Xu J, Zhang C, Et Al. Risk Factors For The Incidence Of Apoplexy In Pituitary Adenoma: A Single-Center Study From Southwestern China. Chin Neurosurg J 2020;6:20. <https://doi.org/10.1186/S41016-020-00202-4>
- [6]. Briet C, Salenave S, Bonneville J-F, Laws Er, Chanson P. Pituitary Apoplexy. Endocr Rev 2015;36:622–45. <https://doi.org/10.1210/Er.2015-1042>.
- [7]. Hahner S, Spinnler C, Fassnacht M, Et Al. High Incidence Of Adrenal Crisis In Educated Patients With Chronic Adrenal Insufficiency: A Prospective Study. J Clin Endocrinol Metab. 2015;100:407– 416.
- [8]. Doglietto F, Costi E, Villaret Ab, Mardighian D, Fontanella Mm, Giustina A. New Oral Anticoagulants And Pituitary Apoplexy. Pituitary. 2016;19:232-4.
- [9]. Albani A, Ferrà F, Angileri Ff, Esposito F, Granata F, Ferreri Fet Al. Multidisciplinary Management Of Pituitary Apoplexy. Int J Endocrinol. 2016;2016:7951536.
- [10]. Bashari Wa, Senanayake R, Fernández-Pombo A, Gillett D, Koulouri O, Powlson As, Et Al. Modern Imaging Of Pituitary Adenomas. Best Pract Res Clin Endocrinol Metab 2019;33:101278. <https://doi.org/10.1016/J.Beem.2019.05.002>.
- [11]. Rajasekaran S, Vanderpump M, Baldeweg S, Drake W, Reddy N, Lanyon M, Et Al. Uk Guidelines For The Management Of Pituitary Apoplexy: Uk Guidelines For The Management Of Pituitary Apoplexy. Clin Endocrinol (Oxf) 2011;74:9–20. <https://doi.org/10.1111/J.1365-2265.2010.03913.X>.
- [12]. Husted Nielsen E, Lindholm J, Bjerre P, Et Al. Fréquence De L'apoplexie Hypophysaire Chez Les Patients Présentant Un Adénome Hypophysaire Non Fonctionnel. Clin Endocrinol. 2006;64:319-322
- [13]. Baldeweg Se, Vanderpump M, Drake W, Reddy N, Markey A, Plant Gt, Et Al. Society For Endocrinology Endocrine Emergency Guidance: Emergency Management Of Pituitary Apoplexy In Adult Patients. Endocr Connect 2016;5:G12–5. <https://doi.org/10.1530/Ec-16-0057>.
- [14]. Pal A, Capatina C, Tenreiro Ap, Guardiola Pd, Byrne Jv, Cudlip S Etal. Pituitary Apoplexy In Non-Fonctionning Pituitary Adenomas : Longterm Follow-Up Is Important Because Of Significant Numbers Of Tumour Recurrences. Clin Endocrinology. 2011;75:501-4
- [15]. Zeina C Hannoush, Md And Roy E Weiss, M.D., Phd, Facp, Face, Pituitary Apoplexy Last Update: April 22, 2018.