

# Leukemic Gingival Enlargement: An Atypical Presentation

Dr. Mukta Motwani<sup>1</sup>, Dr. Apeksha Dhole<sup>2</sup>, Dr. Bushra Siddiquee<sup>3</sup>,  
Dr. Anwasha Ramteke<sup>4</sup>, Dr. Alka Dive<sup>5</sup>, Dr. Ashish Bodhade<sup>6</sup>

<sup>1,2,3,4</sup>(Department Of Oral Medicine And Radiology, Ranjeet Deshmukh Dental College Nagpur, Muhs, Nashik, India)

<sup>5,6</sup>(Department Of Oral Pathology, Ranjeet Deshmukh Dental College Nagpur, Muhs, Nashik, India)

---

## Abstract:

### Background:

Oral manifestations can be used to detect a range of systemic disorders. Gingival enlargement can occur owing to local circumstances, drugs, hormonal changes, or malignant disorders. Dental surgeons must accurately diagnose and refer patients with leukemia, a malignancy characterized by abnormal white blood cell proliferation in the bone marrow. Oral changes may be the only presenting feature, making timely diagnosis and referral crucial to avoid fatal outcomes. This article discusses a case of acute myeloid leukemia (AML) characterized by swollen gums for one month. Early diagnosis and beginning of treatment for leukemic gingival enlargement can enhance patient outcomes and prevent problems.

Around 50-80% of AML patients attain full remission, which is more common in youngsters and those under the age of 60. This report emphasizes the need for thorough oral examinations and investigations to uncover potentially life-threatening conditions.

---

Date of Submission: 14-04-2024

Date of Acceptance: 24-04-2024

---

## I. Introduction:

Gingival overgrowth, also known as "gingival enlargement," denotes an increase in the size of the gingiva and is categorized among various types of periodontal diseases<sup>1</sup>. Gingival enlargement can be classified based on etiological factors and pathological changes into several types: Inflammatory enlargement, which includes acute and chronic forms; drug-induced enlargement, associated with medications such as anticonvulsants like phenytoin, calcium channel blockers like verapamil and nifedipine, and immunosuppressants like cyclosporine; overgrowth associated with systemic diseases, including conditioned overgrowth due to factors like pregnancy, puberty, vitamin C deficiency, plasma cell gingivitis, nonspecific conditioned overgrowth like granuloma pyogenicum, and systemic diseases causing gingival overgrowth such as leukemia and granulomatous diseases like sarcoidosis, Crohn's disease, and Wegener's granulomatosis; neoplastic overgrowth, including both benign and malignant tumors affecting the gingiva; and False enlargements.<sup>2</sup>

Clinical presentations of gingival enlargement vary depending on the underlying cause. Genetically induced gingival enlargement typically appears pinkish in color with minimal signs of inflammation, exhibits a slow growth rate, and feels firm to the touch. On the other hand, soft, edematous, tender gingiva prone to bleeding may indicate blood disorders. In cases of leukemia, gingival enlargement results from the infiltration of premature leukocytes, serving as a common symptom aiding in the diagnosis of the disease and prompting dental consultation. It's crucial for dental professionals to be acquainted with the manifestations of systemic diseases, as many life-threatening conditions may initially present with oral lesions.<sup>3,4</sup>

Leukemia is a malignancy characterized by the excessive proliferation of abnormal white blood cells originating from the bone marrow. This proliferation disrupts the normal process of cell maturation, resulting in the accumulation of immature precursor cells (blasts) within the marrow. These blasts suppress the production of healthy blood cells, leading to deficiencies in mature leukocytes, erythrocytes, and platelets, which in turn cause immunodeficiency, anemia, and thrombocytopenia. Additionally, leukemic cells have the capacity to infiltrate various body tissues, including the skin, spleen, gingiva, lymph nodes, and central nervous system.<sup>4</sup>

The exact cause of leukemia remains unclear, though factors such as chemical injuries, chromosomal abnormalities, radiation exposure, and viral infections are implicated. Worldwide, leukemia affects approximately 3.7 per 100,000 individuals, with age-dependent mortality ranging from 2.7 to nearly 18 per

100,000 persons, and it contributes to about 4% of all malignancy-related deaths.<sup>5</sup>

Leukemia involves the uncontrolled proliferation of leukemic cells, which can infiltrate various tissues including the gingiva. In the case of gingival enlargement, leukemic cells accumulate within the gingival tissues.

The exact mechanism of gingival enlargement in leukemia is not fully understood but likely involves several factors: **Leukemic Cell Accumulation:** Leukemic cells infiltrate the gingival tissues, leading to their enlargement.

**Inflammatory Response:** The presence of leukemic cells triggers an inflammatory response in the gums, contributing to tissue swelling.

**Capillary Proliferation:** Leukemic cells can induce capillary proliferation and vascular changes in the gingiva, further contributing to tissue enlargement.

Oral manifestations of acute leukemia commonly include gingival swelling, oral ulceration, spontaneous gingival bleeding, petechiae, mucosal pallor, herpetic infections, and candidiasis. Acute myeloid leukemia (AML) is characterized by the clonal proliferation of immature myeloid cells, leading to marrow failure and cytopenia. Symptoms may include fever, fatigue, pallor, mucosal bleeding, petechiae, and localized infections.<sup>6</sup>

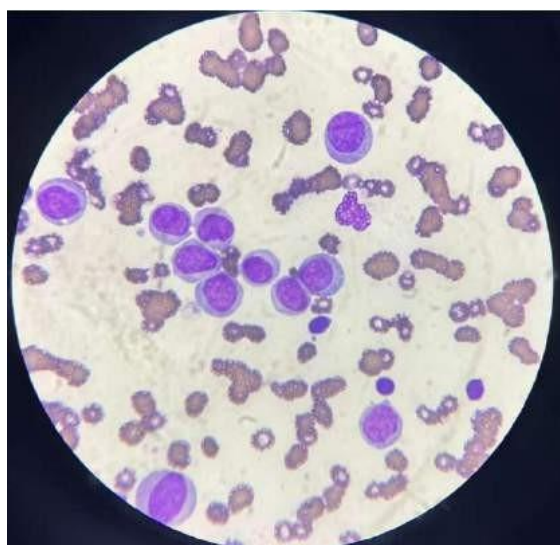
## II. Case Report

A 52-year-old male patient with low socioeconomic status by occupation painter reported in November 2023 to the Department of Oral Medicine and Radiology, Ranjeet Deshmukh Dental College and Research Center, Nagpur. The patient's chief complaints were the swollen gums since past 1 month. The patient had experienced difficulty in swallowing food, nausea, dizziness and weight loss in the past few months.

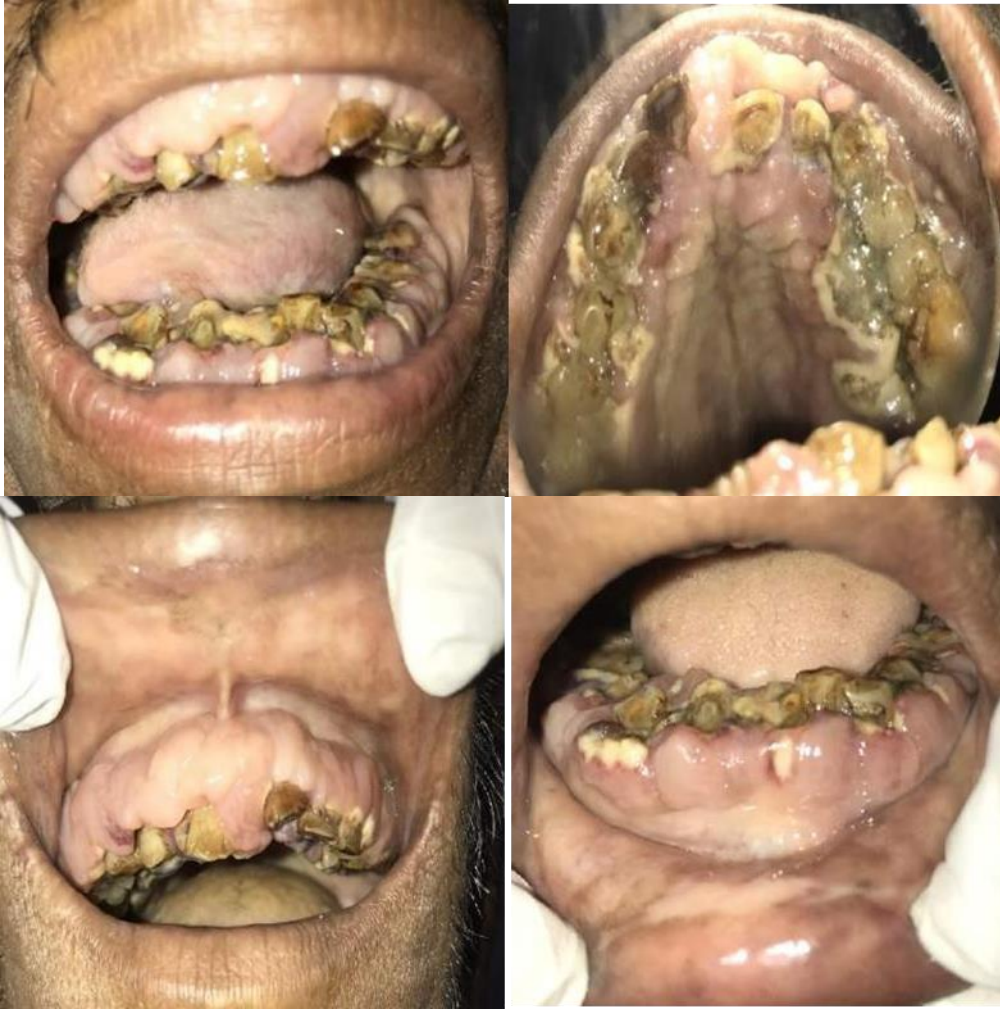On physical examination, marked pallor of the palpebral conjunctiva and cervical lymphadenopathy was observed.

Pallor of the buccal mucosa and gingiva was observed during oral examination. Gingival enlargement was seen in the buccal, labial, palatal, and lingual aspects of the maxillary and mandibular arches involving marginal and attached gingiva. Gingiva was firm, fibrous, lobulated and pale pink in color. In the posterior area, the growth reached the occlusal surface of the teeth. There was no bleeding on probing and tenderness was also not present on palpation. Generalized pseudo pockets were present. The orthopantomogram demonstrated generalized moderate to severe horizontal bone loss.

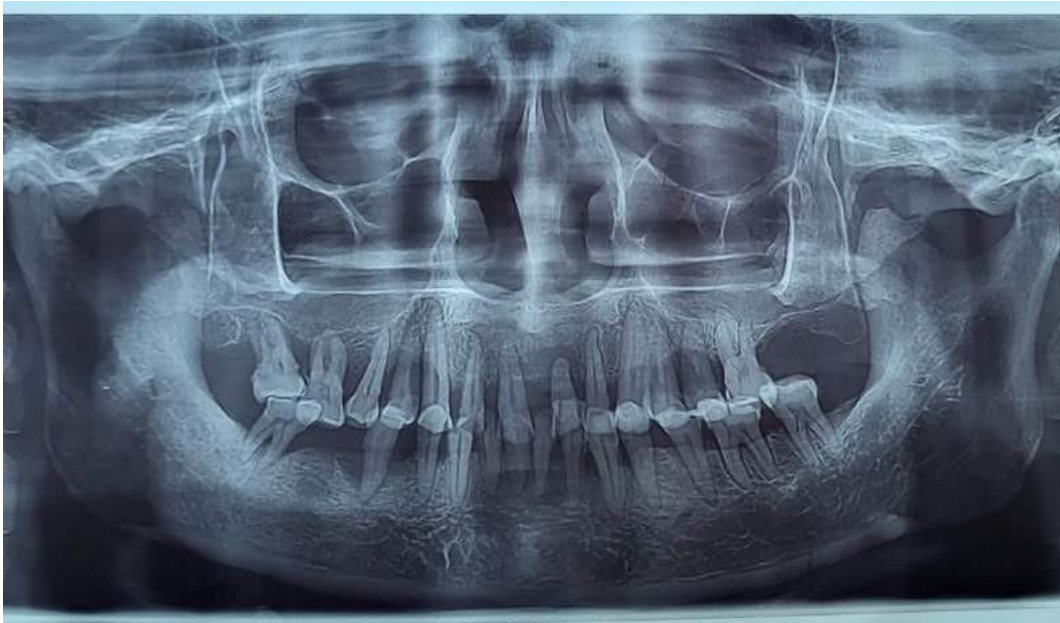
The complete blood count of the patient revealed leukocytosis (**1,13,000c/mm<sup>3</sup>**), thrombocytopenia (**34000/mm<sup>3</sup>**) and anemia (Hb **5.6 gm/dl**). Peripheral blood smear showed marked leukocytosis with numerous blast cells, cells showing granular cytoplasm & cytoplasmic vacuoles, lobulation of nuclei with 1 to 2 prominent nucleoli and cells showed indentation of nuclei which was suggestive of Acute Myeloid leukemia (AML) M5 (French American British Classification).



**Peripheral Blood Smear Leishman Stain (100x)**



**Image Showing Generalised Gingival Enlargement In Patient**



**Opg Of Patient Showing Generalised Moderate Horizontal Bone Loss**

The patient was advised to maintain oral hygiene after complete oral prophylaxis, and the patient was referred to Oral pathology for further blood investigations like CBC. However before any treatment could be done the patient died 2 days later.

### **III. Discussion:**

Leukemia is cancer that starts in blood-forming tissue such as the bone marrow and causes large numbers of abnormal blood cells to be produced and enter the bloodstream.

Leukemias are broadly classified as:

Based on Histogenesis

- Lymphocytic / Lymphoblastic
- Myeloid

Based on Clinical Behavior

- Acute
- Chronic

They are abrupt in onset, if untreated, become fatal in nature.

Acute monocytic leukemia accounts for 3–6% of all AML cases. AML is more frequent in elderly persons and among males than in women. AML is a very uncommon illness.

Swollen gingiva, ulceration, spontaneous gingival bleeding, petechiae, pale mucosa, and infections were among the most frequently reported symptoms of the condition. Other oral manifestations described less often included hemorrhagic bullae on the tongue, split lips, parotid edema, palatal pigmentation, tooth discomfort, and movement.

There has been no evidence of leukemic gingival infiltration in edentulous people, indicating that local irritation and trauma may play a role in pathophysiology. According to reports, gingival results are partially dependent on tissue inflammation. Patients with poor oral hygiene are more likely to have oral discomfort, bleeding, superinfections, and tissue necrosis. <sup>1,2</sup>

There has been no evidence of leukemic gingival infiltration in edentulous people, indicating that local irritation and trauma may play a role in pathophysiology. <sup>1,2</sup>

This instance highlights the need of oral health providers being aware of the oral symptoms of systemic disorders. Acute leukemia frequently leads patients to seek dental care first, making dentists accountable for starting the diagnosis in 25%-33% of AML cases. To help in early diagnosis and subsequent early management, the dental practitioner must clearly recognize the pathology and thoroughly research it by ordering additional tests or sending the patient to a higher level of care. <sup>1,2</sup>

### **IV. Conclusion:**

In this case, the patient was initially given differential diagnosis of leukemic gingival enlargement and idiopathic gingival enlargement based solely on oral manifestations and lymph node examination. While the initial hospital assessments did not confirm the diagnosis, a visit to RRDC RC Nagpur resulted in blood investigations revealing the final diagnosis of leukemic gingival enlargement. Undertaking local periodontal therapy without a proper diagnosis is unjustified in such cases and could potentially lead to severe complications. Therefore, it is crucial for dental surgeons and specialists in oral medicine to recognize the systemic origins of gingival enlargement, gather comprehensive medical history, conduct thorough general and oral examinations, and perform appropriate investigations to establish an accurate diagnosis. Timely referral is essential to prevent life-threatening complications.

### **References:**

- [1] Hasan S, Khan Ni, Reddy Lb. Leukemic Gingival Enlargement: Report Of A Rare Case With Review Of Literature. *Int J Appl Basic Med Res.* 2015 Jan-Apr;5(1):65-7. Doi: 10.4103/2229-516x.149251. Pmid: 25664273; Pmcid: Pmc4318106.
- [2] Chowdhri K, Tandon S, Lamba Ak, Faraz F. Leukemic Gingival Enlargement: A Case Report And Review Of Literature. *J Oral Maxillofac Pathol.* 2018 Jan;22(Suppl 1):S77-S81. Doi: 10.4103/Jomfp.Jomfp\_205\_17. Pmid: 29491612; Pmcid: Pmc5824525.
- [3] Menezes L, Rao Jr. Acute Myelomonocytic Leukemia Presenting With Gingival Enlargement As The Only Clinical Manifestation. *J Indian Soc Periodontol.* 2012;16:597–601.
- [4] Carranza Fa, Hogan El. Gingival Enlargement. In: Newman Mg, Takei Hh, Carranza Fa, Editors. *Clinical Periodontology.* 10th Ed. Philadelphia: Wb Saunders Co; 2002. Pp. 279–96.
- [5] Demirer S, Ozdemir H, Sencan M, Marakoglu I. Gingival Hyperplasia As An Early Diagnostic Oral Manifestation In Acute Monocytic Leukemia: A Case Report. *Eur J Dent.* 2007;1:111–4.
- [6] Chavan M, Subramaniam A, Jhaveri H, Khedkar S, Durkar S, Agarwal A. Acute Myeloid Leukemia: A Case Report With Palatal And Lingual Gingival Alterations. *Braz J Oral Sci.* 2010;9:67–9.