

## Management Of Open Apex: BioRoot Inlay Versus Thermoplastized Condensation – Case Report

Reshma P Babu<sup>1</sup>, Deepak Baby<sup>2</sup>, Sreedevi P V<sup>3</sup>, Ann Mary Augustine<sup>4</sup>, Arunima B<sup>5</sup>

<sup>1</sup>Dept. Of Conservative Dentistry & Endodontics, P S M Dental College, India

<sup>2</sup>Dept. Of Conservative Dentistry & Endodontics, P S M Dental College, India

<sup>3</sup>Dept. Of Conservative Dentistry & Endodontics, P S M Dental College, India

<sup>4</sup>Dept. Of Conservative Dentistry & Endodontics, P S M Dental College, India

<sup>5</sup>Dept. Of Conservative Dentistry & Endodontics, P S M Dental College, India

---

### Abstract:

A sixteen year old boy was presented with esthetic concerns in his upper anterior teeth. On clinical examination both the maxillary central incisor revealed fracture of the crown. Radiographic evaluation revealed open apex of both central incisors. Apexification with Biodentine was carried out in two different methods as BioRoot inlay and thermoplastized condensation. In six months follow up both the tooth were clinically and radiographically asymptomatic.

**Key Word:** Open apex, Trauma, Apexification, BioRoot inlay, Thermoplastized condensation, Biodentine

---

Date of Submission: 14-04-2024

Date of Acceptance: 24-04-2024

---

### I. Introduction

The development of a tooth begins with the formation of the crown, followed by root structure. At the time of tooth eruption, root formation is still incomplete, and takes up to three years for completion<sup>1</sup>. If the normal growth and development of the root structure is disrupted by trauma or caries, this can result in open apices. These traumatic dental injuries are more common in children and adolescents<sup>1</sup> aged 7 to 12 years<sup>2</sup> resulting in pulpal necrosis<sup>1</sup>. It is most common in the maxillary anterior region of the mouth<sup>3</sup>.


The treatment options of immature permanent tooth are as follows: If the condition is reversible pulpitis, apexogenesis is performed and if the condition is irreversible pulpitis, apexification or pulp regeneration is performed. Calcium hydroxide, Mineral Trioxide Aggregate (MTA), or Biodentine, resorbable ceramic, Freeze-dried cortical bone, Freeze-dried dentin, dentinal shavings, Bone Morphogenetic Protein are used for apexification<sup>1,4</sup>. This clinical case report demonstrates successful apexification with Biodentine in asymptomatic young permanent teeth #11 and #21 with two different methods.

### II. Case History:

A sixteen years old male patient with non-contributory medical history, reported to the Department of Conservative Dentistry and Endodontics, with the chief complaint of aesthetic concerns in his maxillary anterior region. Dental history revealed previous history of trauma at the age of seven years. Clinical examination revealed #11 with Ellis class II fracture and #21 with Ellis class II fracture. There was no pain on palpation, tenderness to percussion, or sinus tract. Intra oral periapical radiograph revealed a large blunderbuss canal with associated periapical lesion in relation to #11 and #21 which was diagnosed as chronic apical periodontitis. The patient was given a detailed explanation concerning the treatment and prognosis. Informed consent was obtained from the patient.

Apexification was planned using Biodentine for both central incisors followed by obturation with custom made prefabricated BioRoot inlay in #11 and obturation with thermoplasticized gutta-percha for #21. Local anesthetic was administered using 1 cartridge 1.8 mL 2% lidocaine HCl. Rubber dam isolation was done. The working length was established at 19.5mm for #11 and 19 mm for #21 using #80 K file and was confirmed using digital radiograph. Gentle cleaning and shaping was done in a circumferential manner upto #140 K file. Root canal debridement was done following irrigation protocol consisting of 3% sodium hypochlorite and sterile saline using side vented irrigation needle (NeoEndo). Following irrigation, canals were dried with paper points, calcium hydroxide was placed as an intracanal medicament and secured with a cotton pellet and temporary restoration. In the subsequent appointment after a week both tooth was asymptomatic. After removal of the temporary

restoration, calcium hydroxide dressing was removed by irrigating with 3% sodium hypochlorite and sterile saline and final irrigation was done with 2% Chlorhexidine. [Figure1]



(A) Preoperative radiograph of Ellis class II fracture in # 11 and Ellis class I fracture in # 21

(B) Working length determined

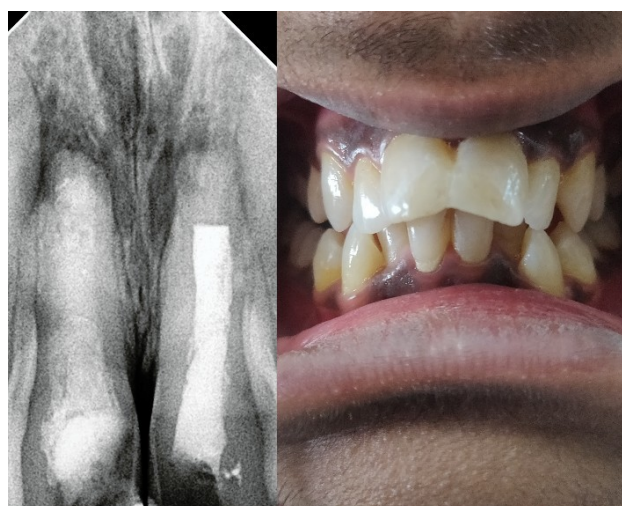(C)The light body impression of the root canal space

(D,E) BioRoot inlay

(F) #11, BioRoot inlay along with a bio ceramic sealer obturation and #21, obturated with thermoplasticized gutta-percha and bio ceramic sealer

In #11 after drying the canal with paper point light body impression of the root canal space was made with elastomeric impression material (GC Flexceed Light Body (Standalone) Impression Material) followed by placing it in a putty impression (Zhermack Elite Hd+ Soft putty Body). Putty impression was split into two halves to aid in retrieving Biodentine as a single plug. After stabilizing the putty mix, a thick mix of Biodentine was prepared and carried with a carrier into the root canal space within the impression and was compacted with a plugger. The root inlay was allowed to set for 12 minutes. After 12 minutes BioRoot inlay was removed and tried in and was confirmed by digital radiograph. BioRoot inlay along with a bio ceramic sealer (Pro Root MTA sealer) was used to obturate the root canal space and was confirmed by a postoperative radiograph. The access cavity was then restored with glass ionomer cement (GIC).

In #21 after drying the canal, Biodentine was mixed according to the manufacturer's instructions and condensed incrementally into the canal to create apical plug. Subsequent increments were condensed against the wall with a prefitted hand plugger until the thickness was confirmed radiographically to be 4 mm. After placing Biodentine, the butt end of a paper point was used to remove any excess material from the walls. After 12 minutes, the hardness of the Biodentine was examined using a plugger to confirm its set. The remainder of canal was backfilled with injection- moulded thermoplasticized gutta percha (Calamus Dual, DENTSPLY) and bio ceramic sealer (Pro Root MTA sealer). The access cavity was then restored with GIC. Patient was recalled after six months. [Figure 2]



[A, B] Six months follow up

### III. Discussion:

Apexification is a procedure promoting the formation of a barrier that closes the open apex of an immature permanent tooth with a non-vital pulp so that the filling materials are contained within the root canal space (Farhad and Mohammadi, 2005).

In order to overcome the disadvantages of various management options for open apex an innovative approach of BioRoot inlay was used in #11. BioRoot inlay is an intraradicular custom made prefabricated restoration that provides a three dimensional seal of the root canal space and reinforces the formation of an apical barrier in conjunction with the bio ceramic sealer. The sealer aids in the sealing of minor discrepancies between the core and the root, resulting in a three dimensional seal and good periradicular bone healing. Biodentine, a new bioactive dentin substitute cement is made up of tricalcium silicate, dicalcium silicate, calcium carbonate, calcium oxide, zirconium oxide, and calcium hydroxide. It takes less than 12 minutes to set<sup>5</sup>. The benefits of Biodentine includes it does not stain teeth, micromechanical bonding, which eliminates the need for surface preparation, and that its microleakage resistance is enhanced by the absence of shrinkage due to the resin-free formulation and the material's biocompatibility<sup>6</sup>. Zanini et al suggested that Biodentine is bioactive because it induces differentiation of odontoblast-like cells and increases murine pulp cell proliferation and biomineralization.

In #21 the apexification with Biodentine as an apical plug followed by thermoplasticized gutta percha because of its improved flow properties it can be moved more easily into the irregularities of the canals, mimicking the complexity of the root canal system, and fill root canals more quickly than lateral condensation. This method takes less time and is less expensive than the BioRoot inlay apexification method. However, biodentine is more expensive than calcium hydroxide.

In comparing the strength of two methods BioRoot inlay has greater strength than thermoplasticized gutta-percha and has dentin like properties<sup>7</sup>. So it will strengthen the weakened tooth structure by improving the fracture resistance. Both cases were asymptomatic during the 6 months' follow-up period, but long-term evaluation is required to assess the efficacy in microleakage and durability.

### IV. Conclusion

In conclusion, the present case shows that apexification with Bioroot inlay and the thermoplasticized guttapercha, despite being two different protocols, have a common objective of treating the necrotic immature permanent tooth. Indeed, the therapeutic decision depends on the clinical situation, the desired results of the treatment, and the performance and dexterity of the dentist.

### References

- [1] Ravindran V, Jeevanandan G, Marimuthu M, Et Al. Comparison Of Mineral Trioxide Aggregate And Biodentine For Open Apex Management In Children With Nonvital Immature Permanent Teeth: A Systematic Review. *European Journal Of General Dentistry*. 2022;11(2):84-93
- [2] Andreasen Jo, Ravn Jj. Epidemiology Of Traumatic Dental Injuries To Primary And Permanent Teeth In A Danish Population Sample, *Int J Oral Surg* 1972;1: 235.
- [3] Bastone Eb, Freer Tj, Mcnamara Jr. Epidemiology Of Dental Trauma: A Review Of The Literature, *Aust Dent J* 2000;45: 2.
- [4] Ravindranath Megha1 , Newbegin Selvakumar Gold Pearlina Mary2 , Arumugam Karthick3 , Paramasivam Vivekanandhan3. (2020). Diagnosis And Treatment Modalities Of Open Apex – A Review. *Indian Journal Of Forensic Medicine & Toxicology*, 14(4), 1380–1384.
- [5] Villat C, Grosgeat B, Seux D, Farge P. Conservative Approach Of A Symptomatic Carious Immature Permanent Tooth Using A Tricalcium Silicate Cement (Biodentine): A Case Report. *Restor Dent Endod*. 2013;38(4):258–62. Doi:10.5395/Rde.2013.38.4.258.
- [6] Nazar F, Nair Kr, Praveena G, Anilkumar A, Rajendran R. Single-Visit Apexification Using Biodentin. *Cons Dent Endod J* 2017;2(1):40-42.
- [7] Mal Kon Du, Ö., Ka Zan Da Ğ, Mk And Kazazođl U, P., (20 14) .A Review Of Biodentine, A Contemporary Dentine Replacement And Repair Material. *Biomed Res Int*. 2014:160951.