

Ovarian Choriocarcinoma In Girls

N.Boumahdi ; A.Boutahar ; O.Alaoui ; A.Mahmoudi ; K.Khattala ;
Y.Bouabdallah

Department Of Pediatric Surgery, Hassan Ii University Hospital, Fès, Morocco

Date of Submission: 21-05-2024

Date of Acceptance: 31-05-2024

I. Introduction :

Infantile choriocarcinoma is an exceptional and poorly understood malignant trophoblastic tumour that can occur in the neonatal period. It is most often due to the transmission to the newborn of metastases from a placental choriocarcinoma. The organs most frequently invaded are the liver (90%, 29 cases) and the lungs (60%, 19 cases). Other organs more rarely affected include the ovary.

The origin of ovarian choriocarcinoma is either gestational or non-gestational. Gestational ovarian choriocarcinomas (GOCC) are more common [3,4]. Non-gestational choriocarcinomas (NGC) are rare in their pure form. They are often associated with other germ cell tumours such as immature teratomas, dysgerminomas and embryonal carcinomas because their embryological origin is identical [3].

Ovarian choriocarcinomas are malignant germ cell tumours. They are defined by the presence of malignant cells, both cyto- and syncytiotrophoblastic, which are closely intertwined and have no associated villous formation [1,2].

II. Observation :

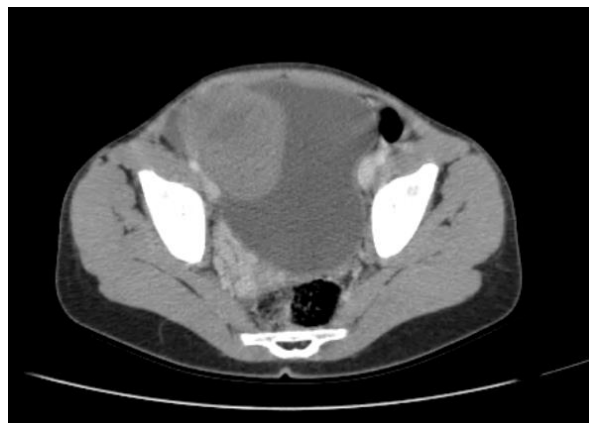The patient was 9 years old and had suffered from appendicitis 6 months previously. She was admitted with an abdominopelvic mass which was fixed deep in the left flank, measuring 13*11 cm in diameter, with diffuse abdominal tenderness, and had been evolving for 2 months in a context of apyrexia and preservation of her general condition

Radiological findings :

Abdominal ultrasound: Large solid cystic abdomino-pelvic tumour with regular contours and heterogeneous echostructure, taking colour Doppler.

CAT scan: large latero- and supravescical tumour mass measuring 145*87*153 mm, raising suspicion of an ovarian mass.

There were no other suspicious abnormalities on the other floors.



MRI : Large, well-limited, encapsulated, intraperitoneal, supravescical and left latero-uterine, solid cystic mass with T2-hyposignal wall, diffusion-restricted peripheral tissue portion and non contrast-enhanced, containing heterogeneous cystic areas, some of which are fluid and some of which are T1-hypersignal, measuring 125 x 75 x 125 mm (T x AP x H).

Topographically, this mass has the following relationships:

- Anteriorly: in contact with the anterior abdominal wall.
- Externally: it pushes the left colon posteriorly.
- medially: it comes into contact with some of the small intestines on the right, with no signs of invasion.
- Posteriorly: it comes into contact with the abdominal aorta and its bifurcation, creating a mass effect on the left iliac ureter, causing moderate upstream DUPC with a pyelone measuring 18 mm.

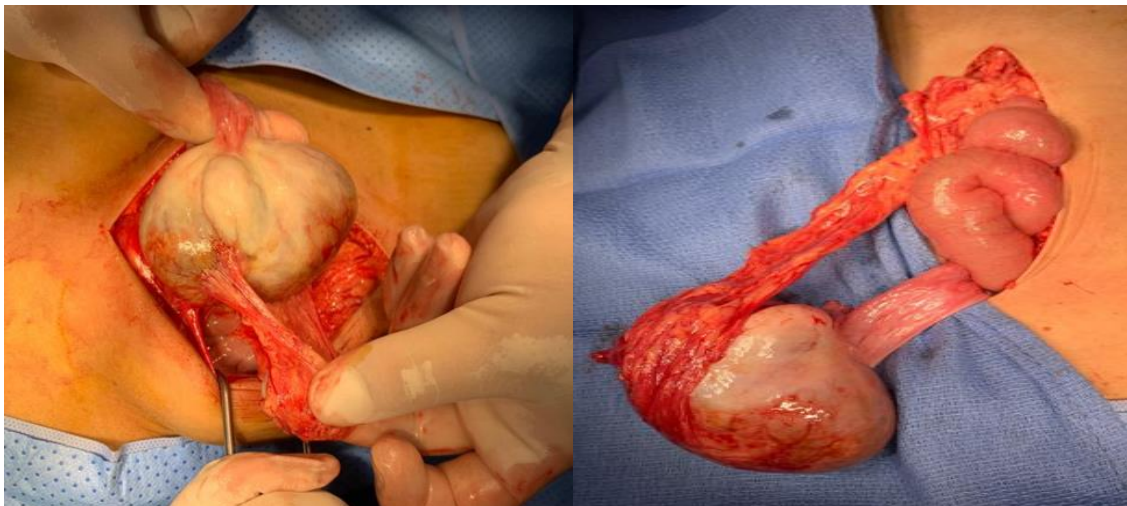
Biological findings :

CBC: Anaemia 8.3 VGM: 79 CCMH: 33
WBC 11600 PNN 9500 lym 1000 Mono 730
Platelets: 450,000
Renal and haemostasis tests normal CRP: 118
ALPHA fetoprotein normal 0.901 ng/ml
Beta HCG elevated to 25428
LDH elevated to 1200
Metabolic and tumour lysis panels normal

At the end of this work-up, it was found to be a non-metastatic right ovarian germ cell tumour, and was treated according to the TGM 95 protocol, with a good response to treatment after 6 sessions of chemotherapy. Regression of tumour size on control CT from 8*6 cm to 14*9*15 cm. With a BHCG level of less than 2.

The patient was then scheduled for right salpingo-oophorectomy.

Intraoperative examination revealed a 7 cm mass over the right ovary, involving the entire ovary and adherent to the greater omentum, with a small contralateral ovary. Right adnexectomy was performed.



Pathology of the surgical specimen was consistent with non-metastatic right ovarian choriocarcinoma.

III. Discussion :

The origin of childhood choriocarcinoma remains uncertain. When choriocarcinoma appears in the neonatal period or in a young infant, it is accepted that it is the result of the transmission of a placental tumour developed during pregnancy. Gestational choriocarcinoma follows hydatidiform mole in a third of cases.

Ovarian choriocarcinoma is a rare and aggressive tumour that forms from the cells that produce the placenta during pregnancy. Although it is more common for this type of tumour to develop in the placenta during pregnancy, it can sometimes develop in the ovaries, even in women who are not pregnant.

Ovarian choriocarcinoma is a rare form of ovarian cancer, but it is generally more aggressive than other types of ovarian cancer.

Symptoms of ovarian choriocarcinoma may include abnormal vaginal bleeding, pelvic pain, enlargement of the abdomen, nausea and vomiting.

Diagnosis of ovarian choriocarcinoma often involves a combination of medical imaging (such as ultrasounds and scans), blood tests to measure levels of certain hormones and sometimes a biopsy to confirm the type of cancer cells.

Treatment for ovarian choriocarcinoma may include surgery to remove the tumour, chemotherapy and, in some cases, radiotherapy. The choice of treatment often depends on factors such as the size of the tumour, the stage of the cancer and the patient's general health.

The prognosis for ovarian choriocarcinoma depends on a number of factors, including the stage of the cancer at diagnosis and the response to treatment. As it is an aggressive cancer, early diagnosis and prompt treatment are important to improve the chances of survival.

IV. Conclusion :

Ovarian choriocarcinoma remains an exceptional malignant germ cell tumour that deserves to be recognised as potentially curable.

Treatment is based on chemotherapy combined with surgery to remove the tumour.

In both children and mothers, the tumour appears to be extremely chemosensitive, and its poor prognosis often seems to be linked to delayed diagnosis and treatment.

Follow-up of the mother is important, as she may also develop a choriocarcinoma in the months following the discovery of the child's choriocarcinoma.

References :

- [1] Norris Jh, O'connor Md. "Pathology Of Malignant Germ Cell Tumors Of The Ovary". Second Edition. In: Copleson M, Editor. "Gynaecologic Oncology". Hong Kong: Longman Group (Fe) Ltd; 1992.
- [2] Vance Rp, Geisinger Kr. Pure Non-Gestational Choriocarcinoma Of The Ovary: Report Of Case. *Cancer* 1985;56(9):2321.
- [3] Simsek T, Track B, Karaveli M, Uner M, Sonmez C. Primary Pure Choriocarcinoma Of The Ovary In Reproductive Ages: A Case Report. *Eur J Oncol* 1998;19(3):284-6.
- [4] Heath Ja, Tiedemann K. Successful Management Of Neonatal Choriocarcinoma. *Med Pediatr Oncol* 2001;36:497-9.
- [5] Kalifa C, Brule F, Baillif P, Et Al. Métastases Chez Un Nourrisson D'un Choriocarcinome Placentaire. *Arch Fr Pediatr* 1981;38:351-2.
- [6] Avril Mf, Mathieu A, Kalifa C, Et Al. Infantile Choriocarcinoma With Cutaneous Tumors. An Additional Case And Review Of The Literature. *J Am Acad Dermatol* 1986;14:918-27.
- [7] Kruseman Ac, Van Lent M, Blom Ah, Et Al. Choriocarcinoma In Mother And Child, Identified By Immunoenzyme Histochemistry. *Am J Clin Pathol* 1977;67:279-83.
- [8] Tsukamoto N, Matsumura M, Matsukuma K, Et Al. Choriocarcinoma In Mother And Fetus. *Gynecol Oncol* 1986;24:113-9