

# Maxillary Distraction Osteogenesis Versus Conventional Orthognathic Surgery In Cleft Lip And Palate Patients

Alia Eid<sup>1</sup>, Ranad Ahmed<sup>1</sup>, Mahmoud Yehia<sup>1</sup>, Salah Abdelfattah<sup>1</sup>

Department Of Oral And Maxillofacial Surgery, Faculty Of Dentistry, Ainshams University, Egypt.

---

## Abstract:

### Background:

Cleft lip and palate (CLP) is the most common congenital anomalies. CLP patients need multiple surgeries to correct these deformities to achieve function and esthetic needs. As a result of these surgeries, CLP individuals suffer from midface hypoplasia. The correction of maxillary hypoplasia is by conventional orthognathic or maxillary distraction osteogenesis.

**Materials and Methods:** This review of literature is based on searches through main databases included Pubmed, Sciencedirect and Scopus. Also, through grey literature EKB, Google Scholar to expand our search. We used searching keywords include cleft lip and palate, conventional orthognathic surgery, maxillary distraction osteogenesis connected with Boolean operators OR, AND.

The review aimed to discuss the characteristics features of CLP individuals and the challenges that face oral and maxillofacial surgeon to decision making to correct the maxillary hypoplasia between both techniques maxillary distraction osteogenesis DO and conventional orthognathic surgery CO.

**Conclusion:** Based on the previous literatures there is no strong evidence that support which orthognathic technique is better than other for CLP patients. However, it is important to consider the key factors for a successful CO for its merits. DO offers an alternative option for difficult CLP cases.

**Keyword:** cleft lip and palate, cleft non syndromic patients, conventional osteotomy le fort I, maxillary distraction osteogenesis, stability and relapse, speech, velopharyngeal incompetence, soft tissue changes, morbidity and blood supply.

---

Date of Submission: 07-05-2024

Date of Acceptance: 17-05-2024

---

Orofacial cleft (OFC) is the most common deformity that affect 1 to 7 out of 1,000 live births globally(1). Nonsyndromic cleft individuals, of average 93-95% of all OFC cases, are the most common form(2).

Cleft lip affects more males than females, with a ratio of 2:1. However, cleft palate alone is more prevalent in females. Within CLP, unilateral cleft lip and palate (UCLP) is more common than bilateral cleft lip and palate (BCLP).

The incidence of cleft lip with or without cleft palate (CL/P) is 1 in 1,000 births, while isolated cleft palate (ICP) occurs at a rate of 1 in 2,500 births(3)(4).

The comprehensive care of CLP individuals involves a multidisciplinary team of specialists and a detailed clinical protocol for evaluation and definitive treatment. The multidisciplinary team responsible for their care typically includes specialists in oromaxillofacial surgery, otolaryngology, speech-language pathology, dental subspecialties (prosthodontics, orthodontics, periodontics), general pediatrics, pediatric subspecialties, genetics, and a team coordinator to facilitate interdisciplinary communication(5).

## I. The Problems That Associated With CLP:

CLP individuals may develop maxillary hypoplasia either due to intrinsic growth potential factors within the maxilla such as developmental deformities, genetic predispositions, and iatrogenic influences. Or from extrinsic factors that result from the previous surgical interventions to correct the CLP problems, these interventions produce extensive scar tissue that affect the maxillary growth(6).

### Characteristics of individuals with CLP:

#### Maxillary Hypoplasia:

The severity of maxillary hypoplasia correlates with the specific type of cleft. In unilateral (UCLP) cases, the maxillary lesser segment is commonly hypoplastic and displaced in a superior, posterior, and medial direction. the maxillary midline tends to deviate toward the cleft side(7)(8).

Bilateral (BCLP) cases, narrow maxilla due to the medial collapse of posterior alveolar segments with bilateral posterior cross bite. the premaxilla may be positioned either superiorly or inferiorly, frequently protruding(7)(8).

## **2. Typical Facial Characteristics:**

CLP patients exhibit concave mid-face hypoplasia involving infraorbital, zygomatic, maxillary, and alveolar areas. This concavity is accompanied by relative mandibular protrusion(9).

## **3. Congenital missing tooth in the alveolar cleft:**

Missing tooth usually lateral or canine depending on alveolar cleft site. The absence of teeth within the alveolar cleft presents challenges in terms of dental arch alignment and occlusion(10).

## **4. Residual problems:**

These bony defects and residual oronasal fistulas in CLP patients are potential complications of cleft palate repair(11–13).

### **a. Bony Defect:**

The bony defect is primarily located in the hard palate region specifically in the nasal floor that gives rise to specific clinical consequences. In UCLP, it leads to inferior displacement of the nasal floor and deviation of anterior nasal spine and nasal septum toward the cleft side. In BCLP, the absence of alveolar bone continuity cause the premaxilla mobile and attached only to the nasal septum and adjacent labial soft tissue.

### **b. Residual Oronasal Fistula (ONF):**

Residual ONFs is considered as a potential problem after alveolar bone graft (ABG), it is characterized by incomplete closure of the palatal soft tissue and communication between oral and nasal cavities.

The multiple attempts to close the ONF resulted in dense scar tissue of the palate, this scar tissue complicates subsequent surgical interventions to close the fistula with the deficient palatal tissue and vascular interruption.

## **5. Muscular dysfunction:**

The prolonged dental malocclusion in CLP patient including posterior crossbites in UCLP and BCLP, the patient has to increase the chewing cycles numbers to compensate for the improper mastication. This compensatory mechanism has a great influence on muscles of mastication especially temporalis and masseter muscle as they are associated with elevated electromyographic (EMG)(14)(15).

The primary lip repair produces labial scar tissue that affects the orbicularis oris muscle, also the CLP patient may have prolonged openbite this affect the muscle tension and consequently the lip seal(16).

## **6. Velopharyngeal insufficiency (VPI):**

VPI is a common concern in CLP patients, it results from anatomical defect of the improper closure of the velopharyngeal (VP) valve. The velopharyngeal anatomical defect of the improper closure of the velopharyngeal valve gap increase between the soft palate and the pharyngeal walls causes hypernasality and nasal rustle through air escapement(17).

It is important to consider the correlation between speech problems and the velopharyngeal gap, some individuals can develop a compensatory mechanism to overcome these alterations in the VP anatomical patterns. The role of speech assessment alone can predict the VP gap size(17).

## **7. Speech deterioration:**

Normal speech development in children is a multifaceted process that relies on inherent language abilities, auditory perception, VP function, articulatory proficiency, oral motor coordination, and the configuration of the vocal tract fig.1. The resonance and articulation assessment play an important role in orthognathic surgery (OGS)(18)(19).

The deformities of the maxilla in CLP patients develop a poor articulation speech through the narrow maxilla, tongue, lips and dental malocclusion. The impaired resonance speech is due to improper VP gap seal that causes hypernasality(18). Figure 1

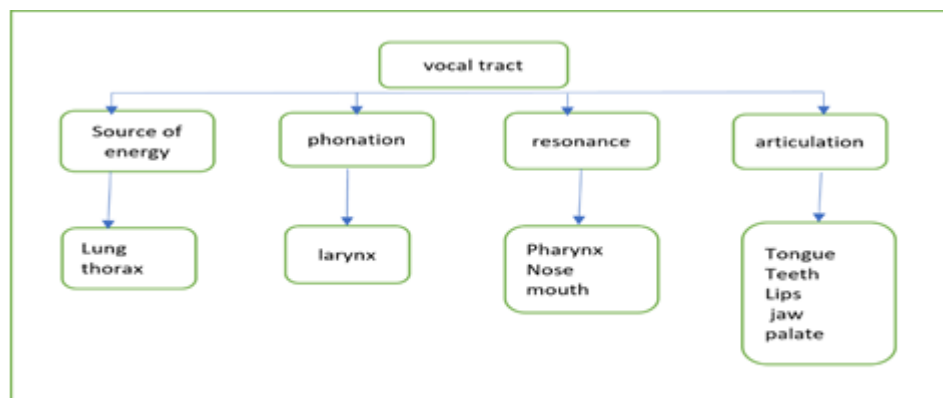


Figure 1 vocal tract structure.

### 8. Nasal obstruction:

CLP patients may exhibit enlarged inferior turbinates and deviated nasal septum, this results in prolonged mouth breathing and consequently anterior open bite(10).

### 9. Mandibular distortion:

The maxilla and the mandible grow in a harmony with each other, so the maxillary prolonged deformities in CLP patients can affect the mandible as anterior open bite with a steep mandibular plane angle due to prolonged mouth breathing, this may increase the anterior facial height. Skeletal asymmetry and deviated occlusal cant due to narrow maxilla and posterior crossbite(9,10).

### 10. Chin deformity:

Prolonged nasal obstruction and mouth breathing result in excess vertical length and retruded chin. The correction of CLP maxillary hypoplasia is done through conventional orthognathic surgery or maxillary distraction osteogenesis(10).

## II. Management With Conventional Orthognathic Surgery (CO):

Maxillary orthognathic surgery is a surgical procedure that involves a precise repositioning of the maxilla in optimal placement within the craniofacial structure through surgical bone osteotomies and rigid fixation to obtain function and esthetic needs(20).

CLP individuals of range 25% to 60% may require (OGS) because of the previous surgical operations that result in dense scar tissue that causes narrow maxilla(10).

The patient can benefit from CO, it allows the correction of enlarged nasal turbinates, maxillary hypoplasia and the 2ry mandibular deformities all simultaneously in one operation, predictable intraoperative results and in short span treatment(21).

Before proceeding with OGS, five key factors should be assessed. These factors include documenting the patient's language characteristics, evaluating velopharyngeal function, assessing jaw movements, considering the need for a pharyngeal flap, and identifying any potential risks in the postoperative period. It is essential to evaluate the movement of the mandible and maxilla preoperatively and anticipate probable changes in their relationships to other oral structures following surgery. While precise predictions of postoperative relationships are challenging, making estimates can help in counseling patients regarding potential speech-related effects(18).

Speech-language pathologists (SLPs) play a crucial role within cleft palate and craniofacial multidisciplinary teams, primarily to observe and assess the vocal tract, aiming to optimize speech outcomes. They should thoroughly document a patient's speech and language status both before and after OGS as part of their comprehensive evaluation and support(18).

However, to obtain a successful OGS with optimal results mainly for stability and relapse, there 4 main key factors that should be considered for CLP patients:

## III. Total Free Mobility Of The Maxilla:

Posnick 2006 (10) stated that total mobilization of the maxilla intraoperative ie. 10-15 min. is the most important factor to achieve less relapse rate. Philips 2012(9) stated that the maxillary segment advancement that are more than 10 mm requires passive mobility up to 30 mins intraoperatively and it may require bone trimming around the greater palatine artery in order to achieve a secure and safe movement in respect to blood supply.

**Type and severity of the cleft:**

BCLP could have a higher relapse rate because of the need of higher maxillary advancement in both AP and vertical dimension.

Mobilization in BCLP is technically difficult as it is important to ensure the vascular blood supply of the premaxilla, multiple residual problems i.e. previous surgical scar, alveolar bone defects, muscle pull and function of lip, malocclusion problems(10,22).

**Amount of advancement**

There is no single reason for skeletal relapse, some investigators considered that the relapse rate is correlated with the amount of maxillary advancement in AP and vertical D while others found that relapse is not related to the extent of surgical movement in either direction(23).

**Previous scar tissue:**

The most important factor to predict relapse rate and degree of difficulty of surgery is the scar and quality of palatal tissue(24).

**Muscular effect:**

Most of CLP individuals need to increase maxilla in vertical and AP dimensions as the maxilla moves downward it will affect the posterior mandibular height to increase, this causes excessive stretch in mandibular sling and tend to increase the force that act on maxilla cause increase in relapse rate(25).

Finn et al(26) found that CLP patients with vertical maxillary deficiency have high bite forces which results in high compressive forces that is responsible in relapse in the vertical direction.

Throckmorton (27)presented a biomechanical model that describe the action of muscle when the maxilla is inferiorly positioned and concluded that the muscle increased in action that result in increase in force that act on maxilla.

**Vascularity:**

During maxillary surgery, the blood vessels most vulnerable to iatrogenic injury include the internal maxillary artery, posterior superior alveolar artery, and descending palatine arteries(28).

The main vascular supply to the mobilized Le Fort I maxillary segment comes from the ascending palatine branch of the facial artery and the anterior branch of the ascending pharyngeal artery within the palatal soft tissue pedicle. There is also a rich mucosal alveolar anastomotic network overlying the maxilla (29).

Maxillary fractures that are not under control may result in high or low fractures that can lead to injury to the base of the skull or the maxillary alveolus. Such fractures can potentially cause vascular injuries either directly during osteotomy to branches of the maxillary artery or indirectly through the shattered pterygoid plate bone affecting the descending palatine vessels and pterygoid venous plexus(30).

For these factors, the decision for conventional orthognathic for CLP patients is considered challenging. Most of surgeons choose maxillary distraction osteogenesis for its main advantage, no need for a complete free mobility of the maxilla because the force of the device is strong enough to move the most recalcitrant maxilla that have dense scar tissue also it need minimal tissue dissection so there is minimal vascular compromise and the risk of unfavorable LF1 fracture is decreased with less risk for injury to descending palatine artery.

There are types for maxillary distraction osteogenesis (DO) for each has merits and demerits. Table 1.

RED (rigid external distractor)	Palatal distractor	Trans-sinusoidal distractor
The need for bone grafting at the osteotomy sites is eliminated, decreasing both surgical time and doner site morbidity(31).		
DO has the ability to mobilize even most recalcitrant maxilla through gradual stretching reduce stress operation for surgeon due to intraoperative maxillary mobilization(32).		
DO has limited ability to correct all cleft deformities i.e fistula, bony defects, dental gaps, nasal obstruction(33).		
Although DO is a safe and recognized method for advancements of the maxilla there are obvious drawbacks to consider. Once a uni-vectorial internal appliance is positioned the vector of distraction cannot be changed and no rotational adjustments can be done. This can influence the accuracy of the final position of maxilla(34).		
Not predictable results as CO(35).		
DO is longer in time at least 3 months and followed by face mask therapy(36).		
The further away the device is placed from center of movement the more asymmetrical movement is obtained(37).		

RED (rigid external distractor)	Palatal distractor	Trans-sinusoidal distractor
device is awkward and social embracing block patient's vision. (37).	device is cemented on teeth and ideal point is the middle center of the palate so when activated the more expansion at the alveolar portion and less at the apex of the palate(38).	require contouring of the bone for better placement and vector control this may cause difficulty with fixation to bone because of frequently encountered inadequate bone surface and quality(39).
Early mobility of pins - infection – scaring(36).	counterclock wise rotation and distalization of the molars(31).	trams exit from the mouth(35).
The longer the distance from the axial screw of the distractor to the callus, the less effective the distraction(39)	limited for the anterior maxilla only.	trams need to be at the level of occlusal plane to exit near buccal orifice (needs to converge) or use customized device which increase the cost(39).
Multivector allow change in the 1ry vector opposite to IO devices(40).	Another possible complication is the occurrence or aggravation of open bite after AMD. Its better the use of bone-borne distractors and adequate downward distraction could be more effective in the prevention of anterior teeth open bite(31).	doesn't leave extraoral scar(39).
changing in direction is also limited as it may produce more strain on the segment. It may induce inc. or dec. tensional forces that placed on maxilla i.e. if the device is more inferior it produces more tensional forces(39).		
Require the patient to be educated on how the device is used because of its manual components that need to be activated(34).		
follow up visits to assure the patient family are using it correctly(34).		
wires that are used can stretch the 1st few days and may not be a true indicator of maxillary advancement(41).		
maximum period for retention is of average 4 weeks otherwise increased risk of infection and psychological acceptance this will affect the consolidation and then Increase relapse(41,42).		

**Table 1 Types of DO devices with their merits and demerits.**

Each case of CLP patient has different challenges and severity, this affects the decision-making process. Conventional orthognathic (CO)surgery is considered a best option for CLP patients if there is good assessment for the challenges and can overcome them, however many cases are difficult to achieve a successful CO then DO is considered a plan B.

**IV. Conclusion:**

Based on the previous literatures there is no strong evidence that supports which orthognathic technique is better than other for CLP patients. However, it is important to consider the key factors for a successful CO for its merits. DO offers an alternative option for difficult CLP cases.

**References:**

- [1] Mossey Pa, Modell B. Epidemiology Of Oral Clefts: An International Perspective, In Cleft Lip And Palate. Front Oral Biology. 2012;16(1):1–18.
- [2] Stuppia L, Capogreco M, Marzo G, La Rovere D, Antonucci I, Gatta V, Et Al. Genetics Of Syndromic And Nonsyndromic Cleft Lip And Palate. Journal Of Craniofacial Surgery. 2011;22(5):1722–6.
- [3] Dixon Mj, Marazita Ml, Beaty Th, Murray Jc. Cleft Lip And Palate: Understanding Genetic And Environmental Influences. Nat Rev Genet. 2011;12(3):167–78.
- [4] Parker Se, Mai Ct, Canfield Ma, Rickard R, Wang Y, Meyer Re, Et Al. Updated National Birth Prevalence Estimates For Selected Birth Defects In The United States, 2004-2006. Birth Defects Res A Clin Mol Teratol. 2010;88(12):1008–16.
- [5] Frederick R, Hogan Ac, Seabolt N, Stocks Rms. An Ideal Multidisciplinary Cleft Lip And Cleft Palate Care Team. Oral Dis. 2022 Jul 1;28(5):1412–7.
- [6] Roy Aa, Rtshiladze Ma, Stevens K, Phillips J. Orthognathic Surgery For Patients With Cleft Lip And Palate. Clin Plast Surg. 2019;46(2):157–71.

- [7] Good Pm, Mulliken Jb, Padwa Bl. Frequency Of Le Fort I Osteotomy After Repaired Cleft Lip And Palate Or Cleft Palate. *Cleft Palate-Craniofacial Journal*. 2007;44(4):396–401.
- [8] Khoo Fcsc And Ls. Cleft Orthognathic Surgery. *Plastic Surgery Secrets Plus*. 2022;(Mmc):192–5.
- [9] Phillips Jh, Nish I, J. D. Orthognathic Surgery In Cleft Patients. *Plastic And Reconstructive Surgery* 2012 Mar 1;129(3):535e-48e.
- [10] Posnick Jc, Tiwana Ps. Cleft-Orthognathic Surgery Bt - Cleft Lip And Palate. In: Berkowitz S, Editor. *Cleft Lip And Palate*. Berlin, Heidelberg: Springer Berlin Heidelberg; 2006. P. 573–85.
- [11] Posnick Jc, Kinard Be. Challenges In The Successful Reconstruction Of Cleft Lip And Palate: Managing The Nasomaxillary Deformity In Adolescence. Vol. 145, *Plastic And Reconstructive Surgery*. 2020. 591e-603e P.
- [12] Posnick Jc, Tompson B. Modification Of The Maxillary Le Fort I Osteotomy In Cleft-Orthognathic Surgery: The Unilateral Cleft Lip And Palate Deformity. *Journal Of Oral And Maxillofacial Surgery*. 1992;
- [13] Posnick Jc, Tompson B. Modification Of The Maxillary Le Fort I Osteotomy In Cleft-Orthognathic Surgery: The Bilateral Cleft Lip And Palate Deformity. *Journal Of Oral And Maxillofacial Surgery*. 1993;
- [14] Prado Dg De A, Berretin-Felix G, Migliorucci Rr, Bueno M Da Rs, Rosa Rr, Polizel M, Et Al. Effects Of Orofacial Myofunctional Therapy On Masticatory Function In Individuals Submitted To Orthognathic Surgery: A Randomized Trial. *Journal Of Applied Oral Science*. 2018;26:1–12.
- [15] Szyszka-Sommerfeld L, Woźniak K, Matthews-Brzozowska T, Kawala B, Mikulewicz M. Electromyographic Analysis Of Superior Orbicularis Oris Muscle Function In Children Surgically Treated For Unilateral Complete Cleft Lip And Palate. *Journal Of Cranio-Maxillofacial Surgery*. 2017 Sep;45(9):1547–51.
- [16] Carvajal R, Miralles R, Cauvi D, Berger B. Superior Orbicularis Oris Muscle Activity In Children With And Without Cleft Lip And Palate. *The Cleft Palate Craniofacial Journal*. 1992;
- [17] Kummer Aw, Briggs M, Lee L. The Relationship Between The Characteristics Of Speech And Velopharyngeal Gap Size. *Cleft Palate-Craniofacial Journal*. 2003;40(6):590–6.
- [18] Fox Dr. Speech Implication Of Orthognathic Intervention. In *Cleft Lip And Palate 2006* (Pp 607-611) Berlin, Heidelberg: Springer Berlin Heidelberg. 2006;607–11.
- [19] Valling Ld. Speech, Velopharyngeal Function, And Hearing Before And After Orthognathic Surgery. *Journal Of Oral And Maxillofacial Surgery*. 1990 Dec;48(12):1274–81.
- [20] Herber Sc, Lehman Ja. Orthognathic Surgery In The Cleft Lip And Palate Patient. *Clin Plast Surg*. 1993;
- [21] Posnick Jc. Modified Orthognathic Surgery To Manage The Residual Alveolar Cleft(S). In: *Cleft Maxillary Reconstruction*. Cham; 2023. P. 127–53.
- [22] Heliövaara A, Ranta R, Hukki J, Rintala A. Skeletal Stability Of Lefort I Osteotomy In Patients With Isolated Cleft Palate And Bilateral Cleft Lip And Palate. *Int J Oral Maxillofac Surg*. 2002 Aug;31(4):358–63.
- [23] Turvey T. Maxillary Advancement And Contouring In The Presence Of Cleft Lip And Palate. *Facial Clefts And Craniosynostosis Principles And Management*. 1996;
- [24] Posnick J, Dagsys A. Skeletal Stability And Relapse Patterns After Le Fort I Maxillary Osteotomy Fixed With Miniplates The Unilateral Cleft Lip And Palate Deformity. *Lww*. 1994;
- [25] Welch Tb. Stability In The Correction Of Dentofacial Deformities: A Comprehensive Review. *Journal Of Oral And Maxillofacial Surgery*. 1989;47(11):1142–9.
- [26] Finn, R. A., Throckmorton, G. S., Bell, W. H., & Legan Hl. Biomechanical Considerations In The Surgical Correction Of Mandibular Deficiency. *Journal Of Oral Surgery (American Dental Association : 1965)*, 38(4), 257–264.
- [27] Throckmorton Gs, Buschang Ph, Ellis E. Morphologic And Biomechanical Determinants In The Selection Of Orthognathic Surgery Procedures. *Journal Of Oral And Maxillofacial Surgery*. 1999 Sep;57(9):1044–56.
- [28] Van Sickels J, Salman So. Complications In Orthognathic Surgery Bt - Peterson's Principles Of Oral And Maxillofacial Surgery. In: *Peterson's Principles Of Oral And Maxillofacial Surgery*. Cham; 2022. P. 2039–69.
- [29] Siebert Jw, Angrigiani C, Mccarthy Jg, Longaker Mt. Blood Supply Of The Le Fort I Maxillary Segment: An Anatomic Study. *Plast Reconstr Surg*. 1997;100(4).
- [30] Lanigan Dt, Hey Jh, West Ra. Major Vascular Complications Of Orthognathic Surgery: Hemorrhage Associated With Le Fort I Osteotomies. *Journal Of Oral And Maxillofacial Surgery*. 1990 Jun;48(6):561–73.