

A Rare Presentation Of Fibrosarcomatous Change In The Background Of Dermato Fibrosarcoma Protuberans In A Child With Down Syndrome

Dr. Jitendra Verma

Pg Resident , Department Of General Surgery, Sharda School Of Medical Sciences & Research, Greater Noida-201310, Up

Dr. Vikram Singh Chauhan

Professor , Department Of General Surgery, Sharda School Of Medical Sciences & Research, Greater Noida 201310, Up

Dr. Purshotam Dass Gupta

Professor , Department Of General Surgery, Sharda School Of Medical Sciences & Research, Greater Noida 201310, Up

Dr. Ashok Kr Gupta

Professor , Department Of General Surgery, Sharda School Of Medical Sciences & Research, Greater Noida 201310, Up

Abstract

Dermatofibrosarcoma protuberans is a cutaneous Soft tissue neoplasm with potential for local recurrence but distant metastasis is rare. Trunk and extremities are most commonly involved. This case presented 12 yr old male with Down syndrome presented with a recurrent swelling in left flank since 5 yrs. He had underwent wide local excision 3 times in past 5 yr. Despite the repeated excisions, the swelling recurred again for 4th time. The patient underwent wide local excision. Tissues were subjected to histopathological and immunohistochemical test subsequently. The tumour cells show mild to moderate pleomorphism, ovoid to fusiform nuclei and brisk mitotic active (10-11/10 hpf) at places. They were reactive to CD 34. The diagnosis of Dermatofibrosarcoma protuberans with areas of fibrosarcomatous change was given.

Key Words: CD34, Dermatofibrosarcoma protuberans, Fibrosarcoma, Mitotic figures, Down syndrome

Date of Submission: 17-06-2024

Date of Acceptance: 27-06-2024

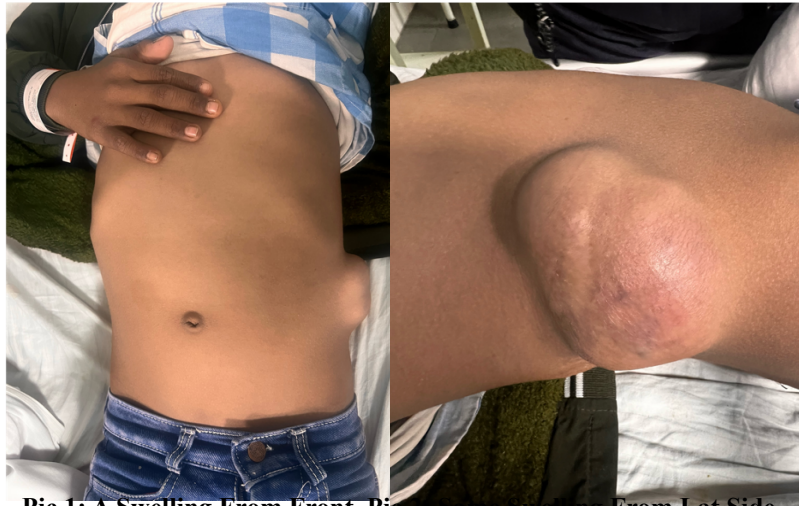I. Introduction

Dermatofibrosarcoma protuberans (DFSP) is a rare type of skin tumor that was first identified by Taylor in 1890. While it tends to grow locally and infiltrate surrounding tissues, it rarely spreads to distant parts of the body.^[1] DFSP typically affects adults aged 30 and older, comprising a small percentage (2-6%) of all soft tissue sarcomas. It commonly develops on the trunk and limbs, with an equal occurrence in males and females. The primary treatment approach involves surgical removal, with wide local excision being the preferred method. However, Mohs micrographic surgery (MMS) is gaining popularity as an alternative.^[2] Our case report presents two unique aspects: the rare co-occurrence of DFSP with Down Syndrome and the presence of fibrosarcomatous changes in the background of DFSP.

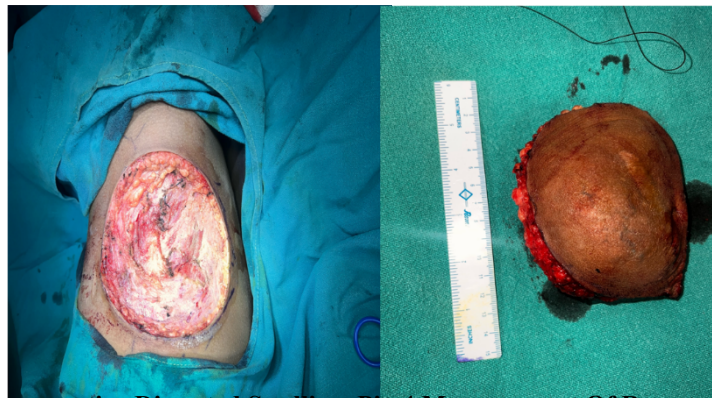
II. Case Report

A 12-year-old male child with Down syndrome presented with a recurrent swelling over the left flank persisting since the age of 6.5 years. The initial episode, characterized by a swelling approximately 1 cm in size, subsequently increased to approximately 5 cm, leading to the first excision at a private hospital in Aligarh. Despite two subsequent excisions following recurrences, the swelling persisted and demonstrated rapid growth over a period of 1.5 years, eventually reaching dimensions of approximately 10*5 cm by the fourth recurrence (Fig 1a). The swelling was accompanied by dull aching pain localized to the affected area, with no associated

systemic symptoms noted.



Pic 1: A Swelling From Front, Pic 2: Same Swelling From Lat Side

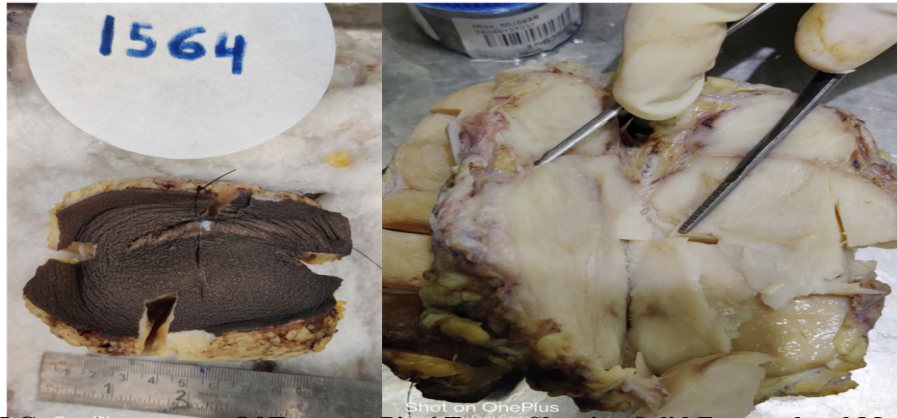

Pic :3 Intraoperative Dissected Swelling Pic:4 Measurement Of Resected Swelling

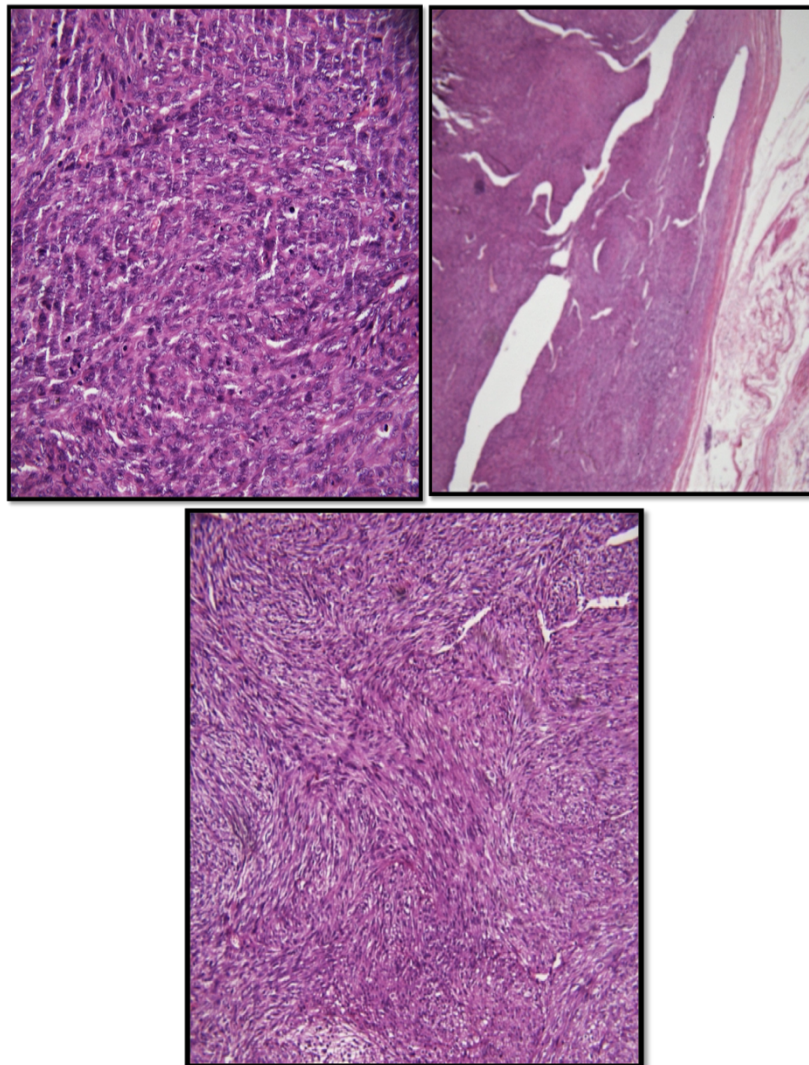
General examination revealed a well-nourished child with Down syndrome, exhibiting no notable abnormalities. Local examination revealed a solitary, globular swelling with smooth, irregular margins and a scar from previous excisions. Palpation indicated a firm, mobile swelling fixed to the overlying skin but not to underlying structures, with no regional lymphadenopathy appreciated. Differential diagnoses considered included liposarcoma, fibrosarcoma, rhabdomyosarcoma, and various sarcomatous lesions, ultimately leading to a provisional diagnosis of soft tissue sarcoma.

Laboratory investigations, encompassing a complete blood count and liver and renal function tests, revealed results falling within normal range.

Additionally serology tests for HIV, HCV, HbsAg returned negative results Workup included laboratory investigations showing normal results, ruling out systemic involvement, and imaging studies revealing a heterogeneous, hyperechoic mass lesion in the subcutaneous plane of the left flank. Patient underwent wide local excision with a 3 cm margin (Fig 1b). Gross appearance of the tumour was solid, which was well encapsulated. The solid area was greyish fleshy in appearance.(Fig2a) Histopathological analysis revealed a fairly well-circumscribed spindle cell tumor with features of fibrosarcomatous transformation. Microscopic examination showed hypercellularity with areas of collagenization, prominent dilated blood vessels, and mild to moderate pleomorphism of tumor cells with brisk mitotic activity. Immunohistochemical analysis demonstrated positivity for CD34.



Pic:5 Gross Appearance Of Tumour **Pic:6** Tumor Showing Solid Encapsulated Mass



Pic:6 A) Atypical Mitosis At 40x. B) Capsule Seen At 10x C) Storiform Pattern Seen At 20x

Given the aggressive nature of fibrosarcomatous variants, characterized by high local recurrence rates, propensity for distant metastasis, and poor prognosis, the patient was referred to a higher center for adjuvant radiotherapy. This case highlights the challenges in managing recurrent soft tissue sarcomas, particularly in pediatric patients with underlying conditions like Down syndrome, emphasizing the necessity for comprehensive evaluation and multidisciplinary management approaches for optimal outcomes.

III. Discussion

DFSP is an intermediate-grade malignant tumor believed to originate from dermal stem cells or undifferentiated mesenchymal cells, constituting only 2–6% of all soft-tissue sarcomas.^[1] While it has a low metastatic rate, DFSP is notorious for its high local recurrence. Although cases suggest an equal sex distribution, it is more commonly seen in females with a median age of 35 years. ^[4] Typically, DFSP affects the trunk (42%–72%), proximal extremities (16%–30%), and head-and-neck regions (10%–16%). Various risk factors associated with DFSP include previous surgical interventions, skin trauma, vaccination, tattooing, radiation, burns, pregnancy, and hormonal treatment with estrogen.

The pathogenesis of DFSP involves a chromosomal translocation t(17;22) (q22;q13), resulting in the fusion of the collagen type I α 1 gene (COL1A1) and platelet-derived growth factor-beta polypeptide gene (PDGFB), leading to the formation of COL1A1-PDGFB fusion transcripts. This fusion upregulates PDGFB, continuously activating platelet-derived growth factor receptor-beta, thereby promoting cell proliferation and tumor formation.

Grossly, DFSP appears as a reddish-brown to normal skin-colored thickened plaque that gradually becomes nodular and protuberant. Histopathologically, DFSP exhibits a characteristic storiform and cartwheel arrangement of spindle cells with CD34 positivity on immunohistochemistry.

Mohs micrographic surgery is the preferred treatment modality for DFSP, offering thorough histological clearance with a low recurrence rate of 1%. Surgeons typically recommend excision with a margin of 2–4 cm around the surrounding skin, including underlying fascia, without elective lymph node dissection.

Skin defects post-wide local excision may be corrected using local or distant flaps. Radiotherapy should be considered in cases where adequate wide excision alone may result in significant cosmetic or functional deficits. DFSP generally has a good prognosis with a 10-year survival rate of 99.1%. However, close follow-up for at least 3 years is recommended due to the higher chances of recurrence during this period.

IV. Conclusion

Dermatofibrosarcoma protuberans (DFSP) presents a diagnostic challenge, especially when occurring in uncommon sites. Delayed treatment due to misdiagnosis can result in local growth and incomplete excision. Therefore, it is imperative for pediatricians to be vigilant of this rare condition and advocate for wide excision to minimize the risk of recurrence. Long-term follow-up, as DFSP has a propensity for late recurrence, necessitating vigilant surveillance to detect and manage recurrences promptly. Additionally, further research is warranted to explore the potential association between Down syndrome and DFSP in pediatric patients.