

Scrub Typhus Mimicking STEMI - A Rare Presentation

Authors - Dr. Divya Sridhar¹, Dr. Adhiya senguttuvan¹, Dr. Preetam Krishnamurthy¹, Dr. Vinod Kumar Balakrishnan¹

Affiliation: ¹Department of Cardiology, Sri Ramachandra Institute of Higher Education and Research, Porur, Chennai-600116

Date of Submission: 16-01-2025

Date of Acceptance: 26-01-2025

I. Case Report:

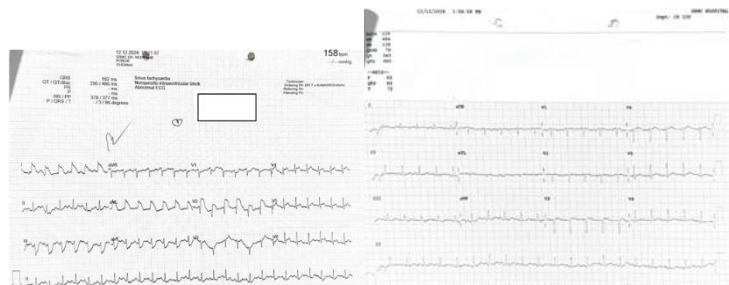
A 62-year female who was a Homemaker, known Diabetic, presented to the Emergency Room with complaints of intermittent high-grade fever for 3 days and shortness of breath for 1 day. She was treated conservatively elsewhere for fever. She had no history of exposure to Crowded places, nor she had any recent travel history. Her breathlessness progressed from class II to IV since that morning.

On examination, Patient was tachypneic, conscious, oriented, afebrile. Temperature was 99⁰F. There was no pallor, icterus, clubbing, pedal edema, lymphadenopathy. Two Eschars was noted over left arm and right thigh. Blood pressures were 130/90 mmHg. Pulse rate was 144 per minute. Respiratory Rate was 30 per minute. SPO2 was 59% at room air and 99% with NIV support. Cardiovascular system examination revealed normal first and second heart sounds without any murmurs. Respiratory system examination revealed Bilateral inspiratory crepitations. Per abdomen examination was unremarkable. In view of respiratory distress, patient was intubated in the Emergency Room.

Figures 1 and 2: Images of Eschar on Right thigh and left arm

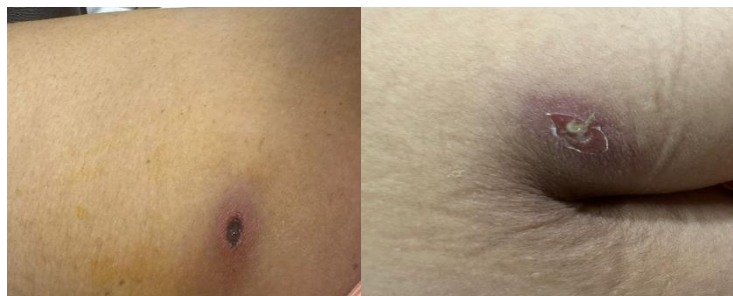

Figure 3: 12 lead ECG On Arrival; Figure 4: 12 lead ECG After Coronary Angiogram



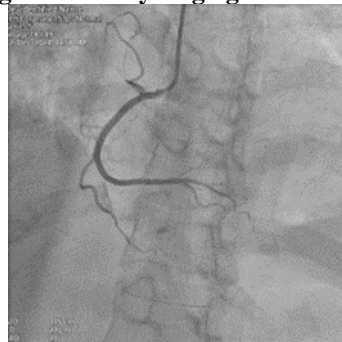
ECG showed ST elevation in lead I, avL, V2 to V6 with reciprocal changes in inferior leads with poor R wave progression. Echocardiogram showed Moderate LV dysfunction with hypokinetic LAD territory, with ejection fraction 38%. Serial Troponin (0.29 to 6.12) and CKMB (5.7 to 21.5) were in rising trend. Patient was

provisionally diagnosed to have Acute Coronary Syndrome - STEMI - Anterolateral wall Myocardial Infarction - KILIP Class III. Loading doses and Heparin were given. Initially, High risk Primary PCI was planned and after obtaining appropriate consents, Coronary Angiogram was done through right radial approach which showed Normal coronaries with Right dominant circulation and patient was found to have Type 2 Myocardial Infarction. Hence, was planned for medical management.

Figure 5 and 6: Selective Left Coronary Angiogram showing normal Left coronaries

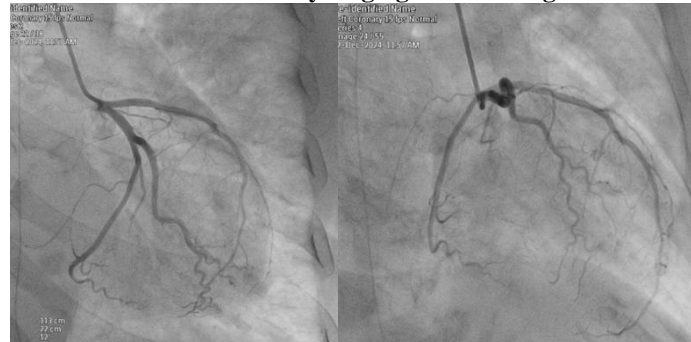

Figure 7: Selective Right Coronary Angiogram showing normal coronaries



Repeat ECG after coronary angiogram showed complete resolution of ST segment uptake. Total counts were elevated (16660/ μ L). Renal function tests and serum electrolytes were within normal limits. Liver enzymes were mildly elevated. In view of fever with eschar on the right thigh and left arm, fever panel with scrub IgM was sent. Lipid profile was within normal limits. Viral Markers were non-reactive. Respiratory Viral panel was negative for Influenza A, Influenza B, SARS COV 2 and Respiratory syncytial virus A and B. Blood cultures from multiple sites showed no growth. Chest X ray showed bilateral mild pleural effusion. Ultrasound abdomen showed hepatomegaly with Grade I fatty infiltration. Urine culture showed no growth. Dengue antigen assay was negative. Scrub typhus IgM was positive (71.44 units). Glycated Hb was 9.3.

Patient was managed with Intravenous diuretic infusion, nebulization, IV antibiotics and other supportive measures. Patient gradually improved, was extubated to oxygen support. Patient was continued on anti-failure measures and was decongested well and was shifted to ward in a stable state. Serial ECG monitoring showed no dynamic changes. Echocardiogram was reassessed in which LV function improved to normal with ejection fraction of 60%, and there were no regional wall motion abnormalities. On day 8, patient was discharged home in a stable state.

II. Discussion:

Scrub typhus, also known as bush typhus is caused by a mite borne gram negative orientia tsutsugamushi, which inhabits intracellularly. It is transmitted by trombiculid mites, also known as chiggers. It is known to cause Acute febrile illness in humans with constitutional symptoms. Some virulent strains can cause more severe form of disease, causing hemorrhagic manifestations, vasculitis, lymphadenopathy, Acute Respiratory Distress syndrome, Encephalitis, Myocarditis. It is more common in Northeastern parts of India. Its transmission is mainly through floor dirt and in green grass floors. (1)

It causes inflammation of endothelial cells of small to medium sized vessels and causes vasculitis and perivascular changes, thereby leading to increased vascular permeability. (2) More virulent strains are notorious to cause Multi organ dysfunction Syndrome, leading to acute respiratory distress syndrome, acute kidney injury, transaminitis, hepatitis, myocarditis, encephalitis and meningitis. With virulent strains, mortality is known to be

higher up to 30%. (3) Cardiovascular involvement has known to result in LV dysfunction, acute coronary syndromes and increased morbidity.(4)

There are very few case reports of scrub typhus presenting as myocardial infarction with coronary involvement. (5,6,7) In our case report, to our surprise the coronaries were normal,inspite of ECG localization of extensive anterolateral wall ST elevation myocardial infarction, thus warranting further medical management. In a resource limited setting, if non accessible to primary PCI centers, thrombolytic therapy is the first line of management in STEMI. However, scenarios like our case report emphasizes the need for urgent coronary evaluation in scrub typhus presenting as ACS before administration of thrombolytic therapy to avoid untoward increase in bleeding risk.

III. Conclusion:

Scrub typhus is a relatively rare disease with most common presentation as acute febrile illness with thrombocytopenia and a characteristic eschar in at least half of the patients.It is essential to be aware of such rare presentations of a common disease to make appropriate treatment decisions and to avoid complications.

References:

- [1] Kelly DJ, Fuerst PA, Ching WM, Richards AL. Scrub Typhus: The Geographic Distribution Of Phenotypic And Genotypic Variants Of OrientiaTsumugamushi. Clin Infect Dis. 2009;48(Suppl_3):S203-30. [Crossref][Pubmed]
- [2] Dogra S. Recent Advances In Understanding Pathophysiology Of Scrub Typhus. JK Science. 2010;12(2):70-71.
- [3] Griffith M, Peter JV, Karthik G, Ramakrishna K, Prakash JA, Kalki RC, Et Al. Profile Of Organ Dysfunction And Predictors Of Mortality In Severe Scrub Typhus Infection Requiring Intensive Care Admission. Indian J Crit Care Med. 2014;18(8):497-502. [Crossref][Pubmed]
- [4] Dhiman P, Sharma A, Raina R, Madabhavi I, Gupta S. Scrub Typhus Presenting As Acute Myocardial Infarction. Online J Health Allied Sci. 2012;11(3):01-02.
- [5] Chen Y, Guo Z, Wang L, Cheng N, Wang C. The First Case Report Of Acute Myocardial Infarction In Young Adult Caused By Scrub Typhus. Medicine. 2023;102(39):E35271. [Crossref][Pubmed]
- [6] Kim DG, Kim JW, Choi YS, Kim SH, Kim SM, Park CG, Et Al. Acute Myocardial Infarction Following Scrub Typhus Infection. Int J Cardiol. 2007;114(1):E18-20. [Crossref][Pubmed]
- [7] Pradeesh A, Vasudevan B, Sharma N, Verma R. A Rare Case Of Scrub Typhus Vasculitis Presenting As Acute Coronary Syndrome Diagnosed By Skin Manifestations. Indian J Dermatol VenereolLeprol. 2022;88(2):184-87. [Crossref][Pubmed]