

Clinical Morphopathological Considerations In The Pulmonary Hydatid Cyst Complicated By Endobronchial Rupture In Children

Babuci S.^{1,2} Dogotari N.,¹ Petrovici V.,^{1,2} Ambros I.,^{1,2} Negru V.²

PMSI Mother and Child Institute

¹“Natalia Gheorghiu” National Scientific-Practical Center for Pediatric Surgery

²“Nicolae Testemițanu” State University of Medicine and Pharmacy

ABSTRACT

Introduction. Hydatid cyst is a zoonotic parasitic disease induced by the larval form of *Echinococcus granulosus*, which continues to be a public health problem in many regions of the world, including the Republic of Moldova, being among the neglected tropical diseases recognized by the World Health Organization.

The aim of this study is the histopathological analysis of the pulmonary hydatid cyst complicated by rupture in children with the evaluation of the changes in the structural architecture of the hydatid larvocyst and their correlation with the spectrum of histopathological changes in the fibrous capsule (pericyst) and the pericystic lung parenchyma involved and responsible for the severity of the inflammation and reparation of pericystic tissues.

Material and methods. The histopathological study included 11 patients with pulmonary hydatid cyst complicated by endobronchial rupture and operated at different time periods from the onset of complications. It was used to examine the elements of the parasitic metacestode, fragments of pericyst (fibrous capsule) and pericystic lung tissue, taken intraoperatively.

Results. In 4 cases of pulmonary hydatid larvocyst ruptured in the bronchus and operated within 24-48 hours from the occurrence of the complication, morphological changes characteristic for a parasite in the evolutionary phase of active fertility were detected, with the presence of partial necrolytic changes of the lamellar cuticle, with an uneven reduction of the lamellar structures, in places with a characteristic appearance of homogenization. In 2 cases, the presence of a disintegrated, partially fasciculated hydatid larvocyst with the presence of a semitransparent liquid was found. In these cases, the lamellar cuticle had a whitish color, and yellowish necrolytic areas or plaques were observed. In all these cases, the internal surface of the larvocyst was white-matte in color, with lamellar cuticle residues, and crater-like eruptions observed in some areas. In the remaining 5 cases of viable pulmonary hydatid cyst complicated by endobronchial rupture hospitalized and subjected to medical-surgical treatment 72 hours after the onset of the complication, the morphopathological changes were much more severe. In these cases, the histological examination made it possible to find the lamellar membrane with homogenization, determining the disordered structure due to intumescence and necrolytic processes, in some places with attenuation of the lamellar aspect. In some areas, the proliger membrane had dystrophic, necrolytic and desquamative changes, completely disorganized, in places with large proteinaceous agglomerations with a varied parasitic cellular component. Aggregations of leukocytes could be observed from the outside. The 2 cases of hydatid cyst complicated with endobronchial rupture and subjected to surgical treatment after a period of more than 12 days from the occurrence of the complication showed characteristic changes of a severe infectious-inflammatory process, including the association of alterative changes of all parasitic structural elements, with the penetration of the inflammatory cellular infiltrate into the layers of the parasitic larvocyst and the association of degeneration phenomena. In both cases, the parasitic larvocyst was considered mortified, the germinal elements of the parasite being in the calcification phase. The histological explorations made at the level of the periparasitic capsule confirmed the presence of necrotic lesions within the hyalinization area associated with a perifocal polymorphocellular inflammatory process with the presence of eosinophils and reticular-epithelial tissue reactions. The lung parenchyma at various distances showed an interstitial infiltration of various intensity, the presence of an interstitial and peribronchial sclerogenic reaction. Simultaneously with the described morphopathological changes, mortified parasitic germinal elements were observed in the tissues of the fibrous capsule, but also some elements capable to contribute to the recurrence of the disease.

Conclusions:

1. In cases of pulmonary hydatid cyst complicated by endobronchial rupture, the hydatid metacestode is subjected to some partial necrolytic changes of the lamellar cuticle, with uneven reduction of lamellar structures, with characteristic signs of homogenization. However, in the early stages of the complication, in

some areas, the partial viability of the parasitic elements (protoscolexes and daughter vesicles) and the germinal membrane is found, which partially preserves its properties of remultiplication, these properties being damaged with the passage of time.

2. Pulmonary hydatid cyst complicated by endobronchial rupture in children is characterized by granulomatous infiltrative inflammatory processes of the pericystic (adventitial) layer, with the association of necrotic degeneration changes, with the development of vascular thrombotic syndrome in the pericyst and the adjacent lung parenchyma and an acute granulocytic inflammatory process with eosinophilic component.

3. In the regions of the pericystic lung parenchyma of the pulmonary hydatid cyst complicated by endobronchial rupture, signs of pneumopathy are attested, manifested by granulomatous exulcerative bronchitis and micropapillomatous bronchiolitis, fibrinous and fibrino-leukocytic alveolitis, and the pleural area is characterized by mesothelial micropolypous inflammatory-proliferative phenomena. These morphopathological manifestations determine a major risk of developing complications, including the insufficiency of padding sutures, the persistence of bronchial fistulas, which can cause a long postoperative morbidity.

4. Along with the alterative-necrolytic changes of the parasitic structures and the significant inflammatory-destructive processes of the pericystic layer, some findings have been documented that indicate the possibility of the development of secondary parasitic cystic formations located in the pericystic tissues, which can determine a major risk of development of local recurrences after surgery.

Keywords: Pulmonary, hydatid cyst, children.

Date of Submission: 28-05-2023

Date of Acceptance: 08-06-2023

I. Introduction

Hydatid cyst is a zoonotic parasitic disease induced by the larval form of *Echinococcus granulosus* (Cestoda class, Taeniidae family) with the predominant involvement of the liver (60% - 80%) and lungs (20% - 30%), although it can be observed in any organ and body part [Aydin Y. et al., 2022, Goussard P. et al., 2022]. This disease continues to be a public health problem in many regions of the world [Salman H. et al., 2023], including the Republic of Moldova, being among the neglected tropical diseases recognized by the World Health Organization [Agudelo Higuera N.I. et al., 2016].

According to some statistical data, approximately 10%-20% of hydatid cyst cases are observed in children. The incidence of postoperative complications is also quite high, especially in cases of hydatid cyst complicated by rupture, which constitutes 11.7%-29.4% [Hamouri S. et al., 2021, Kocaman O.H. et al., 2022].

The hydatid metacestode is characterized by a high potential to cause a local inflammatory process. However, the local reaction in cases of hydatid cyst varies from severe granulomatous lesions to the presence of a non-infiltrated collagenous capsule, derived from the resolution of the inflammation, which correlates with a stable host-parasite relationship that determines the development of fertile parasitic cysts [Breijo M. et al., 2008, Basika T., et al., 2012]. And if several mechanisms have been described in the specialized literature to explain the rupture of the hydatid cyst, such as the degenerative phenomena of the parasitic metacestodes, the diameter of the bronchial fistula, the intracystic pressure, the fragility of the endocyst membrane, the multiplication of the force effect and the anatomical characteristics of the lung [Ashour M.H. et al., 2016], then evolutionary aspects of morphopathological changes in pericystic tissues are not specifically approached in detail. In this context, there is a need of relevant elucidation studies of the pathological changes that occur in cases of rupture of the hydatid metacestode, establishing both the evolution of the parasitic agent in conditions of deseminant of the germinal elements, as well as the clinical-evolutionary particularities of the local inflammatory process, in this context being few studies [Hidalgo C. et al., 2019].

The aim of this study is the histopathological analysis of the pulmonary hydatid cyst complicated by rupture in children with the evaluation of the changes in the structural architecture of the hydatid larvocyst and their correlation with the spectrum of histopathological changes in the fibrous capsule (pericyst) and the pericystic lung parenchyma involved and responsible for the severity of the inflammation and reparation of pericystic tissues process.

II. Material and methods.

The histopathological study included 11 patients with pulmonary hydatid cyst complicated by endobronchial rupture and operated at different time periods from the onset of complications. It was used to examine the elements of the parasitic metacestode, fragments of pericyst (fibrous capsule) and pericystic lung tissue, taken intraoperatively. After prior fixation of the material in the sol. of 10% formalin, after 6 hours the macroscopic and microscopic processing of the selected samples (935 tissue samples) was resorted to, using the histoprocessing and automated staining network "Diapath" with the application of *hematoxylin & eosin, van*

Geison, selective Orceina and A&E staining methods. Histological examinations were performed with conventional microscopy.

III. Results.

The macroscopic examination found that the severity of the structural changes of the pulmonary hydatid metacestode complicated by rupture depended on the evolutionary stage of the parasite, as well as the term of treatment after the occurrence of this complication.

In 4 cases of pulmonary hydatid larvocyst ruptured in the bronchus and operated within 24-48 hours from the occurrence of the complication, morphological changes characteristic for a parasite in the evolutionary phase of active fertility was found, with the presence of partial necrolytic changes of the lamellar cuticle, with the uneven reduction of the lamellar structures, in places with a characteristic appearance of homogenization (fig. 1A). In some areas, fistulas with alterative changes associated with the disjunction of the lamellar membrane were observed, in which the presence of fragmented sectors of the proliger membrane and scolexes could be found. Along with these characteristic changes for all 4 cases, in 2 cases some aspects of remultiplication of germinal membranes were documented. In all these cases, the predominance of parasitic elements, such as scolexes and proligerous capsules at different stages of parasitic re-multiplication, was attested. On examination of the hydatid sand in the drop, a large number of mature scolexes were observed, which could also be found inside the proligerous capsules.

During the microscopic examination, on various areas of the larvocyst, the presence of characteristic signs for the active fertilization phase of the germinal membrane was observed, this having various thicknesses, hypercellularized (fig. 1B), on some areas acellularized, and the presence of some immature scolexes was also noted, which were at the embryonic stage (fig. 1C).

The periparasitic fibrous capsule had a pseudocartilaginous appearance, elastic-hard, with areas of light brown color, in some areas with small foci of a pale-yellow coloration (fig. 1D).

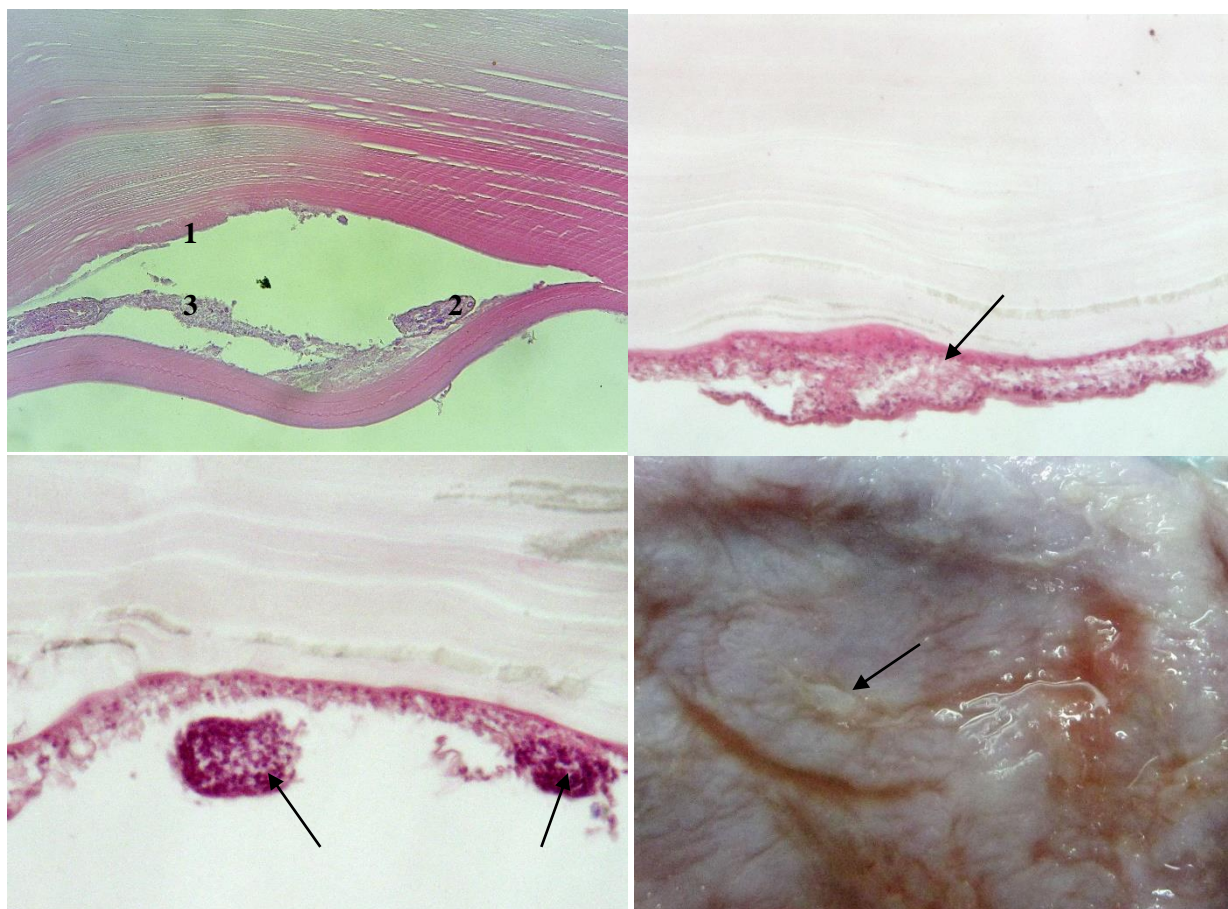


Fig. 1. A - the microscopic appearance of the lamellar membrane of the hydatid larvocyst complicated with disjunction of the lamellar structure: 1 - the alterative zone of the fistula at the level of the lamellar disjunction; 2 - mortified scolex; 3 - herniated proliger membrane in the area of the fistula. $\times 100$. Color. H&E. B - the germinal membrane of the parasitic larvocyst in the

In 2 cases, the presence of a disintegrated, partially fasciculated hydatid larvocyst with the presence of a semitransparent liquid was found. In these cases, the lamellar cuticle had a whitish color, and yellowish necrolytic areas or plaques were observed. In all these cases, the internal surface of the larvocyst was white-matte in color, with remnants of lamellar cuticle, and crater-like eruptions were observed in some areas (fig. 2A). In this small subgroup of patients, the histological examinations revealed the presence of some dystrophynecrolytic changes of the lamellar cuticle, with the presence of a germinal membrane in fertilization and remultiplication activity, with the presence of proligerous capsules, which contained mature scolexes (fig. 2B). In these cases also, various aspects of herniation of the proligerous membrane in the area of the cuticular membrane were attested. At these levels, the presence of proligerous capsules at various stages of evolution was also attested, some with the presence of scolexes at the embryonic stage (fig. 2C).

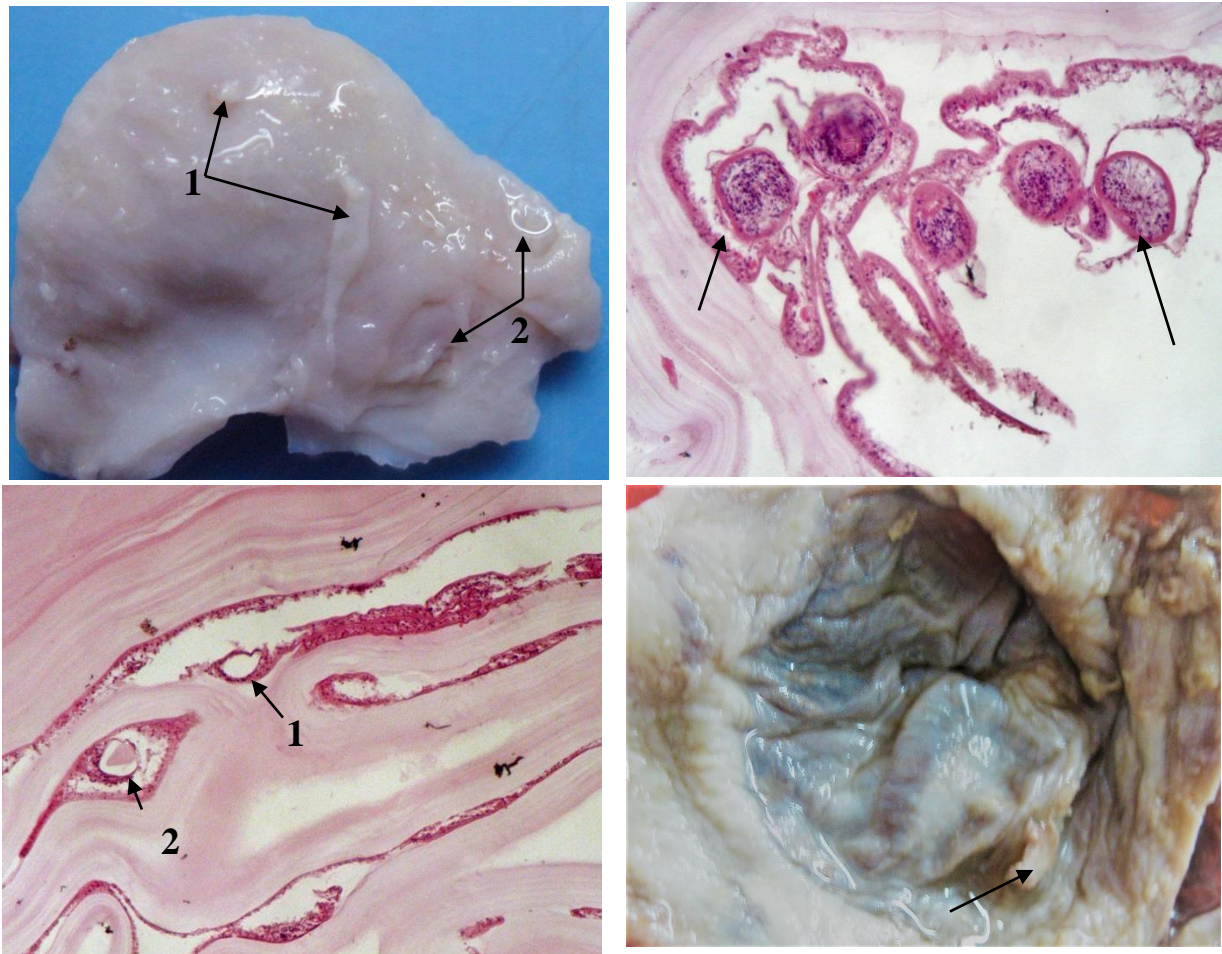


Fig. 2. A - the internal surface of the pericystic capsule: 1 - lamellar-cuticular membrane residues of the hydatid larvocyst; 2 - crater-like eruptions. B - Larvocyst in fertility with the presence of germ capsules with 1-2 mature scolexes. $\times 75$ Color. H&E. C - fascicular areas of the lamellar

In the remaining 5 cases of viable pulmonary hydatid cyst complicated by endobronchial rupture hospitalized and subjected to medical-surgical treatment 72 hours after the onset of the complication, the morphopathological changes were much more severe. In these cases, the histological examination found out the lamellar membrane with homogenization, revealing the disordered structure due to intumescence and necrolytic processes, in some places with attenuation of the lamellar aspect. In some areas, the proliger membrane had dystrophic, necrolytic and desquamative changes, completely disorganized, in places with large proteinaceous agglomerations with a varied parasitic cellular component. Aggregations of leukocytes could be observed from the outside (fig. 3A). On other fields of view, a fascicularization of the lamellar cuticle was attested, with the appearance of some fissural aspects, inside with cellular elements of the proliger membrane and lympho-leukocyte elements. Concomitant with these significant changes in the parasitic structural elements, in one case the development of daughter cysts was observed in the area of the proliger membrane (fig. 3B) and mortified

protoscolexes, which were located in the cracks of the cuticular membrane (fig. 3C), as well as in the lumen with the association of mycotic infection (fig. 3D).

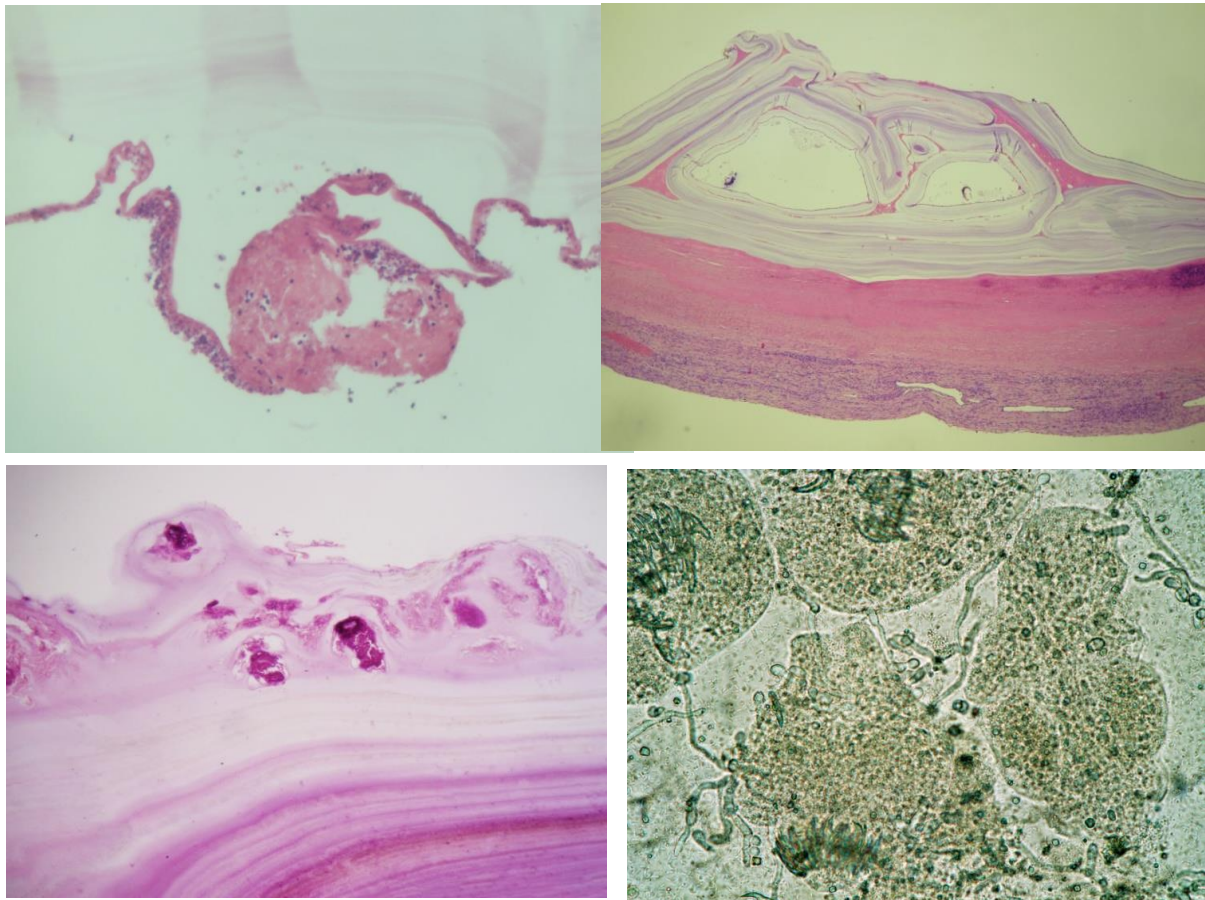


Fig. 3. A – The microscopic aspect of fibrino-cellular adhesive conglomerates at the proliger membrane with perifocal parasitic cell proliferation (1), the lamellar cuticle with phenomena of degeneration of the lamellar structures (2); B - aspects of scolex migration: Viable hydatid cyst with new daughter cysts in the area of the proliger membrane: 1- maternal larvocyst; 2- daughter cysts developed in the lamellar structure with protrusion in the lumen. *Color. H-E.* C – scolexes,

The 2 cases of hydatid cyst complicated with endobronchial rupture and subjected to surgical treatment after a period of more than 12 days from the time of occurrence of the complication showed characteristic changes of a severe infectious-inflammatory process, including the association of alterative changes of all parasitic structural elements, with the penetration of the inflammatory cellular infiltrate into the layers of the parasitic larvocyst and the association of degeneration phenomena. In both cases, the parasitic larvocyst was considered mortified, the germinal elements of the parasite being in the calcification phase.

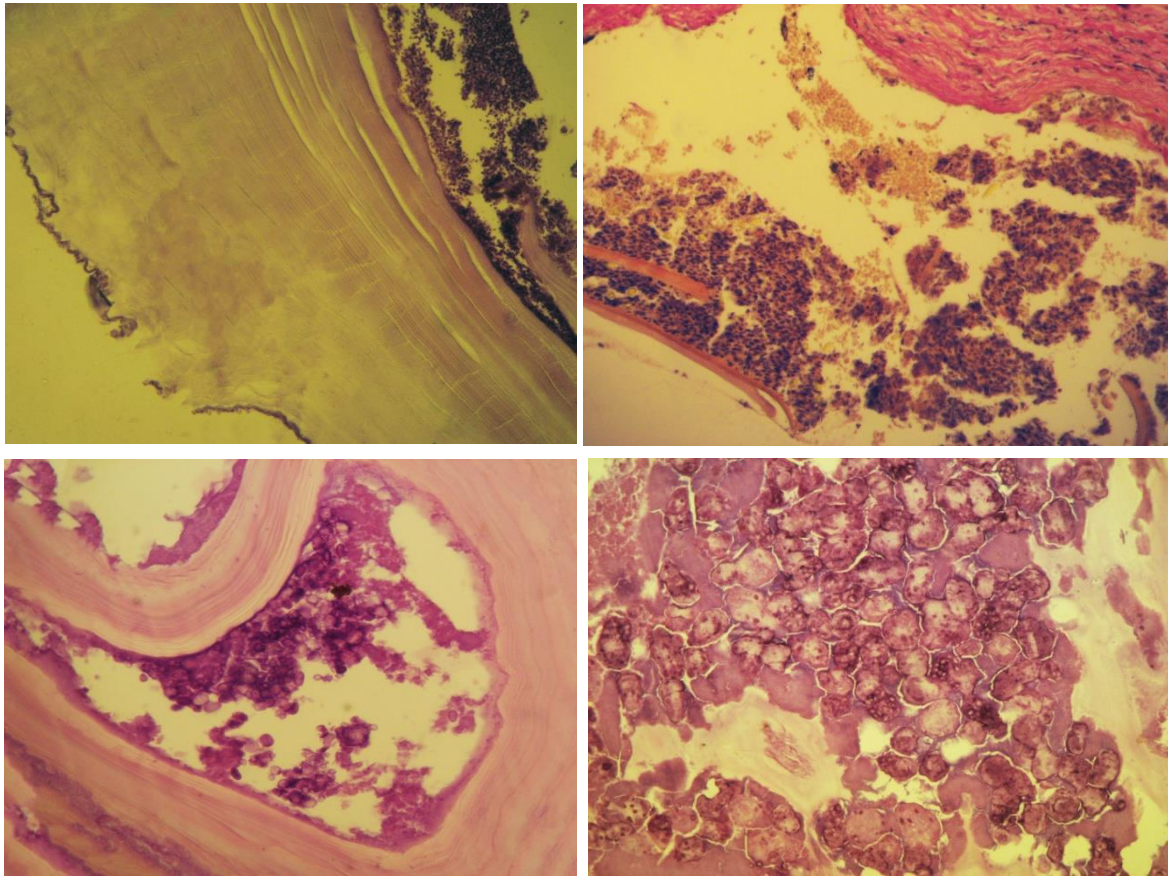


Fig. 4. Histological feature of late-diagnosed hydatid larvocyst complicated by endobronchial rupture. A – the hydatid larvocyst with focal alterative changes associated with the penetration of the inflammatory infiltrate into the lamellar cuticle. B – cellular

The histological explorations at the level of the periparasitic capsule confirmed the presence of necrotic lesions within the hyalinization area associated with perifocal polymorphocellular inflammatory process with the presence of eosinophils and reticulo-epithelial tissue reactions. The pulmonary parenchyma at various distances showed an interstitial infiltration of various intensity, the presence of an interstitial and peribronchial sclerogenic reaction, in various areas associated with the presence of lymphoid follicular structures with active peribronchial germinal centers and at the level of the interalveolar septa, thus forming a reactive perifocal lymphoid-follicular lymphocytic chain (fig. 5A). At the capsule level, in some areas, in parallel with the reticulo-epithelial reactions of the granulomatous inflammation underlying the necrolytic exulcerations, the presence of polynuclear cellular symplasts of the type of foreign body cells was also attested. It should be noted that adjacent to these areas the involvement of the vessels was attested, they showed perivascular and wall inflammatory processes as well as proliferative processes of the endothelium (fig. 5B).

In parallel, damage of the bronchial system with the involvement of bronchioles and small-caliber bronchi was also attested, these also manifested an exulcerative granulomatous bronchitis with peribronchitis and hyperplasia of the follicular lymphoid structures on account of the germinal centers (fig. 6A). Regarding the alveolar parenchyma or the alveolar-interstitial component near the capsule or circumscribed between the capsule and the lymphoid follicular chain, a macrophage alveolitis was also attested, on some areas being of protein serous origin (fig. 6B). The interstitium revealed by the interalveolar septa in various areas showed lesional changes characterized by alveolar atelectatic aspect and polymorphocellular infiltration of various intensity and interstitial sclerogenic reactions (fig. 6C).

fibrillary patch with ischemic changes. Among the necrotic-fibrinous masses, mortified protoscolexes could be observed (fig. 7A). In some areas, the capsular structure had some ischemic-necrotic changes, some merging with fissural structures from the newly formed fibrillary-fibroblastic connective area. Necrotic-fibrinous changes were found on the internal surface, the connective component of the fibrous capsule layer being hyalinized, the surface being covered with fibrinous masses, and in some areas secondary hydatid cystic formations circumscribed by newly formed cellularized fibrillar-fibroblastic tissue were found (fig. 7B).

In cases of pulmonary hydatid cyst complicated with endobronchial rupture and subjected to surgical treatment after a period of more than 12 days from the time of occurrence of the complication, the histopathological examination highlighted the hyalinized tissues of the fibrous capsule, with significant ischemic-alterative and necrolytic changes, with fascicularization aspects, in some areas manifesting by a sinusoidal aspect. The sinusoidal structures were lined with granulocytic elements, much more in the pericapsular area, where they form a granulocytic layer, followed by a fibrinous alveolitis mixed with granulocytes. The granulocytic component included eosinophilic elements in varying proportions. The vascular morphopathological changes were presented by the necrosis of the vascular network of the internal area of the pericyst, with a discrete eosinophilic reaction, blood stasis, with aggregation phenomena and small thrombi, in some areas fibrinoid necrosis of the vascular wall was observed. In some places, the disjunction with restructuring into a fistulous fissure was observed at the border between the necrotic and the fibrillary (fibrocytal-fibroblastic) zone, with pronounced inflammatory changes and eosinophilia (fig. 8A, B). The visceral pleura showed a mesotheliocyte proliferation and micropolypous appearance.

It should be noted that in these cases, simultaneously with the described morphopathological changes, mortified parasitic germ elements were observed in the tissues of the fibrous capsule, but also some elements capable to contribute to the recurrence of the disease (fig. 8C, D).

IV. Discussions.

The hydatid larvocyst consists of three structural components: the acellular laminar membrane, the germinal membrane and the hydatid fluid with germinal elements, the metacestode being surrounded by a fibrous capsule or granulation tissue (pericyst) [Kanan J.H.C., et al., 2006, Murray P.J., Wynn T.A., 2011, Bektas S., et al., 2016].

The laminar layer of the hydatid metacestode, generated by the metabolic activity of the geminal layer of the parasite, represents a specialized extracellular matrix, with a very complicated structure, formed by various layers of mucopolysaccharides and keratin, which contains nano-deposits of calcium inositol hexakisphosphate, being permeable for macromolecules, representing a very large area for the adsorption of diffusible proteins [Basika T. et al., 2012, Hidalgo C. et al., 2019, Rheiner M. et al., 2020]. It is evolutionarily adapted to maintain the integrity and protect the germ layer from the host's immune mechanisms, being involved in the down-regulation of the local inflammatory response [Siracusano A. et al., 2008, Diaz A. et al., 2011, Diaz A. et al., 2015]. Through the ability to inhibit the proliferation of macrophages and to induce the production of arginase, it neutralizes the activity of nitric oxide [Amri M. et al., 2009]. Although there are extensive knowledges about the structure of the hydatid metacestode laminar layer, which acts as a barrier against intermediate host cell-mediated effector mechanisms, there are major gaps in mucin proteomic activity data, about the ability of the laminar layer to induce the expression of inhibitory molecules of immunocompetent cells, etc. [Diaz A. et al., 2023].

The pericyst (fibrous capsule), also called the adventitial layer (Vuitton D.A. et al., 2020), is the outer zone of the hydatid cyst, which develops through the reaction of the host tissue to the parasite and consists almost entirely of host cells [Golzarı S.E.J. et al., 2014, Sakamoto T. et al., 2003]. *Echinococcus granulosus* infection of the intermediate host causes a granulomatous tissue reaction [Thomson R.C., 2017]. Cellular responses are dominated by neutrophils, eosinophils, mononuclear cells, and multinucleated giant cells, whose action is directed both toward the delimitation and elimination of the persistent foreign body. The characteristics of granulomatous reactions are determined by special types of activated macrophages, called epithelioid cells and polynucleated giant cells [Malla N. et al., 2016].

During the development of the hydatid metacestode, several morphopathological changes of the adjacent lung tissue were found, including: infiltration of inflammatory cells, necrotic changes, destructive processes of the lung tissue, development of fibrotic tissues, hemorrhage, congestion, calcification, etc. [Wynn T.A. et al., 2012, Turkoglu E. et al., 2017, Abeb N.D. et al., 2019]. Similar changes were found in our study, the severity of which directly influences the reparative processes. Fibrosis of the lung tissue can be caused by several factors, including infections with pathogens, some of which can cause alveolar-epithelial cell damage and apoptosis, bronchial compression with the subsequent development of atelectasis, stasis phenomena in the alveoli of the perifocal tissue, pressure changes in the air space with the migration of alveolar macrophages [Bektas S. et al., 2016, Minan O. et al., 2009, Wynn T.A. Barron L., 2010]. In cases of pulmonary hydatid cyst, especially in complicated forms, hemorrhages, congestion, bronchopneumonia or organized pneumonia may occur [Nabi

M.S., et al., 2010]. Some studies have reported that hydatid cysts can cause erosion of blood vessels, which can lead to congestion and hemorrhage, and compression of adjacent tissues can cause their destruction [Khadidja H. et al., 2014].

In cases of hydatid cyst, the host-parasite relationship is interactive, the evolution of the disease being dependent on the balance between the host's immune system mechanisms and the parasite's complex evasion strategies [Virginio V.G. et al., 2012], which include antigenic variation, suppression and modulation of T cells, inhibition of effector cells' chemotaxis, release of antigenic proteins, antioxidant defense, resistance to host proteolytic enzymes, etc. The understanding of these biological events is of fundamental importance in defining diagnostic and treatment tactics [Molyneaux P.L. et al., 2013, Seoane P.I. et al., 2016].

It is known that the infection induces an immune imbalance on the tissues of the affected organ with the severe destruction of the architecture, determined by the inflammatory infiltrates and the development of fibrosis [Tager A.M. et al., 2008]. This process is caused by the persistent activation of the immune system, which imposes unfavorable changes on the normal homeostasis of the organ. At the same time, the parasite, evading the defense forces of the host organism, favors the subsequent chronicity of the infection. In this context, the aspects of development of local immune responses in organs affected by hydatid cyst remain largely unknown [Vatankhah A., et al., 2015].

The marked and persistent antigenic action of this parasitic agent is characterized by a major potential of causing an inflammatory reaction. The local reaction is quite varied, from severe granulomatous changes, associated with the degeneration of the cysts with their eventual death, to a collagenous capsule, derived from the resolution of the inflammation, correlated with a stable host-parasite relationship. The peculiarities of the inflammatory reactions in the pericystic tissues are decisive in the pathogenesis, clinical evolution and development of some complications of the disease [Breijo M. et al., 2008]. Control of *E. granulosus* infection is a complex process involving humoral and cellular components of the immune system, immune defense reactions against an extracellular pathogen being dependent on the interaction of macrophages with T lymphocytes [Baz A. et al., 2006, Zhang W. et al., 2008].

V. Conclusions:

1. In cases of pulmonary hydatid cyst complicated by endobronchial rupture, the hydatid metacestode is subjected to some partial necrolytic changes of the lamellar cuticle, with uneven reduction of lamellar structures, with characteristic signs of homogenization. However, in the early stages of the complication, in some areas, the partial viability of the parasitic elements (protoscolexes and daughter vesicles) and the germinal membrane is found, which partially preserves its properties of remultiplication, these properties being damaged with the passage of time.
2. Pulmonary hydatid cyst complicated by endobronchial rupture in children is characterized by granulomatous infiltrative inflammatory processes of the pericystic (adventitial) layer, with the association of necrotic degeneration changes, with the development of vascular thrombotic syndrome in the pericyst and the adjacent lung parenchyma and an acute granulocytic inflammatory process with eosinophilic component.
3. In the regions of the pericystic lung parenchyma of the pulmonary hydatid cyst complicated by endobronchial rupture, signs of pneumopathy are attested, manifested by granulomatous exulcerative bronchitis and micropapillomatous bronchiolitis, fibrinous and fibrino-leukocytic alveolitis, and the pleural area is characterized by mesothelial micropolypous inflammatory-proliferative phenomena. These morphopathological manifestations determine a major risk of developing complications, including the insufficiency of padding sutures, the persistence of bronchial fistulas, which can cause a long postoperative morbidity.
4. Along with the alterative-necrolytic changes of the parasitic structures and the significant inflammatory-destructive processes of the pericystic layer, some findings have been documented that indicate the possibility of the development of secondary parasitic cystic formations located in the pericystic tissues, which can determine a major risk of development of local recurrences after surgery.

Bibliography

- [1]. Abeb N.D., Al-Bayat N.Y. Effect of pulmonary metacestodes of echinococcus granulosus (hydatid cyst) infection on lung tissue of sheep and cow. *Biochem. Cell. Arch.* 2019. 19(2):3463-7.
- [2]. Agudelo Higuaita N.I., Brunetti E., McCloskey C. Cystic echinococcosis. *J Clin Microbiol.* 2016, 54:518-23.
- [3]. Almess M., Ahmad B., Darwish B. Intact and perforated pulmonary hydatid cyst: A comparative study from Damascus, Syria. *Korean J. Thorac Cardiovasc Surg.* 2020. 53(6):387-91.
- [4]. Amri M., Mezioug D., Touil-Boukoffa C. Involvement of IL-10 and IL-4 in evasion strategies of Echinococcus granulosus to host immune response. *Eur. Cytokine Netw.* 2009. 20:63-8.
- [5]. Ashour M.H., Hajjar V.M., Ishaq M., Alamassi M., Saleh W., Al Kattan K.M., Shoukri M. Pulmonary hydatid cysts: the naturally occurring models for rupture. *Asian Cardiovasc Thorac Ann.* 2016. 24(7):670-5.

- [6]. Ataja J., Hanifa H., Ismail A., Ismail Ad. Ruptured hydatid cyst presenting with a hydropneumothorax in a 16-year-old bou: A case report from Syria. *Int. J. Surg. Case Rep.* 2023. 105:108034. doi: 10.1016/j.ijscr.2023.108034.
- [7]. Aydin Y., Bilal Ulas A., Ahmed A.G., Eroglu A. Pulmonary hydatid cyst in children and adults: Diagnosis and management. *Eurasian J Med.* 2022, 54(Suppl. 1):S133-S140.
- [8]. Basika T., Munoz N., Casaravilla C., Irigoien F., Batthyany C., Bonilla M. et al. Phagocyte-specific S100 proteins in the local response to the *Echinococcus granulosus* larva. *Parasitol.* 2012. 139:271-83.
- [9]. Baz A., Ettlin G.M., Dematteis S. Complexity and function of cytokine responses in experimental infection by *Echinococcus granulosus*. *Immunobiology.* 2006. 211: 3-9.
- [10]. Bektas S., Erdogan N.Y., Sahin G., Kir G., Adas G. Clinicopathological findings of hydatid cyst disease: A retrospective analysis. *Ann. Clin. Pathol.* 2016. 4(3):1071.
- [11]. Breijo M., Anesetti G., Martinez L., Sim R.B., Ferrei A.M. *Echinococcus granulosus*: The establishment of the metacestode is associated with control of complement-mediated early inflammation. *Exp. Parasitol.* 2008. 118:188-96.
- [12]. Datta A., Goud S.M., Mohapatra P.R. Rupture pulmonary hydatid cyst. *J. Glob Infect Dis.* 2023. 15(1):35-6.
- [13]. Diaz A., Barrios A.A., Grezzi L., Mouhape C., Jenkin S.J., Allen J.E., Casaravilla C. Immunology of a unique biological structure: the *Echinococcus* Laminated layer. *Protein Cell.* 2023. 14:87-104.
- [14]. Diaz A., Casaravilla C., Alen J.E., Sim R.B., Ferreira A.M. Understanding the laminated layer of larval *Echinococcus* II: immunology. *Trends Parasitol.* 2011. 27(6):263-72.
- [15]. Diaz A., Fernandez C., Pittini A., Seoane P.I., Allen J.E., Casaravilla C. The laminated layer: Recent advances and insights into *Echinococcus* biology and evolution. *Exp. Parasitol.* 2015. 158:23-30.
- [16]. Golzari S.E.J., Sokouti M. Pericyst: the outermost layer of hydatid cyst. *World J. Gastroenterol.* 2014. 20(5):1377-8.
- [17]. Goussard P., Eber E., Mfingwana L., Nel P., Schubert P., Janson J. et al. Pediatric pulmonary echinococcosis: A neglected disease. *Pediatr Resp Rev.* 2022, 43:11-23.
- [18]. Hamouri S., Odat H., Svai S., Hecker E., Alrabadi N. Rupture of pulmonary hydatid cyst in pediatrics: A cross-sectional study. *Ann Med Surg (Lond).* 2021. 62:31-6.
- [19]. Hidalgo C., Stoores C., Strull K., Franco C., Corrêa F., Jimernez M., et al. New insights of the local immune response against both fertile and infertile hydatid cysts. *PLoS ONE.* 2019. 14(1): e0211542. <https://doi.org/10.1371/journal.pone.0211542>.
- [20]. Kabiri E.H., Hammoumi M.E., Kabiri M. Surgical treatment of hydatid thorax in children: A retrospective study of 19 patients. *J Pediatr Surg.* 2020. 55(3):433-6.
- [21]. Kabiri E.H., Kabiri M. Clinical features and treatment of bronchial rupture of pulmonary hydatid cyst in children: a retrospective study of 36 patients. *Gen Thorac Cardiovasc Surg.* 2021. 69(12):1539-44.
- [22]. Kanan J.H.C., Chain B.M. Modulation of dendritic cell differentiation and cytokine secretion by the hydatid cyst fluid of *Echinococcus granulosus*. *Immunology.* 2006. 118:271-8.
- [23]. Kayhan S., Akgunes A. Histopathologically diagnosed pulmonary complicated hydatid cyst cases. *Turk Parasitol derg.* 2011. 35(4):189-93.
- [24]. Khadidja H., Achour Y., Houcin B., Cozma V. Histological appearance of *Echinococcus granulosus* in the camel species in Algeria. *Bull. UASVM Vet. Med.* 2014. 71(1):79-84.
- [25]. Kocaman O.H., Gunendi T., Dere O., Dorterler M.E., Boleken M.E. Pulmonary hydatid cyst in children: A single-institution experience. *Cureus.* 2022. 14(7):e26670. doi: 10.7759/cureus.26670.
- [26]. Ksia A., Fredj M.B., Zouaoui A., Kechiche N., Belhassen S., Mosbahi S. et al. Capitonage seems better in childhood pulmonary hydatid cyst surgery. *J. Pediatr. Surg.* 2020. 55(4):752-5.
- [27]. Malla N., Mewara A. Human cystic echinococcosis with special reference to India – An overview. *Ann. Clin. Cytol. Pathol.* 2016. 2(5): 1038.
- [28]. Mifsud S., Schembri E.L., Gauci J., Mizzi A., Azzopardi C.M., Micallef J. The non-resolving lung cavity: a case of pulmonary cystic echinococcosis. *BMJ Case Rep.* 2017. 2017: bcr2017220909. doi: 10.1136/bcr-2017-220909.
- [29]. Miman O., Atambay M., Aydin N.E., Daldal N. Necrosis in human cystic echinococcosis: an underrecognized tissue reaction possibly related to host response. *Turk J. Med. Sci.* 2009. 39 (2):203-7.
- [30]. Mohammed A., Malki K., Mellagui Y., Bkiyar H., Housni B. Anaphylactic shock due to traumatic rupture of pulmonary hydatid cyst: Case report. *Int J Surg Case Rep.* 2021. 81:105660. doi: 10.1016/j.ijscr.2021.105660.
- [31]. Molyneaux P.L., Maher T.M. The role of infection in the pathogenesis of idiopathic pulmonary fibrosis. *Eur. Resp. Rev.* 2013. 22:376-81. DOI:1183/09059180.00000713376.
- [32]. Murray P.J., Wynn T.A. Protective and pathogenic functions of macrophage subsets. *Nat. Rev. Immunol.* 2011. 11(11):723-37.
- [33]. Nabi M.S., Waseem T. Pulmonary hydatid disease: What is the optimal surgical strategy? *Int. J. Surg.* 2010. 8:612-61.
- [34]. Nasr B., Al Junaeed A., Al Sady G., Al Shehari A., Amri A., Issa M. et al. Lung hydatid cysts in children, evaluation and surgical management. *J. Cancer Sci Clin Ther.* 2023. 7:25-38.
- [35]. Ozdemir A., Bozdemir S.E., Akbiyik D., Daar G., Korkut S., Korkmaz L., Bastug O. Anaphylaxis due to ruptured pulmonary hydatid cyst in a 13-year-old boy. *Asia Pac Allergy.* 2015. 5(2):128-31.
- [36]. Ozdemir T., Sayan A., Candan B., Koyluoglu G. Clinical features and treatment of ruptured pulmonary hydatid cyst in children. *Turk J Pediatr.* 2020. 62(4):578-83.
- [37]. Reinehr M., Micheloud C., Grimm F., Kronenberg Ph.A., Grimm J., Beck A. et al. Pathology of echinococcosis: a morphologic and immunohistochemical study on 138 specimens with focus on the differential diagnosis between cystic and alveolar echinococcosis. *Am. J. Surg. Pathol.* 2020. 44:43-54.
- [38]. Sakamoto T., Cabrera P.A. Immunohistochemical observations on cellular response in unilocular hydatid lesions and lymph nodes of cattle. *Acta Trop.* 2003. 85(2):271-9.
- [39]. Salman H., Salman Z., Kart Y., Akcam M. Cystic Echinococcosis in Children: Ten Years of Experience and Which Laboratory Results are Significant in the Evaluation of Ruptured Cases? *J. Contemp. Med.* 2023, 13(1)54-9. Doi :10.16899/jcm.
- [40]. Seoane P.I., Ruckerl D., Casaravilla C., Barrios A.A., Pittini A. et al. Particles from the *Echinococcus granulosus* laminated layer inhibit IL-4 and growth factor-driven Akt phosphorylation and proliferative responses in macrophages. *Sci. Rep.* 2016. 6:39204. <https://doi.org/10.1038/srep39204>.
- [41]. Siracusano A., Margutti P., Delunardo F., Profumo E., Rigano R. et al. Molecular cross-talk in host-parasite relationships: The intriguing immunomodulatory role of *Echinococcus* antigen B in cystic echinococcosis. *Int. J. Parasitol.* 2008. 38:1371-6.
- [42]. Tager A.M., Shea B.S., Selman M., Zhao Z., Polosukhin V. et al. The lysophosphatidic acid receptor LPA1 links pulmonary fibrosis to lung injury by mediating fibroblast recruitment and vascular leak. *Nat. Med.* 2008.14:45-54.
- [43]. Thompson R.C. Biology and Systematics of *Echinococcus*. *Adv. Parasitol.* 2017. 95:65-109.

- [44]. Türkoğlu E., Demirtürk N., Tünay H., Akıcı M., Öz G., Embleton D.B. Evaluation of patients with cystic echinococcosis. *Turkiye Parazitol. Derg.* 2017. 41:28-33.
- [45]. Vatankhah A., Halász J., Piurkó V., Barbai T., Rásó E., Tímár J. Characterization of the inflammatory cell infiltrate and expression of costimulatory molecules in chronic echinococcus granulosus infection of the human liver. *BMC Inf. Dis.* 2015. 15:530. DOI 10.1186/s12879-015-1252-x.
- [46]. Virginio V.G., Monteiro K.M. Drumond F., de Carvalho M.O., Vargas D.M. et al. Excretory/secretory products from in vitro-cultured *Echinococcus granulosus* protoscoleces. *Mol. Biochem. Parasitol.* 2012. 183:15-22.
- [47]. Vuitton D.A., McManus D.P., Rogan M.T., Romig T., Gottstein B., Naidich A. et al. International consensus on terminology to be used in the field of echinococcus. *Parasite.* 2020. 27:41. doi: 10.1051/parasite/2020024.
- [48]. Wynn T.A., Barron L. Macrophages: master regulators of inflammation and fibrosis. *Semin. Liver Dis.* 2010. 30:245-57.
- [49]. Wynn T.A., Ramalingam T.R. Mechanisms of fibrosis: therapeutic translation for fibrotic disease. *Nat Med* 2012. 18:1028-40.
- [50]. Zakariaei Z., Fakhari M., Sharifpour A., Banimostafavi F.S., Soleymani M., Zakariaei A. Anaphylactic shock due to ruptured pulmonary hydatid cyst in a young patient from Iran. *Ann Med Surg (Lond).* 2021. 68:102675. doi: 10.1016/j.amsu.2021.102675.
- [51]. Zhang W., Ross A.G., McManus D.P. Mechanisms of immunity in hydatid disease: Implications for vaccine development. *J. Immunol.* 2008. 181:6679-85.