

MRI Evaluation for Post-Traumatic Knee Joint Injuries

Ikhlas O. Saeed

¹(Diagnostic Radiology Department, Faculty of Applied Medical Sciences / King Abdulaziz University, KSA)

Corresponding Author: Ikhlas O. Saeed

Abstract : Living with healthy knee joint makes life beautiful, enjoyable and enables to fulfill many dreams that cannot be achieved in the presence of pain that accompanies the traumatic injuries and other knee joint diseases. The aim of this study was to find out the diagnostic value of Magnetic Resonance Imaging (MRI) in the evaluation of post-traumatic knee joint condition. 85 traumatic patient subjected to (MRI) were evaluated retrospectively, data was collected between (2014) and (2015). There was 26 females and 59 males, age range, (13-68) years with a mean age of (2.96). A total number of (85) patients complaining of trauma related knee joint, 6 patients (7.1%) were evaluated with normal MRI findings and 79 patients (93.1%) with abnormal findings. Among the 79 patients who had knee injuries, 20 patients (23.5%) had ACL, following 17 patients (20,1%) had meniscal tears, 14 patients (16.5%) had MCL, 10 patients (11.8%) had kneecap fractures, 6 patients (7.1%) had PCL, 5 patients (5.9%) had tendon tears, 4 patients (4.7%) had kneecap dislocation and 3 patients (3.5%) were diagnosed with sprains.

Keywords : MRI, Knee Injuries, Meniscal Tear, Anterior Cruciate Ligament

Date of Submission: 27-03-2018

Date of acceptance: 12-04-2018

I. Introduction

Knee joint is the largest joint in the human body[1]. It is a synovial hing joint type which allows different types of movement; flexion,extension,external and internal rotation [2,3]. Knee joint responsible for movement and weight-bearing. It consists of bones (femur, tibia and patella), ligaments (anterior cruciate ligament, posterior cruciate ligament, medial and lateral collateral ligament), tendons (patellar tendon is the largest), and meniscus (medial and lateral meniscus act as cushion)[4]. Recreational sport activities are risk factors for knee injury and serious injury caused by direct blow to the knee requires immediate medical attention[4].The anterior cruciate ligament is frequently injured by trauma and victims athletes. In the United States there are between 100,000 and 200,000 ACL ruptures per year[5,6]. The estimated incidence of meniscal tears in some Northern European countries is 2 per 1000 person-years[7]. A study by England et al., found that 35% of enrolled patients older than 50 years old had imaging evidence of a meniscal tear, with ⅓ of these patients being asymptomatic[8]. Medial collateral ligament injuries often happen in sports, it represents 60% of skiing knee injuries[9].

Early detection of knee injuries is extremely important to prevent long-term consequences of delayed treatment [10]. The primary imaging modality for traumatic injuries is Radiography, it is used to detect the onset of joint degeneration post trauma[11,12]. Computed tomography arthrography (CTA) of the knee is a safe technique that provides an accurate diagnosis of meniscal and cartilage injuries in patients with contraindication to MRI [13]. Magnetic resonance imaging is the less invasive method and most accurate for diagnosing meniscal lesions and eliminates unnecessary arthroscopies [14,15]. The aim of this work was to find out the diagnostic value of Magnetic Resonance Imaging in patients injured in the knee joint after the trauma.

II. Material And Methods

This study was conducted at King Abdul Aziz University Hospital in order to determine the diagnostic value of magnetic resonance imaging technology in the evaluation of patients who were subjected to trauma that had a significant impact on their knee joint through the years 2014 and 2015. A retrospective search of hospital database was conducted for eighty-five (85) patients (59 male and 26 female) with a knee joint injury, the age of patient ranged between (13-68)years with a mean age of (2.96) . Pain was the most common symptom among the study group. All patients were subjected to magnetic resonance imaging using 3 Tesla MRI system(Magnetom verio, Siemens Medical systems, Erlangen, Germany) with a dedicated knee coil for Knee joint imaging.

2.1 KNEE JOINT IMAGING PROTOCOL AT (KAUH)

The first sequence is proton density , axial - fast spin-echo (TR/TE: 2000 / 23 flip angle,150°; field of view, 180 mm; matrix, 256 ; slice thickness, 3.0 mm) ; and axial - fast spin-echo T1-weighted (TR/TE: 614 /9.5 ; flip angle,90° ; field of view, 180 mm; matrix, 320; slice thickness, 3.0 mm; and proton density. sagittal ,T2-weighted (TR/TE: 2500 /26 ; flip angle,150° ; field of view, 170 mm; matrix, 320; slice thickness, 3.0 mm) ; and proton density. sagittal , fast spin-echo – fat suppression (TR/TE: 2400 /23 ; flip angle,150° ; field of view, 170 mm; matrix, 320; slice thickness, 3.0 mm) ; and fast spin-echo. sagittal - T1 (TR/TE: 2400 /23 ; flip angle,150° ; field of view, 170 mm; matrix, 320; slice thickness, 3.0 mm) ; and proton density. fast spin-echo , coronal- T2- weighted (TR/TE: 3160 /32 ; flip angle,150° ; field of view, 170 mm; matrix, 320; slice thickness, 3.0 mm) ; and sagittal - T1 - T1 (TR/TE: 3710 /40 ; flip angle,150° ; field of view, 170 mm; matrix, 320; slice thickness, 3.0 mm) ; and proton density. fast spin-echo - fat suppression - coronal (TR/TE: 3050 /41 ; flip angle,150° ; field of view, 170 mm; matrix, 320; slice thickness, 3.0 mm) ; then, proton density. fast spin-echo sagittal -T2 (TR/TE: 2380 /26 ; flip angle,150° ; field of view, 170 mm; matrix, 320; slice thickness, 1.5 mm) for meniscus tear.

2.2 STATISTICS

Data was analyzed using SPSS version 19 and MRI results of the group of patients participating in the study were reviewed by skillful radiologists who have interesting in musculoskeletal medical imaging and the results were presented accordingly.

III. Result

My study included eighty five (85) patients complaining of trauma related knee joint, out of these; 6 patients (7.1%) showed normal MRI findings and 79 patients (93.1%) with abnormal findings. Among the 79 patients who had knee injuries, 20 patients (23.5%) had ACL, followed by 17 patients (20,1%) had meniscal tears (medial and lateral) including Grade I, Grade II, Grade III and complex tear, then come MCL 14 patients (16.5%), 10 patients (11.8%) had kneecap fractures, 6 patients (7.1%) had PCL, 5 patients (5.9%) had tendon tears, 4 patients (4.7%) had kneecap dislocation and 3 patients (3.5%) diagnosed with sprains. (Table 3 and Fig. 3). It is noted that I did not use a gold standard in this retrospective study and MRI was the gold standard for itself to evaluate and determine the effectiveness of this technology in post-traumatic knee joint at King Abdul-Aziz University Hospital.

IV. Discussion

The current retrospective study was focused on the effectiveness of MRI in assessing and diagnosing the post-traumatic knee joint. From my result; the age group of (26-46)years was the more affected group with frequency of 33 (38.8%), followed by age group (15-25)years with frequency of 25 (29.4%), then a frequency of 24 (28.2%) for age group of (47-67). The age groups of (<15) and (>67) were the least with frequency of 2 (2.4%) and one (1.2%) respectively. (Table 1) This result reflects that the activity is increased at these range of age (26-46) and (15-25)years, causing many problems related to knee joint compared to the rest of the ages that recorded a lower rate. (Table 2) shows that the number of male patients 59 (69.4%) injured in the knee joint was higher than the number of female patients 26(30.6%) although some studies reported the opposite.

Out of eighty-five patients complaining of trauma related knee joint, seventy- nine (93.1%), had a positive MRI findings and only 6 patients (7.1%) had normal result. Anterior cruciate ligament (ACL) was the most injured ligament 20 patients (23.5%), this result was in agreement with Junkin DM. et al (2009) who stated that the anterior cruciate ligament is one of the most frequently injured ligaments of the knee[16]. Comes second meniscal tears 17 patients (20,1%) ranging from Grade I to Grade III and complex tear, followed by MCL 14 patients (16.5%), 10 patients (11.8%) had kneecap fractures, 6 patients (7.1%) had PCL, 5 patients (5.9%) had tendon tears, 4 patients (4.7%) had kneecap dislocation while 3 patients (3.5%) diagnosed with sprains. (Table 3 and Fig. 3). My results reflects that MRI was the best modality in evaluation of post-traumatic knee joint condition. Hetta, W. and Niazi, G.(2014) concluded that; MRI represents the optimal imaging tool in the evaluation of the sports related knee injuries, it is an accurate method of diagnosing meniscal, ligament, cartilage and muscles of injured knee [17]. P.W. Vincken et al (2007) reported; MRI is a well-accepted imaging modality in the patient with knee problems and has mostly replaced arthroscopy[18]. Also C.J. Standaert and S.A. Herring (2009) mentioned; Magnetic resonance imaging, with its multi-planar capabilities and excellent soft-tissue contrast, is a leading modality for evaluation of the sports knee injuries[19]. Other authors concluded ; MRI has high accuracy in detection of cruciate ligament tears, meniscal tears [20, 21, 22, 23] and Collateral ligamentous injuries [24, 25]. It is clear from the previous studies in this field that all authors agree that MRI is the best technology for evaluation and diagnosis of knee joint, especially after the trauma.

V. Figures And Tables

TABLE 1: Distribution of patient according to age

		Frequency	Percent	Valid Percent	Cumulative Percent
Valid	<15	2	2.4	2.4	2.4
	15-25	25	29.4	29.4	31.8
	26-46	33	38.8	38.8	70.6
	47-67	24	28.2	28.2	98.8
	>67	1	1.2	1.2	100.0
Total		85	100.0	100.0	

TABLE 2: Distribution of patient according to gender

		Frequency	Percent	Valid Percent	Cumulative Percent
Valid	Male	59	69.4	69.4	69.4
	Female	26	30.6	30.6	100.0
	Total	85	100.0	100.0	

TABLE 3: Distribution of patients according to MRI Results

		Frequency	Percent	Valid Percent	Cumulative Percent
Valid	MM tear Grade III	5	5.9	5.9	5.9
	MM tear-Grade I	5	5.9	5.9	11.8
	LM tear-Grade III	3	3.5	3.5	15.3
	LM tear-Grade I	1	1.2	1.2	16.5
	MM tear-Grade II	1	1.2	1.2	17.6
	MM complex tear	2	2.4	2.4	20.0
	Tendon tears	5	5.9	5.9	25.9
	Sprains	3	3.5	3.5	29.4
	Kneecap fracture	10	11.8	11.8	41.2
	ACL	20	23.5	23.5	64.7
	PCL	6	7.1	7.1	71.8
	MCL	14	16.5	16.5	88.2
	Kneecap dislocation	4	4.7	4.7	92.9
	Normal knee	6	7.1	7.1	100.0
Total		85	100.0	100.0	

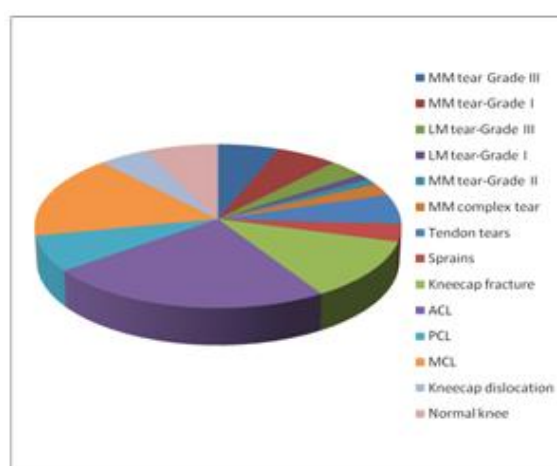


Fig. 3. Distribution of patients according to MRI Results

VI. Conclusion

After the analysis and results of this retrospective study and comparison with other the previous studies have been made in this field I can say with confidence that Magnetic resonance imaging (MRI) comes in the head of medical imaging and is the best way to diagnose and evaluate the condition of the knee joint after injury.

References

- [1]. Kulowski, Jacob (July 1932). "Flexion contracture of the knee". *The Journal of Bone and Joint Surgery*. 14 (3): 618–63. Republished as: Kulowski, J (2007). "Flexion contracture of the knee: The mechanics of the muscular contracture and the tumbuckle cast method of treatment; with a review of fifty-five cases. 1932". *Clinical orthopaedics and related research*. 464: 4–10. doi:10.1097/BLO.0b013e31815760ca (inactive 2017-01-15). PMID 17975372. Lensing AW, Prandoni P, Prins MH, Buller HR. Deep-vein thrombosis. *Lancet* 1999; 353:479-485.
- [2]. Rytter, Søren; Egund, Niels; Jensen, Lilli; Bonde, Jens (2009). "Occupational kneeling and radiographic tibiofemoral and patellofemoral osteoarthritis". *Journal of Occupational Medicine and Toxicology*. 4: 19. doi:10.1186/1745-6673-4-19. PMC 2726153. PMID 19594940.
- [3]. Jump up ^ Gill, T. J.; Van De Velde, S. K.; Wing, D. W.; Oh, L. S.; Hosseini, A.; Li, G. (2009). "Tibiofemoral and Patellofemoral Kinematics After Reconstruction of an Isolated Posterior Cruciate Ligament Injury: In Vivo Analysis During Lunge". *The American Journal of Sports Medicine*. 37 (12): 2377–85. doi:10.1177/0363546509341829. PMC 3832057 PMID 19726621.
- [4]. NP, Kathleen Davis. "How to prevent and treat knee injuries." *Medical News Today*. MediLexicon, Intl., 18 Aug. 2017. Web.
- [5]. Gordon MD, Steiner ME.. Anterior cruciate ligament injuries. In: *Orthopaedic Knowledge Update Sports Medicine III*, Garrick JG (Ed), American Academy of Orthopaedic Surgeons, Rosemont 2004. p.169.
- [6]. Albright JC, Carpenter JE, Graf BK, et al.. Knee and leg: soft tissue trauma. In: *Orthopaedic Knowledge Update 6*, Beaty JH (Ed), American Academy of Orthopaedic Surgeons, Rosemont 1999. p.533.
- [7]. Bhattacharyya T, Gale D, Dewire P, Totterman S, Gale M. E, McLaughlin S, Einhorn T, et al. (2003). The clinical importance of meniscal tears demonstrated by magnetic resonance imaging in osteoarthritis of the knee. *The JBJS. American volume*, 85-A, 4-9.
- [8]. Englund M, Guermazi A, Gale D, Hunter D.J, Aliabadi P, Clancy M, Felson D. (2008). Incidental meniscal findings on knee MRI in middle-aged and elderly persons. *N Engl J Med*, 359(11), 1108-1115.
- [9]. Dale KM, Bailey JR, Moorman CT. Surgical Management and Treatment of the Anterior Cruciate Ligament/Medial Collateral Ligament Injured Knee. *Clin Sports Med*. 2017 Jan;36(1):87-103. [PubMed: 27871663]
- [10]. T.H. Matherne, J.U. Monu, L. Schruoff, H.R. Neitzschman Avulsions around the knee portend instability *Emerg Radiol*, 11 (2005), pp. 213-218
- [11]. Gillquist, K. Messner Anterior cruciate ligament reconstruction and the long-term incidence of gonarthrosis *Sports Med*, 27 (1999), pp. 143-156
- [12]. M. Englund, E.M. Roos, L.S. Lohmander Impact of type of meniscal tear on radiographic and symptomatic knee osteoarthritis: a sixteen-year follow up of meniscectomy with matched controls *Arthritis Rheum*, 48 (2003), pp. 2178-2187
- [13]. M. De Filippo, A. Bertellini, F. Pogliacomi et al., "Multidetector computed tomography arthrography of the knee: diagnostic accuracy and indications," *European Journal of Radiology*, vol. 70, no. 2, pp. 342–351, 2009.
- [14]. B. K. Harrison, B. E. Abell, and T. W. Gibson, "The thessaly test for detection of meniscal tears: validation of a new physical examination technique for primary care medicine," *Clinical Journal of Sport Medicine*, vol. 19, no. 1, pp. 9–12, 2009.
- [15]. D. A. Rubin and G. A. Paletta Jr., "Current concepts and controversies in meniscal imaging," *Magnetic Resonance Imaging Clinics of North America*, vol. 8, no. 2, pp. 243–270, 2000.
- [16]. Junkin DM, Johnson DL, Fu FH, et al. Knee Ligament Injuries. In: Kibler WB, editor. *Orthopaedic Knowledge Update 4: Sports Medicine*. Rosemont: American Academy of Orthopaedic Surgeons; 2009. pp. 135–153.
- [17]. Hetta W., Niazi G. MRI in assessment of sports related knee injuries. *Egyptian Journal of Radiology and Nuclear Medicine*, Volume 45, Issue 4, December 2014
- [18]. P.W. Vincken, A.P. Ter Braak, A.R. Van Erkel, et al. MR imaging: effectiveness and costs at triage of patients with nonacute knee symptoms *Radiology*, 242 (1) (2007), pp. 85-93
- [19]. C.J. Standaert, S.A. Herring. Expert opinion and controversies in musculoskeletal and sports medicine: stingers *Arch Phys Med Rehabil*, 90 (2009), pp. 402-406
- [20]. Crawford R, Walley G, Bridgman S, Maffulli N. Magnetic resonance imaging versus arthroscopy in the diagnosis of knee pathology, concentrating on meniscal lesions and ACL tears: a systematic review. *Br Med Bull*. 2007;84(1):5-23.
- [21]. Oei EHG, Nikken JJ, Verstijnen ACM, Ginai AZ, Hunink MGM. MR imaging of the menisci and cruciate ligaments: a systematic review. *Radiology*. 2003;226(3):837-48.
- [22]. Fischer SP, Fox JM, Del Pizzo W, Friedman MJ, Snyder SJ, Ferkel RD. Accuracy of diagnoses from magnetic resonance imaging of the knee. A multi-center analysis of one thousand and fourteen patients. *J Bone Joint Surg Am*. 1991;73(1):2-10.
- [23]. Munk B, Madsen F, Lundorf E, Staunstrup H, Schmidt SA, Bolvig L, et al. Clinical magnetic resonance imaging and arthroscopic findings in knees: a comparative prospective study of meniscus anterior cruciate ligament and cartilage lesions. *Arthroscopy*. 1998;14(2):171-5.
- [24]. Rubin DA, Kettering JM, Towers JD, Britton CA. MR imaging of knees having isolated and combined ligament injuries. *AJR Am J Roentgenol*. 1998;170(5):1207-13.
- [25]. Rasenberg EI, Lemmens JA, van Kampen A, Schoots F, Bloo HJ, Wagemakers HP, et al. Grading medial collateral ligament injury: comparison of MR imaging and instrumented valgus-varus laxity test-device. A prospective double-blind patient study. *Eur J Radiol*. 1995;21(1):18-24.

Ikhlas O. Saeed. "MRI Evaluation For Post-Traumatic Knee Joint Injuries". *IOSR Journal of Nursing and Health Science (IOSR-JNHS)*, vol. 7, no.2, 2018, pp. 48-51.