

## Role of Selenium and Vitamin E on Gastric Mucosal Damage Induced By Water-Immersion Restraint Stress in Wistar Rats

Sadau, Y. \*, Adelaiye, A.B. <sup>1</sup>, Magaji, R.A. <sup>1</sup>, Ayo, J.O. <sup>2</sup>, Mabrouk, M.A. <sup>3</sup>  
And Isa, A.I. <sup>1</sup>

\* Department of Human Physiology, College of Medical Sciences, Gombe State University, Gombe, Nigeria.

<sup>1</sup> Department of Human Physiology, Ahmadu Bello University, Zaria, Nigeria.

<sup>2</sup> Department of Veterinary Physiology and Pharmacology, Ahmadu Bello University, Zaria, Nigeria.

<sup>3</sup> Department of Human Physiology, Bayero University, Kano, Nigeria.

---

**Abstract:** The aim of the present study was to determine the effect of selenium and vitamin E on gastric mucosal damage and acid secretion induced water immersion restraint stress (WRS) in Wistar rats. (n= 70) Wistar rats of both sexes, weighing 200-220 g were divided in to five groups of seven rats each, viz: (i) passive control (non-stress rats), (ii) active control (WRS + distilled water), (iii) WRS + vitamin E, (iv) WRS + vitamin E + selenium, and (v) WRS + selenium. The WRS procedure lasted for 3.5 hours. Gastric tissues were isolated and investigated macroscopically and histologically to determine mucosal damage. Gastric secretion was collected after additional 3 hours of pyloric ligation. Blood samples were collected through cardiac puncture for the investigation of plasma concentration of malondialdehyde (MDA). The result demonstrated that acute WRS significantly ( $P < 0.001$ ) increase gastric ulcer and gastric secretion parameters as well as MDA concentration. Pre-treatment with selenium or vitamin E significantly lowered the gastric parameters and MDA concentration especially in rats co-administered with selenium and vitamin E. It was concluded that acute WRS exposure causes significant alteration in the structure of the gastric tissue and increased plasma MDA. Pre-treatment with selenium and vitamin E ameliorated the adverse effects of WRS, and co-administration of selenium and vitamin E exerted synergistic effects in the restoration of WRS-induced changes.

**Keywords:** gastric tissue, malondialdehyde, mucosal damage, stress, selenium, vitamin E, water immersion,

---

### I. Introduction

Stress is an aversive stimulus which disturbs physiological homeostasis [1]. It induces the strain upon both emotional and physical endurance, which has been considered the basic factor in the aetiology of a number of diseases [2]. A stress response is a natural reaction by the body against potentially harmful stimuli to enhance the chance for survival [3]. Serious stress can induce organ injury or contribute to diseases, such as gastric ulcers, hypertension, diabetes mellitus and cancer. The stomach is one of the main targets of stress. Stress-induced gastric ulceration is a typical example of stress-associated organ injuries [1]. It is an easy and convenient method to induce both psychological and physical stress. Water-immersion restraint stress (WRS) mimics the clinical acute gastric ulceration, caused by trauma, surgery or sepsis and has been widely accepted for studying stress ulceration [4, and 5]. Both psychological and physiological responses occur during WRS, and are involved in the pathogenesis of gastric ulceration. The psychological responses include anxiety, depression, helplessness, fear and threat of drowning. The physiological responses are neuro-hormonal and immunological activations, involving corticotrophin-releasing factor. These two systems may interact during stressful challenges [6]. One known pathological stress-induced condition is the formation of gastric lesion, and studies have shown that its pathogenesis is multifactorial. It includes factors which disrupt the gastric mucosal integrity such as changes in gastric acid, mucus and bicarbonate secretions, inhibition of gastric mucosal prostaglandin synthesis reduction in gastric mucosal blood flow, and changes in stress hormones and gastric motility [7, 8, and 9]. During stress, there is increased generation of reactive oxygen species (ROS), associated with oxidative stress [10]. The ROS damage cell membranes via lipid peroxidation [10]. Lipid peroxidation generates a variety of relatively stable decomposition end-products, mainly  $\alpha$ ,  $\beta$ -unsaturated reactive aldehydes, such as malondialdehyde (MDA). Selenium (Se) is an essential trace element and its low status in human has been linked to increased risk of various diseases, such as cancer and heart diseases. Since its discovery as an important component of antioxidant enzymes such as glutathione peroxidase (GPx), there has been an increased interest in the study of other Se-containing proteins (selenoproteins) or enzymes (seleno-enzymes) [11]. Selenium prevents reperfusion induced gastric mucosal lesion, intraluminal bleeding and depletion of non-protein sulphhydryl level in the rat stomach. It therefore plays an antioxidant role to protect tissue against oxidative stress [12]. Vitamin E is group of eight antioxidant lipophilic molecules, four of which are tocopherols and four are tocotrienols. It is mostly found in green vegetables, grains, nuts and various vegetable oils, as well

as in eggs and milk. Vitamin E is known to possess many biological properties, including antioxidant activity to modulate protein function and gene expression. Vitamin E ( $\alpha$ -tocopherol) is a lipid-soluble antioxidant and a well-accepted first line defence mechanism against lipid peroxidation. It functions as a chain-breaking antioxidant for lipid peroxidation in cell membranes and as a scavenger of ROS such as superoxide anion, hydrogen peroxide and single oxygen [8]. Yoshikwa et al. [13] reported a decrease in gastric mucosal vitamin E level and an increase in gastric mucosal lipid peroxidation in ischaemia - reperfusion - induced gastric mucosal injury and the severity of the injury was enhanced in vitamin E deficient rats.

The aim of the present study was to investigate the role of selenium and vitamin E on gastric mucosal damage, and acid secretion due to water immersion restraint stress.

## **II. Materials And Methods**

### **2.1 Experimental Animals**

Seventy (70) Wistar rats of both sexes weighing 200-220 g purchased from the Department of Pharmacology, Ahmadu Bello University, Zaria, were used in the study. They were fed standard laboratory diet and given access to drinking water ad libitum. Fourty eight hours before the induction of stress, the animals were deprived of food to allow for complete gastric emptying, but they were given access to water ad libitum. Procedure has been proven to be non-ulcerogenic and sufficient for absolute emptying of the stomach [14]. During fasting, rats were housed each in separate cage with a wide-raised, mesh bottom to prevent coprophagy [15]. This study was conducted in accordance with internationally accepted principles for laboratory animal use and care.

### **2.2 Chemicals**

The antioxidants, sodium selenite pentahydrate ( $\text{Na}_2\text{SeO}_3 \cdot 5\text{H}_2\text{O}$ ), and  $\alpha$ -tocopherol (vitamin E) in the study were of analytical grade, and were purchased from Sigma (chemical Co. (St. Louis, MO, USA), delivered by Zayo – Sigma, Jos, Nigeria.

### **2.3 Experimental Design**

The rats were anaesthetized with chloroform by inhalation and were kept conscious during the experiment. There after no additional anaesthetic was applied. The four limbs of each rat were bound on a wooden board (25 cm x 19 cm) with upper limbs anchored at horizontal position, and the lower limbs extended downwards as reported by Shu et al. [15] in WRS group, the animals were restrained after recovery from the anaesthesia, and the anchored plate were immersed to the level of xiphoid process vertically (head up) in water bath thermostatically-controlled at  $23 \pm 0.5^\circ\text{C}$  [15]. The stress procedure lasted for 3.5 hours. The animals were subdivided into five groups of seven rats each as follows:-

Group I: Passive control animals (unstressed control)

Group II: Animals received distilled water as the vehicle at 5 ml/kg body weight orally for 3 days + WRS (active control).

Group III: WRS + vitamin E (250mg/Kg body weight) orally for 3 days [16].

Group IV: WRS + selenium pentahydrate (100 $\mu\text{g}$  / Kg body weight) orally for 3 days [22].

Group V: WRS + vitamin E + selenium pentahydrate for 3 days.

At the end of this experimental procedure, animals were released from the plate and anaesthetized.

### **2.4 Assessment of Lipid Peroxidation**

Lipid peroxidation as evidenced by the formation of thiobarbituric acid reactive substances (TBARS) was measured by the modified method of Niehaus and Samuel as described by Akanji et al. [17].

Briefly to 150  $\mu\text{L}$  of serum was treated with 2 mL of (1:1:1 ratio) TBA-TCA-HCl reagent (thiobarbituric acid 0.37%, 0.25N HCl and 15% TCA) and placed in water bath for 1 hour at  $90^\circ\text{C}$ . The mixture was cooled and centrifuge at 1000 x g for 10 minutes at  $4^\circ\text{C}$ . The absorbance of the pink supernatant (2.0 ml) was measured against reference blank using a spectrophotometer (Jenwey, model number 6405uv/vis) at 535nm. The MDA was calculated using the molar extinction coefficient of  $1.56 \times 10^5 \text{cm}^{-1}\text{M}^{-1}$ . MDA concentration = absorbance /  $1.56 \times 10^5 \text{cm}^{-1}\text{M}^{-1} \times 1$ .

### **2.5 Evaluation of Gastric Mucosal Lesion**

After the stress procedure, rats were released from the plate and sacrificed under chloroform anaesthesia [15]. The stomach was then harvested and opened along lesser curvature. The severity of mucosal lesions was grossly inspected and photographed. Gastric tissue was fixed in 10% formalin, dehydrated and embedded in paraffin wax. Paraffin section of 5  $\mu\text{m}$  was cut and stained with haematoxylin and eosin. Histological changes were examined under a light microscope. Ulcer index was determined as follows: To score the extent of ulceration an arbitrary scales, were used which are highly subjective and hence carried out by blind

observers; that is, those who were unaware of the experimental protocols. Severity of ulcers was scored with a stereo-zoom microscope and using arbitrary scoring system as described by Shawon and Gautam [18].

- Shedding of epithelium = 10
- Petechial and frank haemorrhage = 20
- One or two ulcers = 30
- More than two ulcers = 40
- Perforated ulcers = 50

An ulcer index (UI) is calculated:

$$UI = UN + US + UP \times 10 - 1$$

Where:

UN = Average number of ulcers per animal.

US = Average of severity score

UP = Percentage of animals with ulcers

Percentage protection is calculated as:

$$\text{Percentage protection} = \frac{C - T}{C} \times 100$$

Where:

C = Mean severity of ulcer score in control group.

T = Mean severity of ulcer score in treated group

## 2.6 Measurement of Gastric Acid Secretion

To avoid interrupting the development and observation of gastric erosion, additional rats were used to measure gastric secretion parameters, which included: volume, titratable acidity and total acid output. Collection of gastric secretion was performed according to the method of Reymond et al. [19]. The rats were anaesthetized using a light chloroform atmosphere. An abdominal incision of about 2.5 cm from below the xiphisternum was carried out, and the stomach was brought into view by gentle traction on the omentum. Thereafter, pyloric ligation was done using a curved needle, attached to a silk thread size 0 or 1. The needle was passed along the upper border of pylorus behind its posterior surface, avoiding the gastro-duodenal artery, and passed out on its lower border, where it crossed the omentum. The ligature was applied to close the pylorus, without crushing its wall. The abdomen was closed by silk sutures, and rats were placed in the same cage and received neither food nor water. After three hours, the rats were sacrificed, and the abdomen was re-opened by removal of the silk sutures. Measurement of gastric acidity was carried following the method described by Shay et al. [20]. The junction between the stomach and the oesophagus, and that of the duodenum and pylorus were secured before the stomach was isolated. Then, 3 mL of distilled water was introduced into the stomach and the organ was carefully shaken. The gastric juice was collected and centrifuged for at 1000 x g for 10 minutes. The supernatant was taken and diluted 10 times. Thereafter few drops of phenolphthalein were added to the solution. Titration was done using 0.01M NaOH solution until the colour of the test solution changed to light pink, indicating pH 7.0 The volume of NaOH needed for titration was used in the calculation to derive the hydrogen ion concentration [20].

## 2.7 Analysis of Gastric Juice

**Volume:** After the centrifugation, the supernatant was measured as the volume of the gastric juice [14].

**Titratable acidity:** A given volume of the gastric juice was titrated against 0.01N NaOH using an end point of pH 7.0, with phenol red as an indicator [14]. It was calculated as milliequivalent per liter (mEq/L) which is equal to the number of milliliters (mL) of 0.01N NaOH required to neutralize 100 mL of the gastric juice [20].

$$\text{Titratable acidity} = \frac{\text{Volume of 0.01N NaOH which neutralized 1 mL of gastric juice} \times 100}{10}$$

**Acid output:** This was calculated as  $\mu\text{Eq/h}$  by multiplying the volume of gastric secretion (mL/h) of rat by the titratable acidity (acid concentration) (mEq/L) of the gastric secretion in the animal [14].

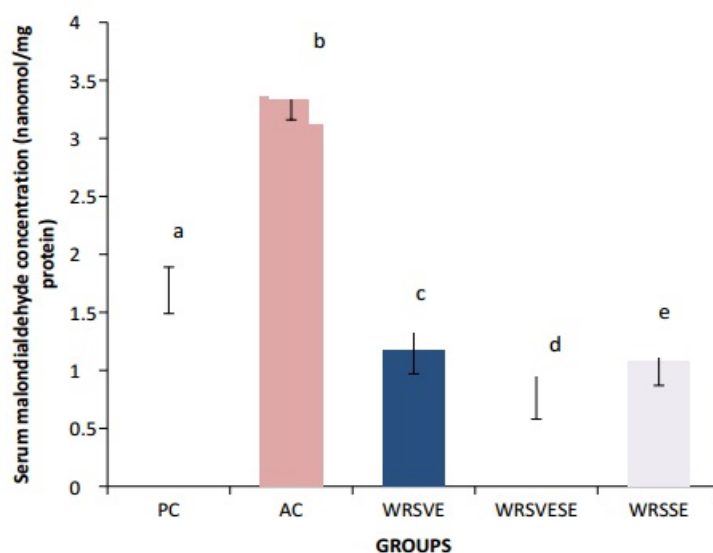
## 2.8 Statistical Analyses

Data obtained are expressed as mean  $\pm$  S.E.M. Statistical comparison between variables were carried out using analysis of variance (ANOVA) and Tukey's post-hoc test was used to compare the differences between the means. Values of  $P < 0.05$  were considered significant.

### III. Results

#### 3.1 The Lipid peroxidation parameter (MDA)

The result of the MDA concentration obtained is shown in Fig 1. There was a significant increase ( $P < 0.001$ ) in the MDA concentration of the active control compared with the passive control. There was a significant decrease ( $P < 0.001$ ) in the MDA concentration in all the vitamin E and selenium pre-treated groups when compared with the active control. This decrease was more pronounced in rats co-administered with vitamin E and selenium



**Fig 1: Effects of selenium and vitamin E on serum malondialdehyde concentration in rats subjected to water immersion restraint stress, a, b, c, d, and e = Means with different superscript letters are significantly ( $p < 0.001$ ) different.**

PC = Passive control (Non stress animals). AC = Active control (WRS + Distilled water). WRSVE = (WRS + vitamin E). WRSVESE = (WRS + vitamin E + selenium). WRSSE = (WRS + selenium). WRS = water immersion restraint stress.

#### 3.2 Ulcer index, ulcer score and ulcer inhibition

Table 1: show number of ulcers, ulcer score, ulcer index and ulcer inhibition capacity of selenium and vitamin E in the pre-treated rats. WRS induced ulcers as shown by the mean number of ulcers  $1.43 \pm 0.43$ , compared with passive control ( $P < 0.05$ ). Similarly, there was significant ( $P < 0.001$ ) increase in the ulcer scores of the active and passive control. Pre-treatment with vitamin E and selenium significantly decreased the number of ulcers, ulcer score and ulcer index ( $P < 0.001$ ) when the pre-treated groups were compared with active control. Vitamin E inhibited ulcer by 52.65 %, selenium by 47.35 %, and especially the combination of vitamin E and selenium inhibited ulcer (by 73.26 %).

**Table 1: Effects of vitamin E and selenium on gastric ulcer parameters in rats subjected to water immersion restraint stress**

Group	Number of ulcers	Ulcer score	Ulcer index	Ulcer inhibition (%)
Pass. Cont.	$0.00 \pm 0.00^{**}$	$0.00 \pm 0.00^{**}$	-----	-----
Act. Cont.	$1.43 \pm 0.43$	$27.14 \pm 3.59$	999	-----
WRS + vit E	$0.43 \pm 0.20^{**}$	$12.86 \pm 6.06^{**}$	560.4	52.65
WRS+vitE+sel	$0.14 \pm 0.14^{**}$	$7.14 \pm 2.86^{**}$	214.7	73.26
WRS + sel	$0.43 \pm 0.20^{**}$	$14.28 \pm 5.71^{**}$	574.7	47.35

\*\* = Significant Differences between active control and passive control also active control compared with vitamin E and selenium groups at  $P < 0.001$

Pass. Cont. = Passive control (Non stress animals). Act. Cont. = Active control (WRS + Distilled water). WRS + vit E = (WRS + vitamin E). WRS + vit E + sel = (WRS + vitamin E + selenium). WRS + sel = (WRS + selenium). WRS = water immersion restraint stress.

### 3.3 Gastric juice Volume, Titratable acidity and Acid output

As shown in table 2, WRS induced gastric ulcer with a significant increase in titratable acidity and acid output ( $P < 0.001$ ) in the active control as compared with the control. Pre-treatment with vitamin E and selenium decreased ( $P < 0.001$ ) the titratable acidity, acid output and volume of the gastric juice.

**Table 2:** Effect of selenium and vitamin E on gastric acid secretion and output in rats subjected to water immersion restraint stress

Group	Gastric juice vol. (ml/3 hours)	Titratable acidity (mEq/L)	Acid output ( $\mu$ Eq/hour)
Pass. Cont.	$2.19 \pm 0.06^{**}$	$36.14 \pm 0.77^{**}$	$78.91 \pm 2.726^{**}$
Act. Cont.	$4.81 \pm 0.09$	$78.71 \pm 1.38$	$127.06 \pm 2.75$
WRS + Vit E	$2.37 \pm 0.16^{**}$	$35.14 \pm 1.50^{**}$	$83.60 \pm 4.18^{**}$
WRS+ VitE+ Sel	$1.53 \pm 0.08^{**}$	$34.29 \pm 7.33^{**}$	$41.60 \pm 2.68^{**}$
WRS + Sel	$2.96 \pm 0.11^{**}$	$36.43 \pm 0.53^{**}$	$107.67 \pm 3.87^{**}$

\*\* = Significant Differences between active control and passive control also active control compared with vitamin E and selenium groups at  $P < 0.001$

Pass. Cont. = Passive control (Non stress animals). Act. Cont. = Active control (WRS + Distilled water). WRS + vit E = (WRS + vitamin E). WRS + vit E + sel = (WRS + vitamin E + selenium). WRS + sel = (WRS + selenium). WRS = water immersion restraint stress.

## IV. Discussion

The result showed that WRS induced cells damage in the body leading to lipid peroxidation as evidenced by gastric mucosal damage in rats, and administration of vitamin E or selenium ameliorated the-induced mucosal damage in the rats. The findings of the study demonstrated that ROS may be involved in the gastric mucosal damage as evidence by increased MDA concentration recorded in the active control rats. It is also accepted as basic indicator of tissue damage in the heart, lungs, small intestine and stomach [22]. In the present study the MDA level increase significantly in the active control ( $P < 0.001$ ) with respect to the passive control. Whereas selenium and vitamin E pre-treatment reduced the level of the MDA significantly ( $P < 0.001$ ) in comparison to the active control (Figure 1). The results clearly revealed that selenium and vitamin E inhibited gastric mucosal lesion in rats, subjected to WRS through prevention of lipid peroxidation. Co-administration of selenium and vitamin E produced considerable decrease in MDA concentration, compared to selenium or vitamin E alone in the present study. Jeong-Hwan et al. [22] reported that pre-treatment of 100  $\mu$ g/ kg selenium for 3 days significantly decreased MDA concentration in ethanol-induced gastric mucosal lesion in rats. Naime et al. [22]. Investigated the effects of selenium, which is a co-factor of GSH-Px, on gastric mucosal injury induced by cold restraint stress and found that selenium protected mucosa from lipid peroxidation-induced damage by significantly decreasing gastric MDA concentration. Naime et al. [23] also found that a combination of vitamin E and selenium decreased significantly in gastric mucosal damage and lipid peroxidation-induced MDA concentration in rats, subjected to cold restraint stress. The present study showed that vitamin E and selenium administration in WRS-induced gastric lesion in Wistar rats may exert therapeutic effects as evidenced by a significant difference ( $P < 0.05$ ) in the gastric ulcer parameters (ulcer score, number of ulcer and ulcer index), when the active control was compared with passive control. The study findings agreed with the report of Anil et al. [1] who demonstrated that that the stomach is one of the main targets of stress and that stress-induced gastric ulceration is a typical example of stress-associated organ injuries. Thus, the administration of vitamin E and selenium individually or in combination decreased significantly all the studied gastric ulcer parameters because vitamin E and selenium as scavengers may inhibit the ROS lipid peroxidation of molecules and, therefore, prevent tissue damage [24]. The result of the present study was in accordance with the report of Ibrahim et al. [8] who concluded that supplementation with palm vitamin E or  $\alpha$ -tocopherol reduced gastric lesion significantly. According to Abu Taib et al. [12], selenium prevented reperfusion- induced gastric mucosal lesion, intraluminal bleeding and depletion of non-protein sulphhydryl (NPSH) level in the rat stomach, therefore exert antioxidant effect by protecting the tissue against oxidative stress. This study found that the ulcer was inhibited by vitamin E by 52.65%, selenium inhibited ulcer by 47.35%, while co-administration of vitamin E and selenium inhibited the ulcer by 73.26%, the highest rate. The present study found that the exposure of rats to WRS significantly ( $p < 0.001$ ) increased gastric secretion parameters (gastric juice volume, titratable acidity and acid output) in the active control, compared to the passive control. Pre-treatment with selenium and vitamin E decreased ( $p < 0.001$ ) in gastric secretion parameters (Table 2). The result thus correlated with the report of Yuan-Fang et al. [25] that gastric output increased remarkably in rats exposed to WRS, and this increase lasted while the stress was present. The stress-induced increase in acid output correlated well with severity of the mucosal lesion. Yuan-Fang et al. [25] reported that rat gastric acid output was increased remarkably by WRS, and this increase lasted while the stress was present. The stress-induced increase in acid output correlated well

with the severity of mucosal lesions. Bilateral cervical vagotomy prevented the gastric mucosal lesion in the WRS model, which suggested that WRS induced gastric mucosal lesion was basically a digestive ulcer, resulted from parasympathetic over- activity and related increased in acid output at the basis of reduced mucosal resistance. The result of the present study reported an increase in the volume, titratable acidity and acid output in the active control; but selenium and vitamin E pre-treatment lowered significantly the recorded increases. This effect may contribute to gastric mucosal protection activity of selenium and vitamin E.

## V. Conclusion

It is concluded that WRS caused significant increases in the concentration of serum lipid peroxidation, gastric ulcer and secretion parameters. Pre-treatment with selenium and/or vitamin E ameliorated adverse effects of WRS. Co-administration of vitamin E and selenium exerted synergistic effects in the restoration of WRS-induced changes in gastric mucosal damages and MDA concentration.

## References

- [1]. Anil, K., Ruchika, G., Vaibhav, G. and Puneet, K. (2010). Possible role NO Biol., 48: 11-31. modulators in protective effect of trazodone and citalopram (antidepressant) in acute immobilization stress in mice. *Ind. J. Exp.*
- [2]. Sheldon, C. Denise, J.D. William, J.D. Gregory, E.M. Ellen, F. Bruce, S.R. and Ronald, B.T. (2012). Chronic stress, glucocorticoid receptor resistance, inflammation and diseases risk. *Proceeding of the National Academy of Sciences*, 109(16): 5995-5999.
- [3]. Nayanatara, A.K., Tripathi, Y. Nagaraj, H.S., Jeganth .P.S., Ramaswamy,C. and Ganaraja,B. (2012). Effects of chronic immobilization stress on some selected physiological, biochemical and lipid parameters in Wistar Albino Rats. *RJPBCS*, 3 (1): 34-42
- [4]. Dur-Zong, H. Yi-Wei, C. Pei-Yi, C. Srinivasan, P. and Ming-Yei, L. (2013). Protective effect of 3,4-methylenedioxyphenol (sesamol) on stress-related mucosal diseases in rat. *Biomed. Resea. Inter.* 48: 18-27.
- [5]. Ochi, M. Tominga, K. Tanaka, F. Tanagiwa, T. Shiba, M. Watanabe, T. and Arawaka, T. (2008). Effect of chronic stress on gastric emptying and plasma ghrelin levels in rats. *Life Sci*, 82: 862-868.
- [6]. Robles, T.F. and Carroll, J.E. (2011). Restorative biological process and health. *Soc.PersonalPsychol compass*, 5: 518-537
- [7]. Nur- Azlina, M.F. Ibrahim, A.I. Yusof, K. and Nafeeza, M.I. (2012). Palm vitamin E reduces catecholamines, xanthine oxidase activity and gastric lesion in rats exposed to water immersion restraint stress. *Biomed. Central (BMC) Gastroenterol*, <http://www.biomedcentral.com/1471-230x/54/.....>
- [8]. Ibrahim, A.I. Yusof, K. Mohd, I.N. Mohd, F. and Nur, A. (2010). The effects of palm vitamin E on stress hormonal levels and gastric lesion in stress – induced rats. *Ach. Med. Sci.*, 8 (1): 22-29.
- [9]. Jun, Z. Anthony. D. Reji, B. Kirk, L. and Toku, T. (2009). Effects of repeated restraint stress on gastric motility in rats. *Am. J. Physiol. Regul. Integr. Comp.*, 296 (5): 1358 -1365.
- [10]. Finkel, T. and Holbrook, N.J. (2000). Oxidants, oxidative stress and the biology of ageing. *Nature*, 408:239-247.
- [11]. Ujang, T. (2008). Selenium: Its role as antioxidant in human health. *Env. Health Prev. Med.*, 13 (2): 102-108.
- [12]. Abu Taib, M.M.A. Rasheed, S.A. Othman, A.A. Mohammad, S.A. Ali, A.M. and AliS.T. (1997). Selenium protects against ischemia- reperfusion induced gastric lesion in lesion in rats. *The Saudi J. of Gastroenterol.*, 3 (3): 125-129
- [13]. Yoshikawa, T. Yasuda, M. Uedas, S. Naito, Y. Tanigawa, T. Oyamada, H. and Kondo, M. (1991). Vitamin E in gastric mucosal injury induced by ischemia- Reperfusion in nitric oxide depleted rats. *Alim. Pharm. Ther*, 13 (4): 553-559.
- [14]. Magaji, R.A. Okasha, M. A.M. Abubakar, M.S. and Fatihu, M.Y. (2007). Anti- ulcerogenic and anti- secretory activity of the N- Butanol portion of *Syzygiumaromaticum* in rats. *Nig. J. Pharm. Sci*, 6(2): 119-126.
- [15]. Shu, G. Qian, G. Qing, J. Wei, H. Xue, G, and Ji-Min, C. (2012). Gastric mucosal damage in water-immersion stress: Mechanism and prevention with GHRP-6. *World J. Gastroenterol*, 18 (24): 3145-3155.
- [16]. Vivian, M.C. Yazmin, R.C. Yohani, P.G. Ambar, O.Y. Sonia, J.D. Rosa, M.F. and Daisy, C.Q. (2011). Effects of grape seed extract, vitamin C and vitamin E on ethanol and aspirin-induced ulcers. *Adv. Pharmacol. Sci.* <http://dx.doi.org/10.1155/2011/740687>
- [17]. Akanji, M.A. Adeyemi, O.S. and Oguntoye, F.S. (2009). Psidiumguajava extract reduce trypanosomosis associated lipid peroxidation and raises glutathione concentration in infected animals. *Exp. Clin. Sci. J.*, 8: 148-154.
- [18]. Shawon, L. and Gautam, P. (2012). An overview of the current methodologies used in evaluation of gastric and duodenal anti-ulcer agent. *Pharm. Sci. Mag.*, 3 (8): 10 – 20.
- [19]. Raymond, J., Tania, M., Rebecca, C. and Ruth, E. (1995). Human spasmolytic polypeptide is a cytoprotective agent that stimulates cell migration. *Gastroenterol*, 108: 108-116.
- [20]. Shay, H. David, C.H. and Grunstein, M.A. (1954). Quantitative method for measuring spontaneous gastric acid secretion in rat. *Gastroenterol*, 58: 340-357.
- [21]. Zhongzhi, W. Junichi, H. Xinhui, W. Akiko, M. Takahiro, T. Norimasa, M. and Tatsuo, W. (2011). Protective effects of Ginger against Aspirin-Induced gastric ulcers in rats. *YonagoActa Med*, 54: 11-19
- [22]. Jeong-Hwan, K. Shin-Hyung, P. Soo-wan, N. and Yung-Hyun, C. (2012). Gastro protective effect of selenium on ethanol-induced gastric damage in rats. *Int. J. Mol. Sci.*, 13 (5): 5740-5750.
- [23]. Naima, C. Ramazan, C. Aytak, A. Mehmet, D. Cengiz, T. Esan, G. and Fikri, C. (2001). Protective effects of vitamin E, selenium and allopurinol against stress induced ulcer formation in rats. *Turk. J. Med. Sci.*, 31: 199-203
- [24]. Mansoor, H. and Mahamood, M. (2009). Non - enzymatic and enzymatic antioxidants activities in aqueous extract of different *Ficusdeltoidea* accessions. *J.Med. Plants Res*, 3 (3): 120 -131.
- [25]. Yuan – Fang, X. Qing, J. Shu, G. Fu- Zhen, W. Ji-Min, C. and Zheng-Guo, Z. (2005). Role of parasympathetic overactivity in water immersion stress-induced gastric mucosal lesion in rat. *J. App. Physio*, 99 (6): 2416 – 2422.