

## Teratogenic Effects and Maternal Toxicity of Sprague Dawley Rats Fed *Ficusdeltoidea* Leaves Aqueous Extract in Late Gestation

Abdullah F,<sup>1</sup>Hussin H.<sup>2</sup>, Sukardi S.<sup>1\*</sup>

<sup>1</sup>Department of Biomedical Sciences, Faculty of Medicine and Health Sciences, Universiti Putra Malaysia, Serdang Selangor;

<sup>2</sup>Department of Pathology, Faculty of Medicine and Health Sciences, Universiti Putra Malaysia, Serdang Selangor.

---

**Abstract:** *Ficusdeltoidea* have many beneficial uses however no report has been documented on the possible teratogenic effects if consumed during pregnancy. A study was conducted to observe the effects of feeding *Ficusdeltoidea* leaves aqueous extract (FDLAE) to rats during the late gestation period. Thirty pregnant Sprague Dawley rats were divided equally into five groups: positive control (retinylpalmitate in corn oil), negative control (only water), vehicle control (corn oil), low dose (5g/kg/day) and high dose (10g/kg/day) of FDLAE. Dams were sacrificed at term and their uteri removed by Caesarean section. Livers, placentae and kidneys of dams were subjected to histopathological examination. Fetuses were stained with Alizarin Red S to observe skeletal malformations. The results showed that the maternal liver and kidneys were significantly ( $p < 0.05$ ) affected in FDLAE treatment and positive control groups, however only the placenta was affected in the positive control group. Mortality of dams and numerous skeletal abnormalities of fetuses were also observed in FDLAE treatment groups. We suggest that feeding FDLAE to pregnant dams during the late gestation period cause teratogenic effects and contribute to maternal toxicity.

---

### I. Introduction

Many medicinal herbs and pharmaceutical drugs can be therapeutic at one dose and toxic at another; where the toxicity related to conventional medicines is more widely documented (Saadet *et al.*, 2006). Many people consume herbal medicines thinking them 'safe' as the herbs originated from natural products, but the prolong intake of any medicinal herbs in a large quantity may be harmful (Deciga-Campos *et al.*, 2007). Amongst the many medicinal plants published, *Ficusdeltoidea* is one of the tropical herbal plants widely consumed by Malay folks due to its pharmacological importance (Review by Bunawan *et al.*, 2014). It is an evergreen shrub or small tree belonging to the Moraceae or Mulberry family, is native and widely distributed in several Southeast Asian countries and locally known as Mas Cotek (Mat Salleh and Latif, 2002). This plant and its parts have been reported to possess antinociceptive activity (Sulaiman *et al.*, 2008), hypoglycaemic effects (Adam *et al.*, 2012), antioxidant activity (Hakiman and Maziah, 2009), anti-cancer activity (Khan *et al.*, 2016) and provides protection against osteoarthritis joint destruction (Che Ahmad Tantowiet *et al.*, 2016) among others. Severe toxic effects of herbal medicines have been reported to be associated with hepatotoxicity although reports of other toxic effects on the kidney, nervous system, blood, skin, mutagenicity and carcinogenicity effects have also been published (Saadet *et al.*, 2006). Many chemicals and drugs are also reported to be teratogenic to the human embryo when taken during pregnancy and herbal medicines are no exception. An example is retinyl palmitate which contains the compound retinoids known to be an excellent teratogen; whereby when actively converted into retinoic acid (the short lived active form of Vitamin A), is responsible for the regulation of gene expression; thus any disorders may exert teratogenic effects especially on the central nervous system (Somner, 2008). These compounds have also been known to halt limb outgrowth and chondrogenesis resulting in limb reduction defects (Lee *et al.*, 2004; Ali Khan and Hales, 2006). The two major factors to be considered when assessing teratogenic potentials of a particular medicine are, the stage of pregnancy at which the exposure had occurred, and the amount of medication taken (Rogers and Kavlock, 2001). Teratogenic effects which occur during embryonic life may show immediately after birth, at infancy or even later in life (Korach, 1998). Basically, in teratology studies, the evaluation of skeletal anomalies is a vital step in determining the xenobiotic teratogenic activity in risk assessment (Tyl, *et al.* 2007; Solecki, *et al.*, 2015). One of the effects seen in skeletal malformation is skeletal dysplasia which is related with severe disability and may even cause fatality (Cessart, 2010). As *Ficusdeltoidea* products are widely consumed for various types of health benefits, we therefore propose a research to investigate whether feeding *Ficusdeltoidea* aqueous extract to pregnant rats during the late gestation period have possible teratogenic and maternal toxicity effects.

### II. Materials and Methods

#### *Ficusdeltoidea* leaves aqueous extract (FDLAE) and treatment dosage

FDLAE was obtained in powdered form from UTM Skudai, Johor. The treatment dosages were fixed at 5g/kg/day and 10g/kg/day of FDLAE(both doses for 8 days repeatedly).

### **Experimental Design**

The experiment consists of thirty pregnant *Sprague Dawley* rats randomly divided into 5 groups during the late gestation period. Two groups were treated with two different doses of FDLAE at 5g/kg/day (Low Dose group or LD) and 10g/kg/day (High Dose group or HD), one group of positive control treated with retinylpalmitate in corn oil (PC), one group treated with only corn oil as the vehicle control (VC), and the last group given only water as the negative control (NC). Corn oil is advised as the first choice to be used as vehicle for hydrophobic substances in toxicological studies (Anjali *et al.*, 2011) because in such acute period of administration, it is reported not to produce any toxic effects or skeletal malformations to the tested subjects which were rats. However if given for prolonged periods, corn oil will have some undesirable effects on reproduction and histology of the kidney in rats (Masako, *et al.*, 2000).

### **Body Weight Measurement**

The body weight of each pregnant dam was measured daily throughout the experimental period of 21 days. During the measurement, the pregnant dams were carried slowly and handled carefully to prevent agitation and stress, while the weighing machine was placed on a smooth surface to prevent faulty measurements.

### **Experimental Procedure**

A monogamous mating process was practiced where one female was mated with one fertile male rat and kept overnight in a cage with a tray at the bottom to collect the vaginal plug. If a vaginal plug is detected the next morning, it will be considered as day 1 of pregnancy (day 1 post-coitum). The mated females were then randomly assigned into different groups and given treatment from gestation day (GD) 8 to 15. The dams were observed closely daily for survival, food and water consumption, changes in appearance, behavior, and signs of vaginal bleeding, or abortion. Daily weights were also done to monitor toxicity throughout the experiment. The maternal weight gain was recorded during the entire pregnancy (total weight gain) including during the treatment period. Upon reaching day 21 of pregnancy (at term), the dams were sacrificed using diethyl ether and their uteri removed by Caesarean section. The liver, placenta and kidneys of dams were collected, weighed and later fixed in 10% formalin for histopathological (HPE) studies. The numbers of fetuses were recorded, processed and observed for any skeletal malformations (Solecki *et al.*, 2015) where numbers of skeletal elements were counted and any malformation or variations observed were recorded. They were also examined for obvious external malformations before subsequent processing.

### **Preparation of Reagents (retinyl palmitate in corn oil)**

Retinyl palmitate was purchased commercially from Fisher Scientific. It was dissolved in corn oil as the vehicle. According to the Material safety data sheet Vitamin A USP MSDS, the Oral LD<sub>50</sub> for Retinyl palmitate in rats is 7910mg/kg. According to Collins *et al.* (1994), the effective dose of retinyl palmitate seen to give effect is 90 mg/kg/day. Thus, in this study conducted, 300,000 USP/kg/day was prepared after converting the effective dose unit (90mg/kg) according to the international unit system.

### **Evaluation of Skeletal Malformations**

#### **a) Fetal staining**

Firstly the fetuses were washed with tap water after being kept in 10% formalin solution. They were then partially incised at the abdominal region to remove all internal organs. Next, the fetuses were then placed in clean individual bottles or in staining boxes which consist of 1:4 (diethyl ether: methanol) and left for a week. The fetuses were then washed with tap water and placed in clean individual bottles or staining boxes containing 0.3% Alizarin Red S. in 10% KOH solution and left for a week. The solution should turn colorless when the Alizarin stain had been absorbed by the fetuses. The fetuses were then transferred to clean individual bottles consisting of 1:1 glycerine:75% ethanol for 24 to 48 hours. Finally, all the fetuses stained were stored in pure glycerine in clean individual bottles.

#### **b) Fetal bone observation**

The observation was done by examining the sizes and shapes of the vertebral arches and centers, ribs and sternal centers. The number of ossification centers was counted. The most frequently observed numbers of ossification centers at each site were as follows: cervical 7, thoracic 13 or 14, lumbar 7 or 6, sacral 5, caudal more than 5, sternal centers 6, and ribs 13 or 14. Subsequently, the thoracic, pelvic girdles, forelimbs and hind limbs were examined for development of the long bones; the numbers of phalanges were counted. The number of phalanges for a normal 21-day rat fetus should be forelimb (metacarpals 4, proximal 4, middle 4, distal 5) and

hind limb (metatarsals 5, proximal 5, middle 4, and distal 5).

### Evaluation of Maternal Toxicity- Tissue Sampling

Kidneys, placentae and livers were collected and cleaned with normal saline, dried, and weighed before being preserved in 10% formalin prior to tissue processing for histology.

### Statistical Analysis

All data obtained throughout this study were expressed as Means  $\pm$  S.E.M. (standard error of means). Data on maternal body weights were subjected to a Two-way Analysis of Variance (ANOVA), followed by Duncan's test to compare mean differences between experimental groups. A One-Way Analysis of Variance (ANOVA) and Dunnett's means comparison test were used to analyze the data of all maternal organ weights, fetal weight and fetal length. For histological examinations, the non-parametric Chi-square test was applied; for all findings where p value is less than 0.05 was selected as the level of statistical significance.

## III. Results

### Gross Observations

Dams in the HD group showed dermatologic effects or scabs, were generally malaise and anorexic with a decrease in feed consumption and appear lethargic. Upon caesarian, it was observed that in both HD and LD groups, there were constrictions between the fetuses in the uterine horns. In the HD group, a dam was observed to have an empty sac with placenta in the uterus indicating late fetal resorption. Additionally, two dams were found dead on two different gestation days (GDs), one with a swollen front limb.

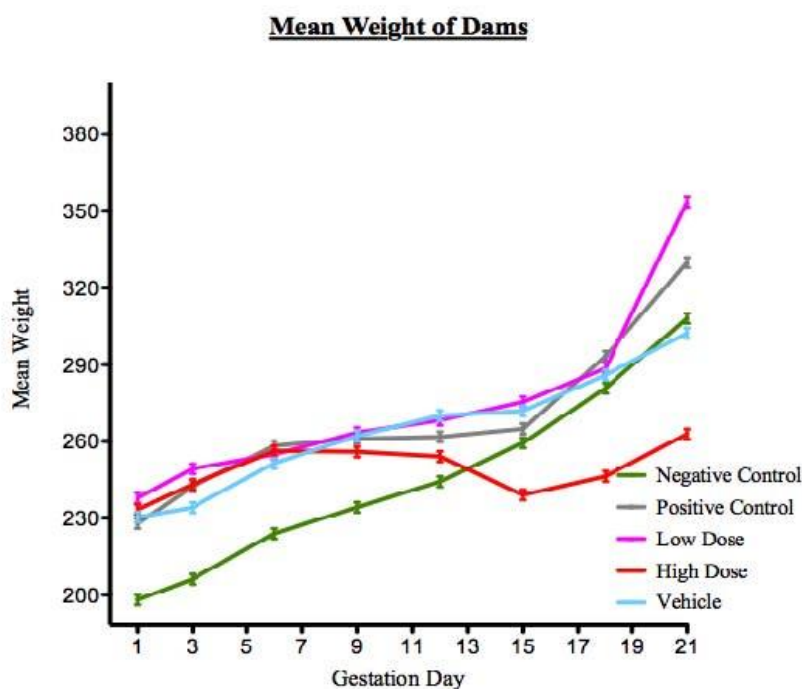
### Effect of FDLAE on number of dams with fetuses

The HD group has consequently resulted in 2 deaths, leaving only 1 dam with fetuses and 3 dams with no fetuses as compared to the LD group where only 2 dams did not have any fetuses.

### Effects of FDLAE on maternal body weight

The mean maternal body weights of both the LD and the HD groups were higher than the NC group. As for the PC group when being compared to the VC group, the mean weight of the pregnant dams of the PC group was lower than the VC Group. Mean weights of pregnant dams up to term was shown in Graph 1. A comparison between each treatment was done and it was found that the maternal weight was not significantly ( $p > 0.05$ ) affected by the treatment of FDLAE but it does show a significant difference ( $p < 0.001$ ) between the LD and HD groups.

**Graph 1:** Mean weights of pregnant dams up to term (GD 21).



### Effects of FDLAE on maternal organs

#### a) Effects of FDLAE on liver weight

The NC group had the highest mean weight while the HD Group had the lowest. Liver weight in the HD group was significantly different ( $p > 0.05$ ) when compared to the NC group.

**b) Effects of FDLAE on kidney weight**

The VC group had the highest mean weight and the lowest was observed in the HD group. There was no significant difference in the means of kidney weights between the NC Group and both the FDLAE treatment groups.

**c) Effects of FDLAE on placenta weight**

The mean weight of the placenta was highest in the VC group, followed by NC group, PC Group, LD group and the lowest mean weight was in the HD group. The weight of the placenta was not significantly affected by the types of treatments given.

**d) Effects of FDLAE on fetal weight**

Mean weights of fetuses were highest in the NC group, followed by the PC group, the VC group, the LD group and lastly the HD group. The fetal weight was not significantly affected by the type of treatments given.

**e) Effects of FDLAE on fetal length**

Mean length of fetuses of both treatment groups were lower than the NC Group. The PC group had the lowest fetal length. Fetal lengths were significantly ( $p < 0.05$ ) affected by the treatments of FDLAE.

**Effects of FDLAE on the histology of different maternal organs**

**a) Evaluation of kidney histological examinations**

There was a significant difference ( $p < 0.05$ ) in kidney cell structures showing infiltration of inflammatory cells in the interstitium of tubules and glomerulus of both FDLAE treatment groups when compared to the NC group.

**b) Evaluation of the liver histological examinations**

There was a significant difference ( $p < 0.05$ ) in abnormal changes in the liver in both FDLAE treatment groups as compared to the NC group. The cell plate structure of the liver was affected and a mild degree of inflammation was observed in the LD group while a moderate degree of inflammation was observed in the HD group. Nuclear polymorphism was also observed in the LD group.

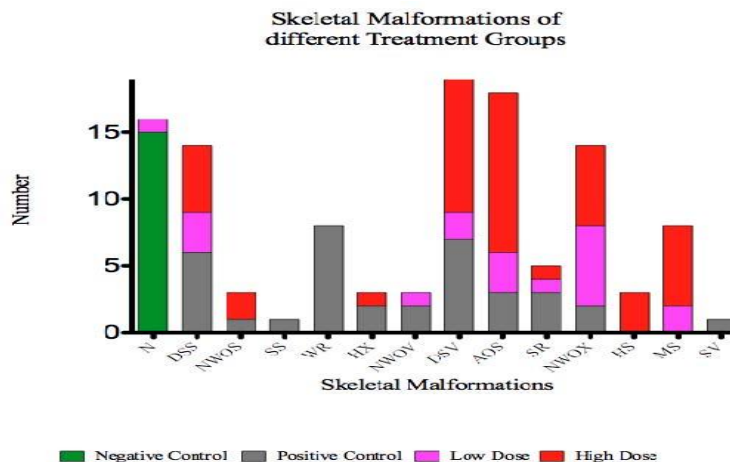
**c) Evaluation of placental histological examinations**

There was evidence of degeneration of trophoblasts, villi of the stroma were not well formed or showing collapsed villi structures and inflammatory cells were observed in the PC group while other groups showed normal well formed villi structures, intact chorionic villi and trophoblasts.

**Evaluating fetotoxicity-Observation of Skeletal Malformations**

The effect exerted by different treatments (NC, PC, LD and HD groups) towards the presence of any skeletal abnormalities were analyzed from different aspects (vertebrae, ribs, and sternum) and depicted in Graph 2.

**Graph 2:** Various skeletal malformations observed in different treatment groups



The observations for skeletal malformations (standard teratogenic skeletal abnormalities) were carried out by comparing the findings in both treatment groups to the NC and PC groups. Both treatment groups showed

significant ( $p < 0.05$ ) difference in the various skeletal malformations present. The skeletal malformations observed include Normal (N), Dumbbell shaped sternum (DSS), Not well ossified sternum (NWOS), Split sternum (SS), Wavy ribs (WR), Hypoplastic xiphoid (HX), Not well ossified vertebrae (NWOV), Dumbbell shaped vertebrae (DSV), Absence of sternum (AOS), Supernumerary Ribs (SR), Not well ossified xiphoid (NWOX), Hemicentric sternabrae (HS), Misaligned sternabrae (MS) and Split vertebrae (SV).

#### IV. Discussions

In this study conducted, two different doses (low dose of 5g/kg/day and high dose of 10g/kg/day) of FDLA were given orally to pregnant dams from gestation day 8 to 15. The controls in this study were retinyl palmitate (Positive Control), Distilled Water (Negative Control), and Corn Oil as vehicle control. The RP is dissolved in corn oil because it cannot be dissolved in water or Tween 20; thus making corn oil as the vehicle control group. During this treatment period, gross examination of each pregnant dam was carried out daily and dams in the HD group had a decrease in their feed consumption and showed general malaise and weakness. Their stereotypic behavior and fixed motor patterns include complex rhythmic motor activities like tail and leg incoordination during movements, walking, turning and rearing (Fragopoulou *et al.*, 2009). Number of dams with fetuses also decreased in the treatment groups when compared to the negative control. The period of organogenesis or development of organs will manifest as abortions, malformations, or retarded development if drugs or chemicals were introduced. Rogers and Kavlock (2001) reported that maternal toxicity can lead to toxic effects in the fetuses; whereby, embryotoxicity and fetotoxicity are the general terms used to describe toxicity related to the period of exposure during gestation.

The maternal mean body weights were observed to be higher in the treatment groups as compared to the negative control group and this change may be due to the slight edematous conditions observed in a few dams. The kidney which is an important excretory organ was observed to have inflammatory changes due to the infiltration of inflammatory cells into the glomerulus and interstitium (Fathallah-Syakh and Neiberger, 2008). This change will further explain the symptoms of general malaise and weakness, as well as anorexic conditions; which are accompanied by sodium and water retention leading to generalized edema (Parmar, 2016). The liver plays an important role in the innate immune response, providing the first line of defence against microbes and toxins crossing the intestinal barrier (Janeway, 2002), whereby they are eradicated from the systemic circulation by the Kupffer cells (Gregory and Wing, 2002). The histopathological findings from this study showed that the hepatocytes were puffed up (swollen) and infiltration of inflammatory cells were numerous suggesting acute inflammation (Ramaiah *et al.*, 2004). Gujra *et al.*, (2003) reported that cholestasis is basically the condition in which little or no bile is secreted or the flow of bile into the digestive tract is obstructed; in this case due to the disruption in the liver function. We suggest that the signs of dermatologic effects observed as scabs formed or due to intense itching (seen in the HD group) were basically due to the deposition of bile products in the skin (Mela *et al.*, 2003).

The teratogenic effects observed as skeletal malformations or dysplasia is a heterogeneous and complex group of conditions that affect bone growth and formation resulting in a variety of anomalies in the shape and size of the skeleton (Menegola *et al.*, 2002; Dodo *et al.*, 2009). Skeletal malformations of fetuses are clinically important, as skeletal dysplasias can be associated with severe disability and may even be lethal (Cessart, 2010). It is also important to know that skeletal variations or malformations for some fetal observations are perhaps the best indication that the anatomical changes were caused by exposure to the chemical agent involved (Chahoud and Paumgarten, 2009) and do not just happen without a strong stimulus or in this case, without a teratogen. In this study, fetotoxicity was seen as late fetal resorptions in the HD group which further confirms that the herbal chemicals have been transported through the placenta to the fetus causing a devastating toxic effect on the susceptible growing fetus. However histological changes such as degeneration of trophoblasts, not well formed villi stroma or collapsed villi structures and evidence of inflammation were only observed in the RP group as compared to other groups and these findings were consistent with those reported by Collins and Mao (1999).

The fetus weights were also seen to be lower in both treatment groups. This may probably be due to less nutrition was available to the fetus as the dams were unhealthy. However the skeletal malformations were not dose-dependent and the types of malformations that occur were dependent on fetal variations. Most of the fetuses in both treatment groups have two or more skeletal anomalies observed; like absence of sternum, rudimentary supernumerary ribs, dumbbell shaped sternabrae, etc. The question here was how fetal bone formation was affected by the FDLA treatments given. Basically, this question can be related to the former findings related to the maternal toxicity which involved the liver and kidneys. This deduction is in agreement with Singh *et al.*, (2009) as any abnormality in the histoarchitecture of major organs during histological examinations would be the most reliable outcome of toxic manifestations. We suggest that when the liver function was disrupted, this will cause the dams to suffer from possible vitamin D deficiency (Rode, *et al.*, 2010; Malhamet *et al.*, 2011) thus causing calcium malabsorption and weaker bones to be formed. Additionally,

the kidneys function to produce the hormone calcitriol (Vitamin D3), involved in calcium and phosphate resorption, therefore any disruption to the kidney would also cause an effect to the kidney functions; thus causing a disorder to the amount of calcitriol formed (Melamed and Thadani, 2012). This would cause a fall in the resorption of calcium and phosphate vital for bone growth and development, what more during the organogenesis period. In relation to that, the growing fetus obtains the calcium needed for its bone formation from the mother (Kovacs, 2001), therefore when the mother has less calcium to provide, the fetus will not be getting the appropriate amount needed for its bone growth and formation (Oliveriet *al.*, 2004). This would explain the findings of not well ossified xyphi, hemicentric sternebrae, absence of sternum, hypoplastic sternum, etc.

## V. Conclusion

The study conducted was an effort to identify and ensure whether the consumption of *Ficusdeltoidea* leaves in aqueous form was safe during late pregnancy using an animal model with a similar placental structure as a pregnant human female. The research findings suggest that consuming *Ficusdeltoidea* leaves aqueous extract at the doses of 5g/kg/day and 10g/kg/day during late gestation contribute to maternal toxicity and teratogenic effects in the form of skeletal malformations and fetal resorption.

## Acknowledgements

The authors wish to thank Universiti Putra Malaysia for the RUGS grant, animal housing team, physiology and histopathology laboratory team from the Faculty of Medicine and Health Sciences, Universiti Putra Malaysia, Serdang, Selangor, Malaysia.

## References

- [1]. Adam Z, Khamis S, Ismail A, Hamid M. (2012). *Ficusdeltoidea*: A potential alternative medicine for diabetes mellitus. Evidence-Based Complementary Alternative Medicine. 201 (2): 632763. pp:1-12.
- [2]. Ali Khan, S. E., and Hales, B. F. (2006). Retinoid receptor antagonists alter the pattern of apoptosis in organogenesis stage mouse limbs. Toxicological Science. 90(1): 208-220.
- [3]. Anjali, S., Tanuja, N. A., Singh, J.K., and Ravish, K. (2011). Effect of Corn Oil as a Vehicle on Kidney of Female Swiss Albino Mice *Mus Musculus* by Gavage Method. Research Journal of Biotechnology. 6(1):15-8.
- [4]. Bunawan, H., Mat Amin, N., Bunawan, S.N., Baharum, S.N. and Mohd. Noor, N. (2014). *Ficusdeltoidea* Jack: A Review on Its Phytochemical and Pharmacological Importance. Evidence-Based Complementary and Alternative Medicine. pp: 1-9
- [5]. Cessart, Marie. (2010). Suspected Fetal Skeletal Malformations or Bone Diseases: How To Explore. Journal of Pediatric Radiology. 40:1046-1051.
- [6]. Chahoud, I. and Paumgarten, F.J.R. (2009). Dose-response relationship of rat skeleton variations: Relevance for risk assessment. Environmental Research 109:922-929.
- [7]. Che Ahmad Tantowi, N., Mohammad, S., and Hussin, P. (2016). Effect of *Ficusdeltoidea*, a medicinal plant, on cartilage protection in cartilage explant and postmenopausal rat models of osteoarthritis. Osteoarthritis and Cartilage. 24 (1): S353-S354
- [8]. Collins, M.D. and Mao, G.E. (1999). Teratology of retinoids. Annual Review Pharmacology Toxicology 39:399-430
- [9]. Collins, M.D., Tzimas, G., Hummler, H., Burgin, H., and Nau, H. (1994). Comparative Teratology and Transplacental Pharmacokinetics of All-*trans*-Retinoic Acid, 13-*cis*-Retinoic Acid, and Retinyl Palmitate Following Daily Administrations in Rats. Toxicology and Applied Pharmacology. 127 (1): 132-144
- [10]. Deciga-Campos M., Rivero-Cruz I., Arriaga-Alba M., Castaneda-Corral G., Angeles-Lopez G.E. Navarrete A. and Mata R (2007). Acute toxicity and mutagenic activity of Mexican plants used in traditional medicine. Journal of Ethnopharmacology, 110: 334-342
- [11]. Dodo, T., Fukuta T, Uchida K, Mineshima H, Okuda Y, Okada F, Katsutani N, Hirano K, Aoki T (2009). A comparative investigation of fetal skeletal anomalies in rats induced by acetylsalicylic acid with single and double-staining techniques. Regulatory Toxicology and Pharmacology. 54(3):308-313
- [12]. Fathallah-Shaykh, S. and Neiberger R. (2008). eMedicine Specialties. Pediatrics: General Medicine Nephrology. Article Last Updated: 8 Jul 2008.
- [13]. Fragopoulou, F.A., Koussoulakos, L.S., and Margaritis, H.L. (2009) Cranial and postcranial skeletal variations induced in mouse embryos by mobile phone radiation. PATPHY-647.
- [14]. Gregory, S. H. and Wing, E.J. (2002). Neutrophil-Kupffer cell interaction: a critical component of host defenses to systemic bacterial infections. Journal of Leukocytic Biology. 72(2):239-48.
- [15]. Gujral, J.S., Farhood, A., Bajt, M.L., and Jaeschke, H. (2003). Neutrophils aggravate acute liver injury during obstructive cholestasis in bile duct-ligated mice. Hepatology. 38:355-363.
- [16]. Hakim M. and Mahmood, M. (2009). Nonenzymatic and enzymatic antioxidant activities in aqueous extract *Ficusdeltoidea*. Journal of Medicinal Plants Research. 3(3):120-131.
- [17]. Janeway, C. A. Jr. and Medzhitov, R. (2002). Innate immune recognition. Annual Review Immunology. 20:197-216
- [18]. Khan, A.A., Omer-K.A., Talib, Ahmed, H., Javed, M.A., and Sarmidi, R.M. (2016). Human and Animal Health Green Tropical Phytoextracts - Promising Anticancer Alternative. Brazilian Archives of Biology and Technology vol. 59.
- [19]. Korach, K.S. (1998). Development and Reproductive Toxicology. ed. M. Dekker. New York: McGraw Hill
- [20]. Kovacs, C. S. (2001). Calcium and bone metabolism in pregnancy and lactation. The Journal of Clinical Endocrinology and Metabolism. 86:2344-2348.
- [21]. Lee, G.S., Kochhar, D.M., and Collins, M.D. (2004). Retinoid induced limb malformations. Current Pharmaceutical Biotechnology. 10: 2657-2699.
- [22]. Malham, M., Jorgensen, S.P., Ott, P., Agnholt, J., Vilstrup, H., Borre, M., and Dahlerup J.F. (2011). Vitamin D deficiency in cirrhosis relates to liver dysfunction rather than aetiology. World Journal of Gastroenterology. 17:922-925.
- [23]. Masako, S., Kazuyoshi, W., Hideki, M., Tetsuji, N., Kiyoshi, I., and Hiroshi, Ono. (2000). Influence of Corn Oil and Diet on Reproduction and the Kidney in Female Sprague-Dawley Rats. Toxicological Sciences 56 (1):156-164.

- [24]. Mat Salleh, K and Latiff, A. (Editors) (2002).TumbuhanUbatan Malaysia. Publisher: Research Management Unit, UKM. Watan Printer, Kuala Lumpur.
- [25]. Mela, M., Mancuso, A.,andBurroughs, A.K. (2003). Review article: pruritis in cholestatic andother liver diseases. *Ailment Pharmacology Theraphy*. 17 (7): 857-870
- [26]. Melamed, M.L. and Thadhani, R.I. (2012).Vitamin D Therapy in Chronic Kidney Disease and End Stage Renal Disease.*Clinical Journal of American Society of Nephrology* 7(2): 358–365.
- [27]. Menegola, E., Broccia, M.L., Di Renzo, F., and Giavini, E. (2002).Comparative study of sodium valproate-induced skeletal malformations using single or double staining methods.*ReproductiveToxicology*.16 (6): 815–823
- [28]. Oliveri, B., Parisi, M. S., Zeni, S., and Mautalen, C. (2004). Mineral and bone mass changes during pregnancy and lactation. *Nutrition*.20:235–240.
- [29]. Parmar, M.S. (2016). Acute glomerulonephritis. *Medscape*. Update August 4 2016.
- [30]. Ramaiah, S., Rivera, C., and Arteel, G. (2004).Early-phase alcoholic liver disease: an update on animal models, pathology, and pathogenesis. *International Journal of Toxicology*.23:217–231.
- [31]. Rode, A., Furlanos, S., and Nicoll, A. (2010). Oral vitamin D replacement is effective in chronic liver disease. *Gastroenterology Clinical Biology* 34:618-620.
- [32]. Rogers J.M and Kavlock R.J. (2001).Developmental toxicology. In Casarett and Doull's toxicology: The basic science of poisons, ed. Klaassen CD. pp: 351–86, 6th ed. New York: Mc Graw-Hill.
- [33]. Saad B., Hassan A., Ghassan A.H. and Omar S. (2006) Review: Safety of Traditional Arab Herbal Medicine. *Evidence-Based Complementary and Alternative Medicine* 3(4): 433–439
- [34]. Singh, G.D., Ganjoo, M., Youssouf, M.S.,Koul, A., Sharma, R., Singh, S., Sangwan, P.L., Koul, S., Ahamad, D.B. and Johri, R.K. (2009). Sub –acute toxicity evaluation of an aqueous extract of Labisiapumila, a Malaysian herb. *Food and Chemical Toxicology*, 47:2661-2665.
- [35]. Solecki, R., Rauch, M., Gall, A., Buschmann, J., Clark, R., Fuchs, A., Kan, H., Heinrich, V., Kellner, R., Knudsen, T.B., Li, W., Makris, S.L., Ooshima, Y., Paumgarten, F., Piersma, A.D., Schonfelder, G., Oelgeschlager,M., Schaefer, C., Shiota, K., Ulbrich, B., Ding, X., and Chahoud, I. (2015). Continuing harmonization of terminology and innovations for methodologies in developmental toxicology: Report of the 8th Berlin Workshop on Developmental Toxicity, 14–16 May 2014. *Reproductive Toxicology*. 57:140-146.
- [36]. Sommer, A.(2008). Vitamin A Deficiency and Clinical Disease: An Historical Overview. *Journal of Nutrition*.138 (10): 1835-1839
- [37]. Sulaiman M.R., Hussain M.K., Zakaria Z.A., Somchit M.N., Moin S., Mohamad A.S., Israf D.A. (2008). Evaluation of the antinociceptive activity of *Ficusdeltoidea*aqueous extract.*Fitoterapia*, 79 (7-8): 557-561
- [38]. Tyl, R.W., Chernoff, N., and Rogers, J.M.(2007).Altered Axial Skeletal Development.*Birth Defects Research*. Part B. 80: 451-472