

## Histologic Effect of Garlic Extract on the Spleen of Adult Wistar Rat

\*Udi Onoriode Andrew<sup>1</sup>, Lilian Ebele Chris Ozoko<sup>2</sup>, Itaire Afoke Kingsley<sup>3</sup>,  
Enaohwo T. Mamerhi<sup>2</sup>, Ewere Beauty<sup>2</sup>

<sup>1</sup>Department of Public Health, Faculty of Health Sciences, Novena University, Ogume.

<sup>2</sup>Department of Human Anatomy, Faculty of Basic Medical Sciences, Delta State University, Abraka.

<sup>3</sup>Department of Human Anatomy, University of Medical Sciences Ondo City, Ondo State,

Corresponding Author: Udi Onoriode Andrew

---

**Abstract:** One of the plant commonly consumed in Nigeria for dietary and therapeutic purpose is Garlic (*Allium sativum*). Often time, the effect of the plant on the spleen is not considered by users. This present study is to investigate the histologic effect of garlic extract on the spleen of adult Wistar rats. This was a descriptive experimental study involving twenty-four (24) adult wistar rats as experimental animals. Twenty-four (24) adult Wistar rats weighing between 150-250 g were used for this research. The experimental animals were obtained from the Animal House of the faculty of Basic Medical Sciences, Delta State University, Abraka. The animals were randomly assigned into four (4) groups. The control group were given distilled water and rat chow. The treatment group (Group 2, 3, 4) received 100mg/kg, 200mg/kg and 300mg/kg respectively of body weight of aqueous garlic extract, rat chow and water. Histological results from this study indicate that higher doses of garlic extract has effect on the cells of the spleen (white pulp, red pulp, lymphoid tissue, trabeculae) and even the outer capsule of the wistar rats.

**Keywords:** Garlic, Wistar rats, Dietary and lymphoid tissue

---

Date of Submission: 30-05-2017

Date of acceptance: 28-07-2017

---

### I. Introduction

One of the plants commonly consumed in Nigeria for dietary and therapeutic purpose is Garlic (*Allium sativum*)<sup>1</sup>. Padilla-Camberos *et al.* reported the use of garlic as an antibacterial and anticancer agent by inducing apoptosis in a caspase-3-dependent way<sup>2</sup>. Other reports shows the pharmacological effects of *Allium sativum* on the immune system. This include suppression of inflammatory cytokines production, immunomodulatory and proliferation of human lymphocytes<sup>3,4,5,6</sup>. In a different study conducted by Hammamiet *al.*, Assayed *et al.* and Joseph *et al.* of effect of garlic on human system, opined that garlic possessed toxic substances<sup>7,8,9</sup>. Banerjee *et al.* described the doses of garlic as a key role in determining its effect on both morphology and biochemistry of tissues<sup>10</sup>. Eluwaet *al.* Conducted a study on the effect of a mixed diet of Garlic, Garden Egg and Groundnut on the cytoarchitecture of the spleen of anaemic Wistar rats. They used twenty five induced anaemic wistar rats of both sexes weighing 160-200g. The study showed slight effect on the spleen. They concluded that the mixed diet of garlic, garden egg and groundnut had a protective effect on the cytoarchitecture of the spleen of induced anaemic wistar rats<sup>1</sup>.

Alirezaet *al.* examined the effect of Garlic consumption on Th1/Th2 Cytokines in Phytohemagglutinin (PHA) activated rat spleen lymphocytes. They divided thirty male rats equally into two groups. The treatment group received garlic solution in water (600 mg/kg/4 mL) while control groups received distilled water by gavage. After 1 month, they analysed the serum and supernatant of PHA activated spleen lymphocytes for IFN- $\gamma$  and IL-4 by the enzyme-linked immunosorbent assay test and also weighed the spleen. The result revealed no significant differences between the spleen weights in the two groups. They concluded that oral garlic treatment may favor a Th2 or humoral immune response<sup>8</sup>.

Nusaibahet *al.* investigated the histological effects of excessive consumption of Zingiber officinale on liver and spleen of mice. The result shown that the spleen section of mice treated with (50 mg/kg) of extract displayed hyperplasia of red pulp with proliferation with mononuclear cell around sinusoid form cord like structure, while, the sectional spleen treated with (75 mg/kg) of extract showed moderate hyperplasia of white pulp. They thereafter recommended low intake of garlic food supplement. This present study is to investigate the histologic effect of garlic extract on the spleen of adult Wistar rats<sup>11</sup>.

## II. Materials And Methods

### Study Design:

This is a descriptive experimental study involving twenty-four (24) adult wistar rats as experimental animals.

### Collections and Preparation of Aqueous Garlic Extract

Fresh garlic bulbs were purchased from Abraka central market, Abraka, Delta State and taken to Botany Department of Delta State University, Abraka for identification and authentication of the plant. The identified garlic was taken to the Department of Pharmaceutical Chemistry Laboratory of the faculty of Pharmacy, Delta State University, Abraka for extraction. Cold maceration (soaking) method was used to prepare the extract. The garlic was peeled off, washed and weighed using a digital weighing balance. The weighed garlic was pounded in a clean mortar with pestle into a paste. The pounded garlic was soaked in distilled water for 48 hours (steering at intervals for proper mixing). After 48 hours, it was sieved into a conical flask using a clean sieve and a filter paper. The filtrate was taken to the rotary evaporator to remove excess amount of water, at a temperature of 60-80°C leaving behind the crude active in the flask. The crude active was further concentrated using the oven at a temperature of 30-40°C. A stock solution of 100, 200, 300mg/kg was prepared from the concentrated paste-like garlic extract. The stock solution was kept in the refrigerator at a temperature of 4°C till use.<sup>12</sup>

### Extract Administration

The extract was administered orally using an orogastric cannula. The extract was administered once daily between the hours of 10:00 am and 12:00 pm for a period of 21 days

### Experimental Animals

Twenty-four (24) adult albino wistar rats weighing between 150-250g were used for this research. The animals were obtained from the Animal House of the College of Basic Medical Sciences, Delta State University, Abraka. The animals were randomly assigned into four (4) groups. The control group were given distilled water and rat chow. The treatment group (Groups 2,3,4) received 100mg/kg, 200mg/kg and 300mg/kg respectively of body weight of aqueous garlic extract, rat chow and water.

### Animal Sacrifices

Twenty-four (24) hours after the last day of administration, the animals were sacrificed by cervical dislocation. The spleen tissues were harvested and fixed in a 10% formal saline for histological analysis, this was adopted by Carlton<sup>13</sup>.

### Procedure for Tissue Processing

The tissue was processed and stained with standard histologic techniques.

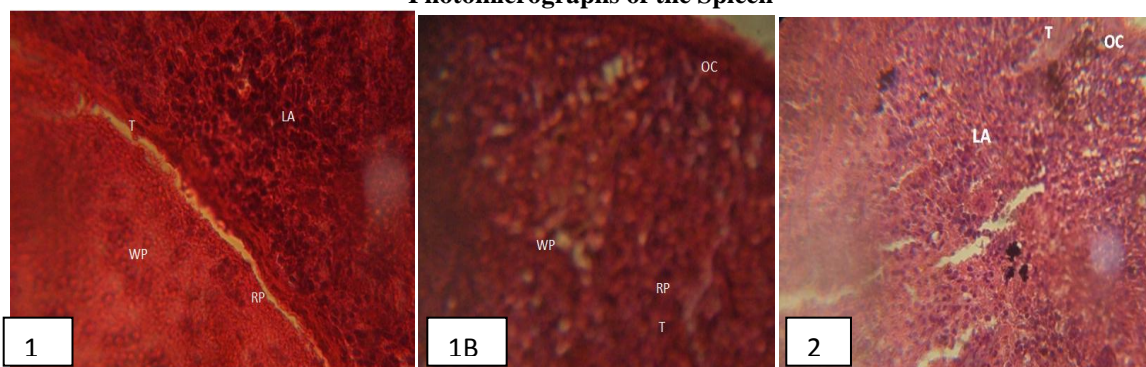
### Result analysis and interpretation

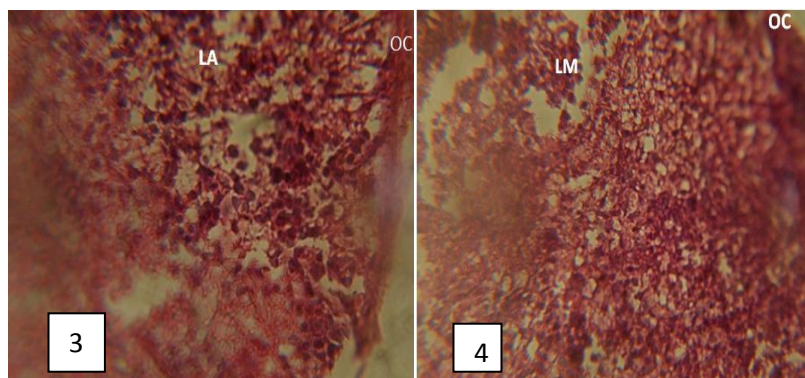
The stained tissue images were captured using digital microscopic eyepiece, 'SCOPETEK DCM 500, 8.0 MEGA PIXELS' connected to the USB port of a computer and the results were presented in a well labeled histologic slides.

## III. Results

Histological results of this study indicate that the higher doses of garlic extract affect the cells of the spleen (white pulp, red pulp, lymphoid tissue, trabeculae) and even the outer capsule. They also show that the higher doses of garlic extract have a dehydrating effect on these cells. The damage to the cells of the spleen observed in this study shown damaging effect of the high dose of garlic. Damage to the white pulp by high doses of garlic extract as recorded in the study may lead to anemic conditions in the experimental animals, limited oxygen supply and invariably slow growth. This can thus be said to be one reason why the animals which received 300 mg/ml of the extract (group 4) showed reduced growth.

### Photomicrographs of the Spleen





**Fig 1:** Normal rat spleen consisting of the Red pulp (RP), the white pulp (WP), the trabecula (T) and the Lymphoid aggregations (LA). (H &E X400). **Fig 2:** Normal rat spleen consisting of the Red pulp (RP), the white pulp (WP), the trabecula (T) and the Lymphoid aggregations (LA). (H &E X100). **Fig 3:** Normal spleen consist of slightly rough outer capsule (OC) (H&E X400). **Fig 4:** Micrograph shows absence of the Red pulp and white pulp. The capsule is discontinuous at some points, and the lymphoid aggregation is absent with presence of scanty meshwork or reticular fibres. (H&E X400).

#### IV. Discussion

Garlic have been reported to cause gastrointestinal tract injury in healthy subjects after intragastric infusion of a single dose of raw garlic of over 0.75 g<sup>14</sup>. Koderá, also reported a similar study that involved injecting 0.5 ml of raw garlic juice into the ligated duodenum of rats<sup>15</sup>. The result revealed injury in the duodenal mucosal lining after 2 hours of exposure. The damage includes ulcers and bleeding after 24 hours. This were similar to the present study as there was evident of effect on the cells of the spleen (white pulp, red pulp, lymphoid tissue, trabeculae). The damage to the cells of the spleen observed in this present study may be due to the damaging effect of the high dose of garlic.

Banerjee *et al.*, described the spleen as the largest secondary immune organ in the body which is responsible for initiating immune reactions to blood-borne antigens and for filtering the damaged red blood cells<sup>10</sup>. Koderá *et al.* further stated that these functions are carried out by the two main compartments of the spleen, the white pulp (including the marginal zone) and the red pulp<sup>15</sup>. Damage to these cells as induced by high dose of garlic extract in this present study, may result in the inability of the spleen to play its normal role. This may cause the body to be unable to filter foreign materials and destroy damaged red blood cells.

Other study described the red pulp of the spleen as a storage site for iron, erythrocytes, and platelets and site of hematopoiesis, particularly in fetal and neonatal animals<sup>14, 15</sup>. Damage to the white pulp by high doses of garlic extract as recorded in this present study may lead to anemic conditions in the experimental animals, limited oxygen supply and invariably slow growth. This could thus be said to be one reason why the animals which received 300mg/ml of the extract (group 4) showed reduced growth.

In conclusion, the result of this present study showed a significant alteration to the cells of the spleen (white pulp, red pulp, lymphoid tissue, trabeculae) and even the outer capsule. The higher doses of garlic extract also had a dehydrating effect on these cells. Compromise in the normal structure and function of the spleen induced by the higher doses of garlic extract could lead to many adverse effects in the animals. It is therefore necessary to establish a standard dosage that will be safe for any therapeutic or prophylactic measure, while taking into consideration other factors.

#### References

- [1] Eluwa, M. A., Isamoh, T. E., Asuquo, O. R., Akpantah, A. O. and Ekanem, T. B. (2013) Evaluation of Consumption of Mixed Diet of Garlic, Garden Egg and Groundnut on the Cytoarchitecture of the Spleen of Anaemic Wistar Rats. *International Journal of Science and Research* 2(10) 2319-7064
- [2] Omotoso, G. O., Saibu, S. A., Akinlolu, A. and Kadir, E. (2011) Effects of Aqueous Extract of Garlic and Vitamin C on the Kidney of Albino Rats. *Asian J. Exp. Biol. Sci.* 2(3) 2011: 455-461
- [3] Hodge G, Hodge S, Han P. 2002. *Allium sativum* (garlic) suppresses leukocyte inflammatory cytokine production in vitro: potential therapeutic use in the treatment of inflammatory bowel disease. *Cytometry*. 48: 209–215.
- [4] Kyo, E., Uda, N., Kasuga, S. and Itakura, Y. (2001). Immunomodulatory effects of aged garlic extract. supplement of conference: recent advances on the nutritional effects associated with the use of garlic. *J. Nutr* 131: 1075–1079.
- [5] Lau BHS, Yamasaki T, Gridley DS. 1991. Garlic compounds modulate macrophage and T-lymphocyte functions. *Mol Biother* 3: 103–107.
- [6] Morioka, N, Sze LL, Moron D. L. and Irie R. F. (1993). A protein fraction from aged garlic extract enhances cytotoxicity and proliferation of human lymphocytes mediated by IL-2 and concanavalin A. *Cancer Immunol Immunother* 37: 316–322.
- [7] Hammami, I., Amara, S., Benahmed, M., El May, M.V and Mauduit, C (2009). Chronic crude garlic-feeding modified adult male rat testicular markers: mechanisms of action. *Reprod Biol Endocrinol* 7:65-68

- [8] Assayed, M.E., Salem, H.A. and Khalaf, A.A. (2008). Protective effects of garlic extract and vitamin C against cypermethrin reproductive toxicity in male rats. *Res. J.Vet. Sci* **1**: 1-15.
- [9] Alireza, Z., Aliasghar, V. and Masoud, S. G. (2009) The Effect of Garlic Consumption on Th1/Th2 Cytokines in Phytohemagglutinin (PHA) Activated Rat Spleen Lymphocytes *Phytother. Res.* **23**, 579–581
- [10] Banerjee, S.K., Maulik, M., Manchanda, S.C., Dinda, A.K., Das, T.K and Maulik, S.K (2001). Garlic-induced alteration in rat liver and kidney morphology and associated changes in endogenous antioxidant status. *Food and Chemical Toxicology* **39(8)**:793-797.
- [11] Nusaibah, A., Marwa, H., Khuder, S., Yacoub, A. and Noor, N. (2013). Histological Effects of Excessive Consumption of Zingiberofficinaleon Liver and Spleen of the Mice. *Journal of Al-Nahrain University* **16 (2)**151-156.
- [12] Uvieghara K.E. (2014). Procedures of Extraction of Garlic Extract. Faculty of Pharmacy, Department of Pharmaceutical Chemistry laboratory. Delta State University, Abraka.
- [13] Carlton (1967). Carlton's histological techniques. Oxford university press, newyork. 4:144 – 149.
- [14] Desai, H. G., Kalro, R. H. and Choksi, A. P. (1990) Effect of ginger and garlic on DNA content of gastric aspirate. *Indian J Med Res***92**: 139-141.
- [15] Kodera, Y., Suzuki A, Imada O, Kasuga S, Sumioka I and Kanezawa A, (2002). Physical, chemical, and biological properties of s-allylcysteine, an amino acid derived from garlic. *J Agric Food Chem*; **50**:622e32.

Udi Onoriode Andrew. "Histologic Effect of Garlic Extract on the Spleen of Adult Wistar Rat."  
IOSR Journal of Pharmacy and Biological Sciences (IOSR-JPBS) 12.4 (2017): 01-04.